



PATIENT

Mouse Coppola

PRESENTING CLINICAL SIGNS

Patient presents for weight loss, diarrhea, and possible abdominal mass. No current meds, or bloods.

SPECIES

Feline

ULTRASONOGRAPHIC EXAMINATION OF THE ABDOMEN

Urinary System

Urinary bladder is adequately distended. It has a normal uniform wall thickness. Contents include primarily anechoic fluid with occasional echogenic non-shadowing debris, most consistent with incidental suspended lipid in a cat, possibly combined with exfoliated cells, mucous and/or small blood clots. Both sterile inflammation as well as urinary tract infection can also present with echogenic debris. No masses or cystoliths are observed. The trigone and visible pelvic urethra are normal in thickness with a smooth mucosal surface.

BREED

DSH

SEX

Neutered Male

The right kidney is normal in size (4.02 cm), shape and echogenicity. It has smooth peripheral margination. There is a normal 1:3 cortex to medulla ratio with appropriate corticomedullary distinction. There is no evidence of pyelectasia, mineral or infarcts observed.

AGE

11 Years

The left kidney is normal in size (3.5 cm), shape and echogenicity. It has smooth peripheral margination. There is a normal 1:3 cortex to medulla ratio with appropriate corticomedullary distinction. There is no evidence of pyelectasia, mineral or infarcts observed.

WEIGHT

6.6 Pounds

Adrenal Glands

The right adrenal gland is normal in size (0.64 cm), shape and contour. Corticomedullary structure is unremarkable. Visible surrounding vasculature appears normal.

The area of the left adrenal gland was examined without evident pathology.

INTERPRETED BY

Beth Johnson, DVM
DACVIM

Spleen

The spleen is subjectively normal in size with a normal smooth capsular contour. Parenchyma is appropriately finely textured and homogenous with normal echogenicity relative to surrounding tissue (hyperechoic to liver). No focal nodules or masses are observed. Splenic vasculature appears normal.

IMAGING PERFORMED BY

Kelly Vazquez

Liver

The liver is subjectively normal in size with normal smooth curvilinear peripheral contour. Parenchyma is appropriately hypoechoic to the spleen in echogenicity and appropriately mildly coarse and homogenous in echotexture. Caudal to the gallbladder, there is a focal hepatic nodule/mass, primarily hyperechoic in echogenicity, but containing multiple cysts of varying size. The nodule/mass measures 1.6 cm x 1.9 cm. Several other primarily hyperechoic cystic nodules/masses noted. Visible vasculature and biliary tree appear normal without distension or congestion.

HOSPITAL NAME

Animal General
on the Hudson

The gallbladder is non-distended in size. The wall is smooth without visible thickening. Luminal contents are primarily anechoic. There is no evidence of cystic or common bile duct dilation.

REFERRING VET

Dr. William Freedman

Gastrointestinal

INVOICE

42369

The stomach wall is normal in thickness (canine < 0.5 cm and feline < 0.4 cm) and layering. The lumen of the stomach is empty with no evidence of obstruction, foreign material or infiltrative disease. Pyloric outflow tract appears patent.

DATE

10/26/22

The visible small intestine demonstrates areas of thick muscularis layer relative to mucosa (disruption of the normal 1:3 muscularis:mucosa ratio). Small intestinal submucosa is slightly irregular, thick and



PATIENT

Mouse Coppola

hyperechoic, without evident loss of layering appreciated. The lumen is empty with no evidence of obstruction or foreign material.

SPECIES

Feline

In the mid right abdomen, adjacent to the ileocecolic junction, but not definitively involving it (that can be seen, there is an approximately 5.0 cm long bowel mass characterized by complete loss of layering and a 1-2 cm thick, hypoechoic wall.

The visible colon is normal in wall thickness (< 0.2 cm) and layering. Contents are consistent with normal formed feces and gas.

BREED

DSH

Pancreas

Pancreas is prominent (enlarged) in size, hypoechoic to surrounding tissue and has a mildly irregular undulating contour. Parenchyma is coarse with mixed echogenic remodeling noted. Pancreatic duct dilation is noted.

SEX

Neutered Male

Free Abdomen

There is no evidence of free peritoneal effusion noted in these images.

AGE

11 Years

There is no apparent lymphadenopathy noted in these images.

PRIMARY FINDINGS

- **Bowel mass believed to be small bowel** - Ileocecal junction area cannot be definitively ruled out but appears less likely. Top differential includes infiltrative neoplasia such as lymphoma, especially given the diffusely thick muscularis throughout the remainder of the bowel versus possibly adenocarcinoma versus other. Benign disease is possible but considered much less likely.
- **Feline biliary cystadenomas** - In a senior cat, this liver lesion is most consistent with a/multiple benign biliary cystadenoma(s). Malignancy cannot be ruled out but is considered less likely given lack of clinical signs and/or laboratory changes.

INTERPRETED BY

Beth Johnson, DVM
DACVIM

ULTRASONOGRAPHIC FINDINGS

- Chronic active pancreatitis
- Urinary bladder debris

IMAGING PERFORMED BY

Kelly Vazquez

HOSPITAL NAME

Animal General
on the Hudson

INTERPRETATION OF THE FINDINGS & FURTHER RECOMMENDATIONS

Three view thoracic radiographs are recommended for further assessment of cardio-pulmonary status as well as to further evaluate for any evidence of metastatic disease, if not recently evaluated.

A fine needle aspirate of the bowel mass is recommended if patient's coagulation status is appropriate.

A gastrointestinal malabsorption panel (including cobalamin, folate, TLI and PLI) to Texas A&M GI Laboratory is recommended for further evaluation of GI and pancreatic function.

If a diagnosis cannot be obtained cytologically, and/or the diagnosis is not round cell, such as neoplasia, ultimately an exploratory laparotomy with planned mass removal, resection, and anastomosis may be warranted, at which time biopsies of the diffuse bowel changes would be recommended as well.

REFERRING VET

Dr. William Freedman

INVOICE

42369

DATE

10/26/22



PATIENT

Mouse Coppola

SPECIES

Feline

BREED

DSH

SEX

Neutered Male

AGE

11 Years

WEIGHT

6.6 Pounds

INTERPRETED BY

Beth Johnson, DVM
DACVIM

IMAGING PERFORMED BY

Kelly Vazquez

HOSPITAL NAME

Animal General
on the Hudson

REFERRING VET

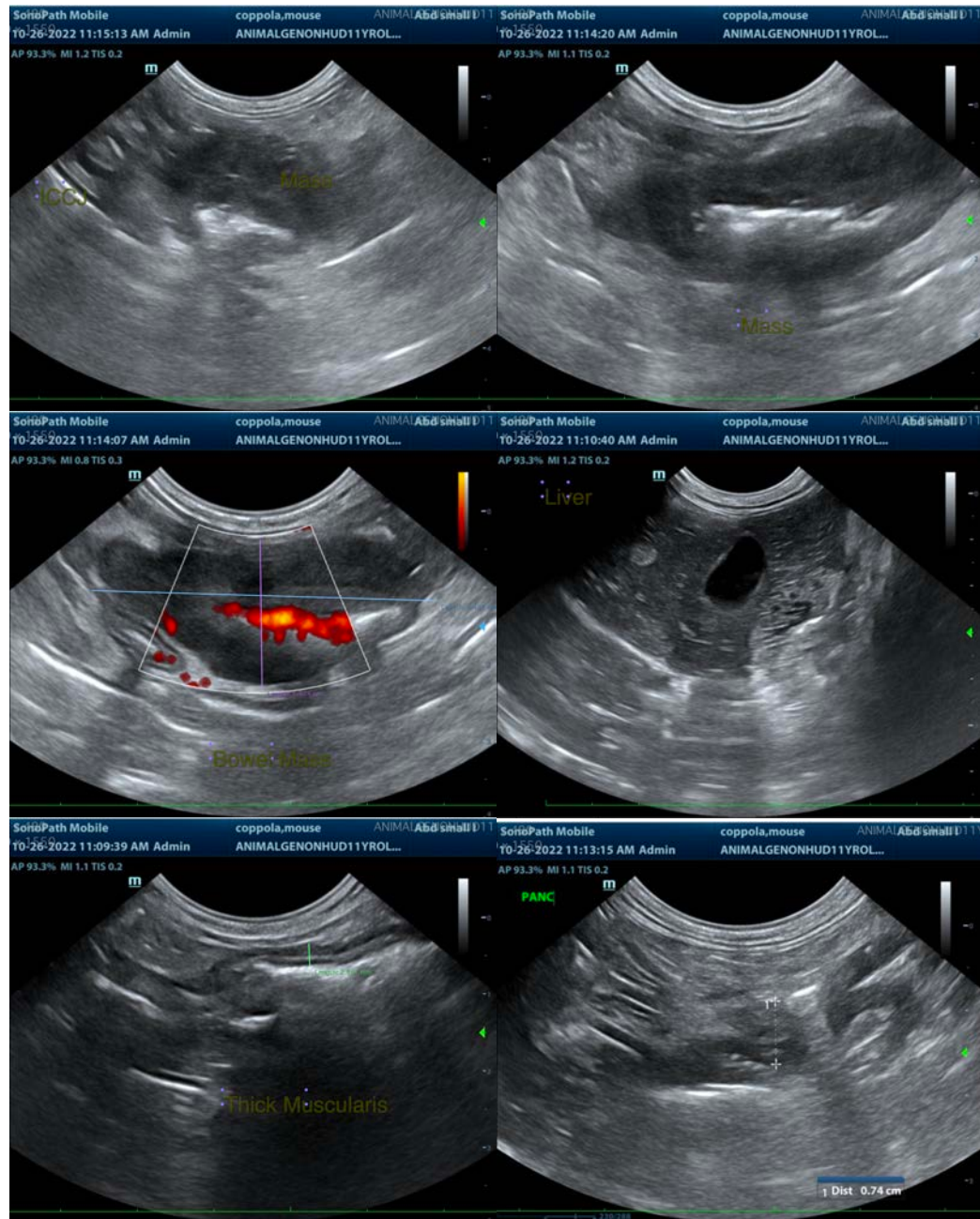
Dr. William Freedman

INVOICE

42369

DATE

10/26/22





PATIENT

Mouse Coppola

SPECIES

Feline

BREED

DSH

SEX

Neutered Male

AGE

11 Years

WEIGHT

6.6 Pounds

INTERPRETED BY

Beth Johnson, DVM
DACVIM

IMAGING PERFORMED BY

Kelly Vazquez

HOSPITAL NAME

Animal General
on the Hudson

REFERRING VET

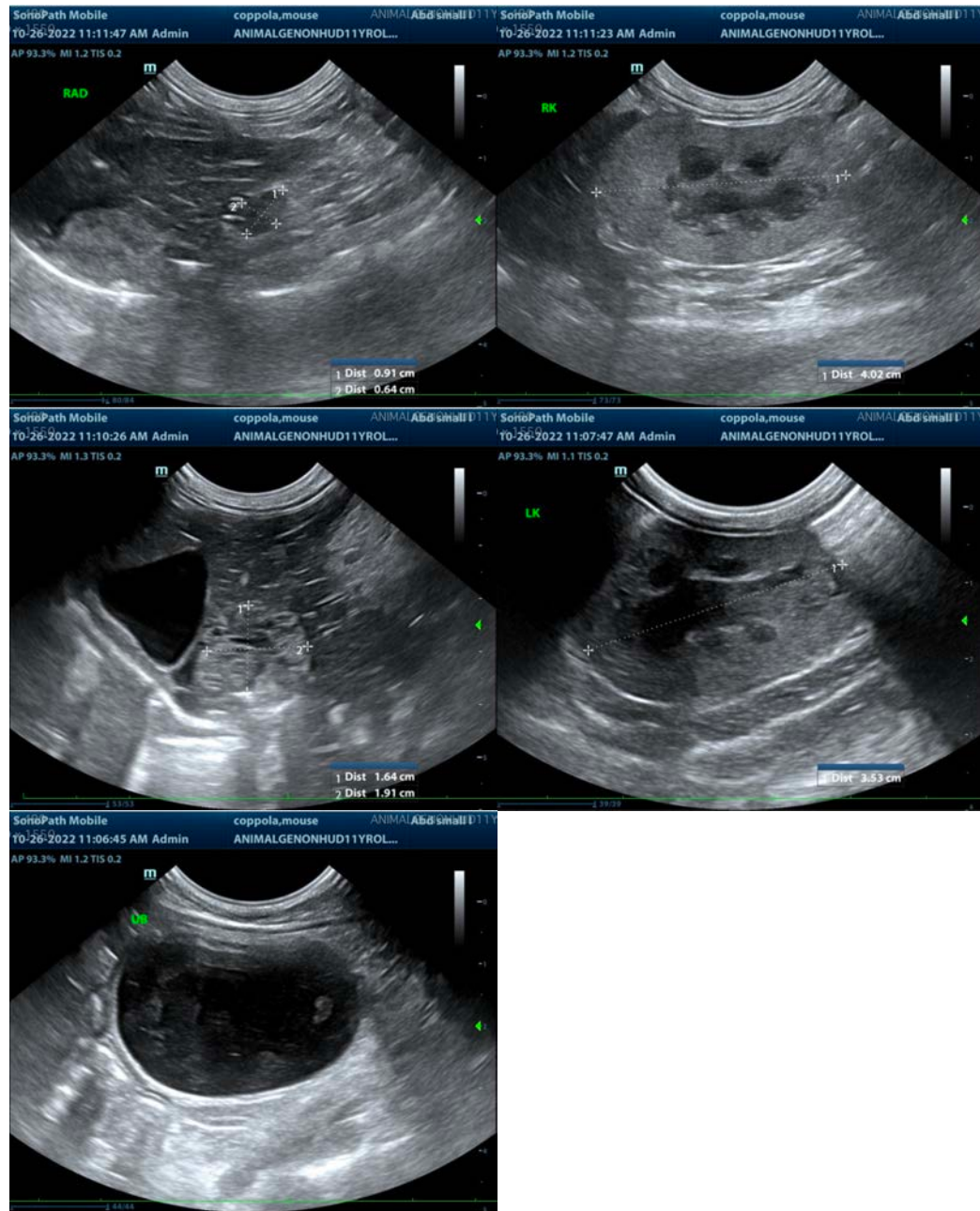
Dr. William Freedman

INVOICE

42369

DATE

10/26/22



The information and recommendations provided are based on the images presented by the referring veterinarian/sonographer. No evaluation can be communicated regarding pathology that was not visible in the image/video clips provided.

Thank you for this referral. If the clinical or image interpretation does not parallel your findings or if I can be of any further assistance please contact me.

Beth Johnson, DVM, DACVIM
Beth.Johnson@sonopath.com