

**DATE PRESENTING CLINICAL SIGNS**

10/26/22

Grade 2/6 murmur right sided, no arrhythmia noted, lungs clear bilaterally. Hx of kidney issues dx'd at Advanced Veterinary Complex. Pt has not been eating since yesterday; pt is historically a picky eater, but usually will not avoid food completely.

**PATIENT**

Ellie Markus

Current Medications: None listed.

Lab Results: See attached.

Date of Previous IntraPet Ultrasound: No previous.

**SPECIES**

Sedation: Not required to complete full diagnostic ultrasound.

Canine

Stat Report: Not requested.

**BREED**

Boxer

**ULTRASONOGRAPHIC EXAMINATION OF THE ABDOMEN****Urinary System**

The urinary bladder is moderately distended with anechoic contents. No masses, inflammatory changes, echogenic sediment or cystoliths are observed. The urinary bladder, trigone and visible pelvic urethra are normal in thickness with a smooth mucosal surface.

**SEX**

Spayed Female

The right kidney is small, measuring 3.96 cm. The left kidney is large (compensatory), measuring 6.37 cm. Both kidneys are irregular and diffusely echogenic with decreased corticomedullary distinction and poor visualization of internal architecture. No overt neoplasia or mineral is observed. Chronic infarcts are noted in the right kidney. Pyelectasia is noted bilaterally, measuring 0.95 cm in the sagittal view of the left kidney and 0.39 cm in the sagittal view of the right kidney.

**AGE**

5/27/21

**WEIGHT**

54.7 Pounds

**Adrenal Glands**

The right adrenal gland is normal in size (2.88 cm long x 0.64 cm at the cranial pole and 0.65 cm at the caudal pole), shape and contour. Corticomedullary structure is unremarkable. Visible surrounding vasculature appears normal.

**INTERPRETED BY**Beth Johnson, DVM  
DACVIM

The left adrenal gland is normal in size (2.6 cm long x 0.75 cm at the cranial pole and 0.77 cm at the caudal pole), shape and contour. Corticomedullary structure is unremarkable. Visible surrounding vasculature appears normal.

**IMAGING PERFORMED BY**

Rachel Brilhart RDMS

**Spleen**

The spleen is subjectively normal in size with a normal smooth capsular contour. Parenchyma is appropriately finely textured and homogenous with normal echogenicity relative to surrounding tissue (hyperechoic to liver). No focal nodules or masses are observed. Splenic vasculature appears normal.

**HOSPITAL NAME**

Eldersburg VH

**Liver**

The liver is subjectively normal in size with normal smooth curvilinear peripheral contour. Parenchyma is appropriately hypoechoic to the spleen in echogenicity and appropriately mildly coarse and homogenous in echotexture. No focal lesions are observed. Visible vasculature and biliary tree appear normal without distension or congestion.

**REFERRING VET**

Dr. James

**INVOICE**

42376

The gallbladder is non-distended in size. The wall is smooth without visible thickening. Luminal contents are primarily anechoic. There is no evidence of cystic or common bile duct dilation.

**Gastrointestinal**

The visible stomach wall is normal in thickness and layering. The lumen of the stomach is mildly distended with very echogenic reverberation artifact from intraluminal gas. There is no evidence of obstruction, foreign material or infiltrative disease; however, complete visualization of far wall is partially inhibited by gas. Pyloric outflow tract appears patent.

The visible small intestines are normal in wall thickness and layering (canine duodenum < 0.5 cm and feline duodenum < 0.4 cm; other < 0.3 cm). Small intestinal motility appears adequate (1-3 contractions per min). The lumen of the small intestine is empty with no evidence of obstruction, foreign material or infiltrative disease.

The visible colon is normal in wall thickness (< 0.2 cm) and layering. Contents are consistent with normal formed feces and gas.

### ***Pancreas***

The pancreatic parenchyma is appropriately isoechoic to surrounding tissue. Visible capsule is smooth and normal in contour. There is no visible pancreatic duct dilation. There is no evidence of active peripancreatic inflammation.

### ***Free Abdomen***

There is no evidence of free peritoneal effusion noted in these images.

The mesenteric lymph nodes are prominent in size with swollen capsular contour. Normal elongated shape (length to width ratio) is maintained. There is no loss of parenchymal detail.

## **PRIMARY FINDINGS**

- **Renal dysplasia** – This appearance of the kidneys in a young dog is most concerning for congenital renal dysplasia or juvenile nephropathy. Other differentials include glomerular or interstitial nephritis, leptospirosis, chronic pyelonephritis, ethylene glycol toxicosis, etc.
- **Bilateral pyelectasia** – Differentials for pyelectasia include pyelonephritis, diuresis, congenital malformation or ureteral or lower urinary tract obstruction.

## **SECONDARY FINDINGS**

- **Reactive mesenteric lymph nodes** – This is likely normal for a young dog.

## **INTERPRETATION OF THE FINDINGS & FURTHER RECOMMENDATIONS**

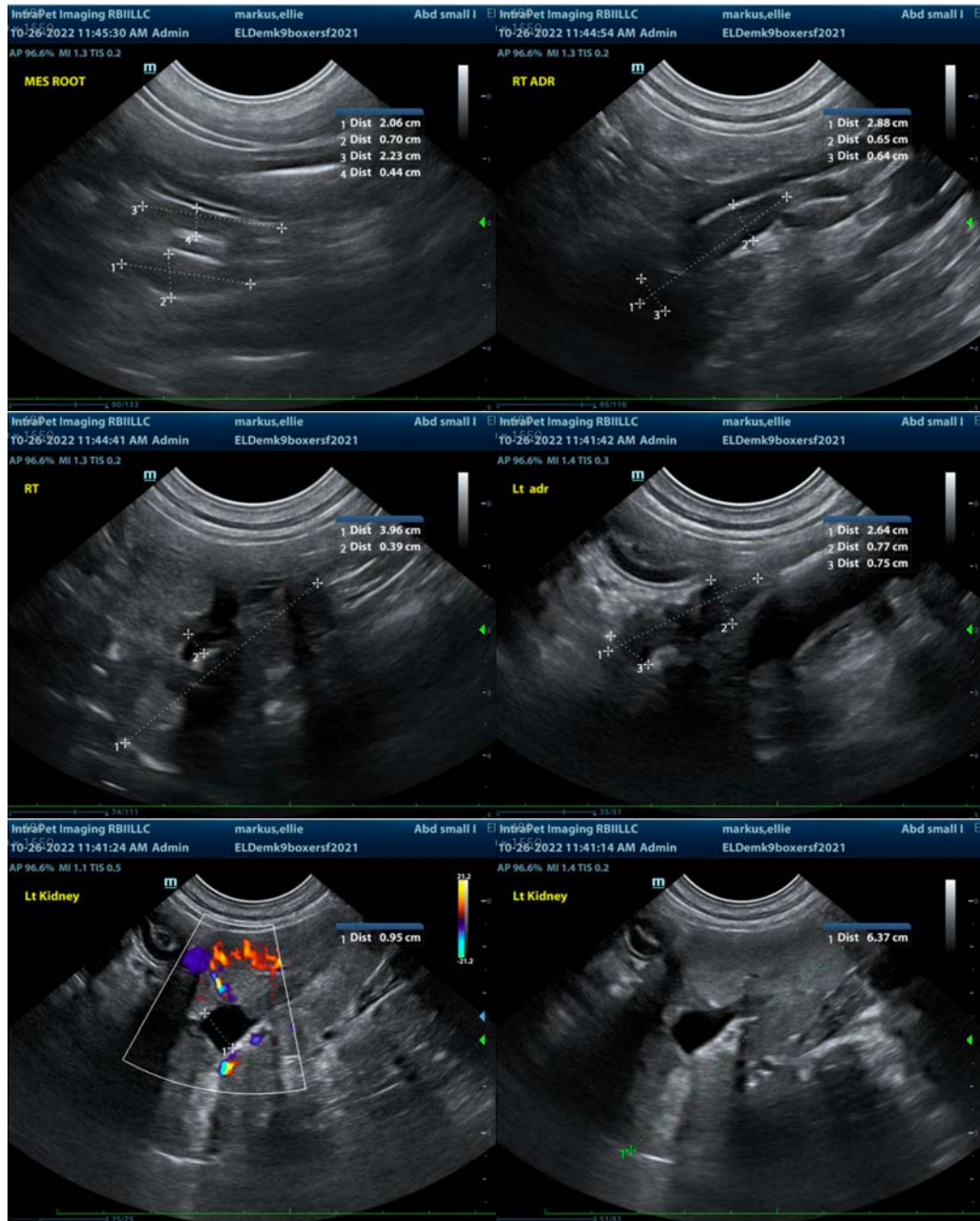
A urine culture is recommended if not recently evaluated, and given the pyelectasia (primarily in the left kidney), if a positive culture cannot be obtained from the urinary bladder, direct sampling of the renal pelvis with ultrasound guided pyelocentesis for culture and sensitivity could be considered, if safe to do so in this patient.

The appearance of the kidneys is consistent with chronic disease. However, testing for Leptospirosis is warranted if Lepto status has not been evaluated.

Given the reported proteinuria, urine protein to creatinine ratio is recommended to help guide treatment. Blood pressure is also recommended if not recently evaluated.

In the meantime, medical management for chronic kidney disease in the form of a kidney friendly diet, fluid therapy (either in-hospital or at-home subcutaneously) could be considered if clinically indicated. Management of the gastrointestinal signs with antiemetics and gastroprotectants is recommended to help aid appetite in addition to appetite stimulants, in addition to any indicated management of hypertension and/or proteinuria based on results.

If pyelocentesis cannot be obtained and urine culture is negative, empirical antibiotics could still be considered as well.



**The information and recommendations provided are based on the images presented by the referring veterinarian/sonographer. No evaluation can be communicated regarding pathology that was not visible in the image/video clips provided.**

Thank you for this referral. If the clinical or image interpretation does not parallel your findings or if I can be of any further assistance please contact me.

**Beth Johnson, DVM, DACVIM**  
Beth.Johnson@sonopath.com