

**DATE PRESENTING CLINICAL SIGNS**

10/25/22 Urinary incontinence since 8 weeks of age.

PATIENT Current Medications: Simplicef 200mg x 1 week.
 Date of Previous IntraPet Ultrasound: No previous.
 Sedation: Torbugesic/Midazolam IV.
 Stat Report: Not requested.

Koda Hulbert

SPECIES ULTRASONOGRAPHIC EXAMINATION OF THE ABDOMEN

Canine

Urinary System**BREED**

Urinary bladder is only mildly distended (empty). Visible contents are anechoic. Urinary bladder wall is unable to be fully assessed for pathology without further distension. No visible masses or cystoliths are observed. The trigone and visible pelvic urethra are normal thickness with a smooth mucosal surface. If there are urinary signs and/or concern for urinary bladder pathology, reassessment after complete filling is recommended.

Newfoundland

SEX

Spayed Female

Due to the bladder being empty, ureteral papillae/jets are difficult to observe. However, there is an anechoic tubular structure dorsal to the urinary bladder that runs along and passed the trigone and into the area of the proximal urethra. Termination of the structure cannot be determined.

AGE

8/19/20

The right kidney is normal in size (7.15 cm), shape and echogenicity. It has smooth peripheral margination. There is a normal 1:3 cortex to medulla ratio with appropriate corticomedullary distinction. There is no evidence of pyelectasia, mineral or infarcts observed.

WEIGHT

78 Pounds

The left kidney is normal in size (6.6 cm), shape and echogenicity. It has smooth peripheral margination. There is a normal 1:3 cortex to medulla ratio with appropriate corticomedullary distinction. There is no evidence of pyelectasia, mineral or infarcts observed.

INTERPRETED BYBeth Johnson, DVM
DACVIM**Adrenal Glands**

The right adrenal gland is normal in size (2.9 cm long x 0.61 cm at the cranial pole and 0.67 cm at the caudal pole), shape and contour. Corticomedullary structure is unremarkable. Visible surrounding vasculature appears normal.

IMAGING PERFORMED BYStephanie Warga
RDCS, RVT

The left adrenal gland is normal in size (2.59 cm long x 0.55 cm at the cranial pole and 0.65 cm at the caudal pole), shape and contour. Corticomedullary structure is unremarkable. Visible surrounding vasculature appears normal.

HOSPITAL NAME

Banfield Abingdon

Spleen

The spleen is subjectively normal in size with a normal smooth capsular contour. Parenchyma is appropriately finely textured and homogenous with normal echogenicity relative to surrounding tissue (hyperechoic to liver). No focal nodules or masses are observed. Splenic vasculature appears normal.

REFERRING VET

Dr. Simpson

Liver

The liver is subjectively normal in size with normal smooth curvilinear peripheral contour. Parenchyma is appropriately hypoechoic to the spleen in echogenicity and appropriately mildly coarse and homogenous in echotexture. No focal lesions are observed. Visible vasculature and biliary tree appear normal without distension or congestion.

INVOICE

42331

Gallbladder is moderately distended with anechoic bile as well as suspended and gravity dependent echogenic debris. The wall is smooth without visible thickening. There is no evidence of cystic or CBD dilation. There is no evidence of effusion or inflammation.

Gastrointestinal

The stomach wall is normal in thickness (canine < 0.5 cm and feline < 0.4 cm) and layering. The lumen of the stomach is empty with no evidence of obstruction, foreign material or infiltrative disease. Pyloric outflow tract appears patent.

The visible small intestines are normal in wall thickness and layering (canine duodenum < 0.5 cm and feline duodenum < 0.4 cm; other < 0.3 cm). Small intestinal motility appears adequate (1-3 contractions per min). The lumen of the small intestine is empty with no evidence of obstruction, foreign material or infiltrative disease.

The visible colon is normal in wall thickness (< 0.2 cm) and layering. Contents are consistent with normal formed feces and gas.

Pancreas

The pancreatic parenchyma is appropriately isoechoic to surrounding tissue. Visible capsule is smooth and normal in contour. There is no visible pancreatic duct dilation. There is no evidence of active peripancreatic inflammation.

Free Abdomen

There is no evidence of free peritoneal effusion noted in these images.

A slightly irregular heterogeneous mesenteric lymph node is noted that measures 2.3 cm long and 1.5 cm thick.

PRIMARY FINDINGS

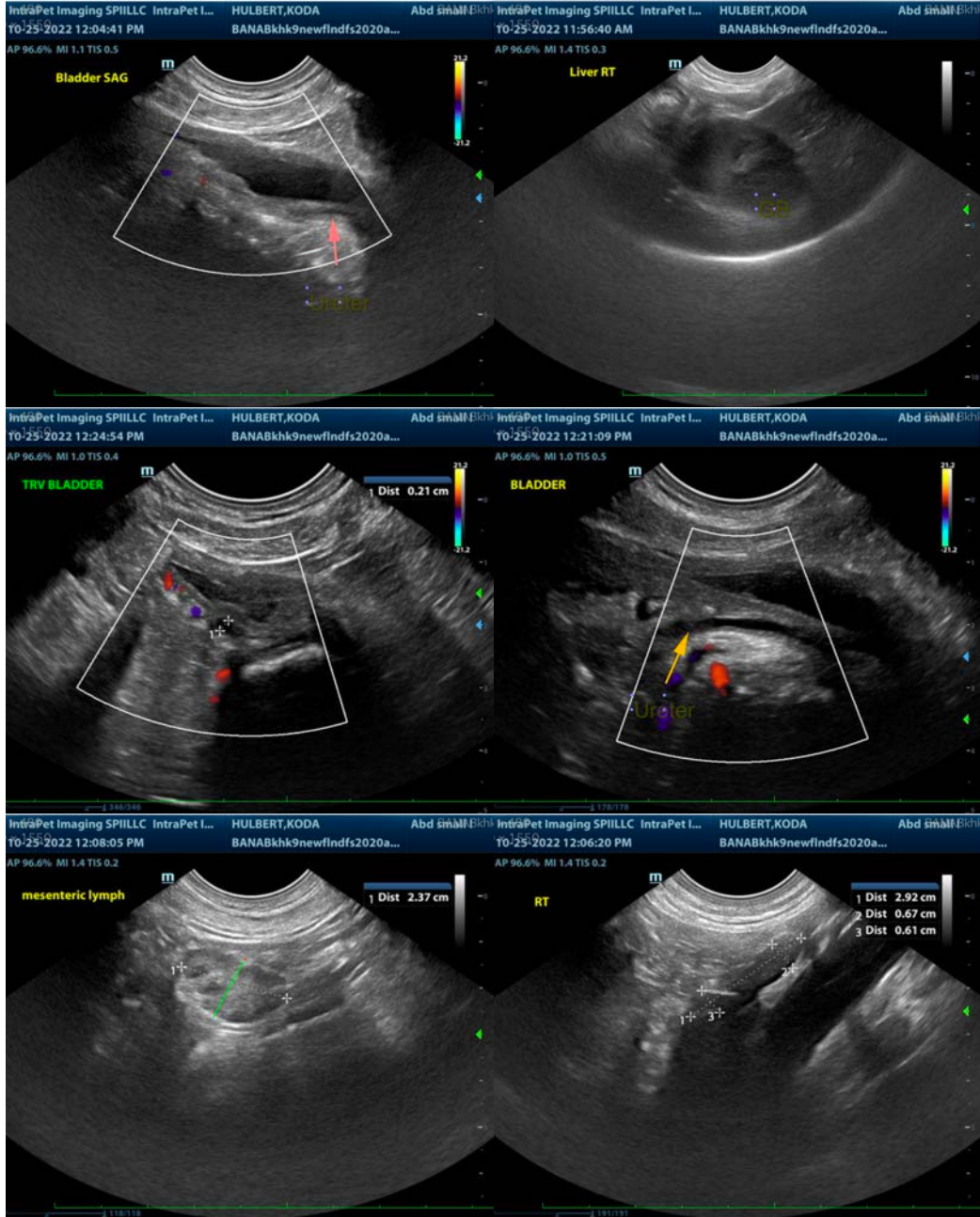
- Ectopic ureter(s) is/are highly suspected.

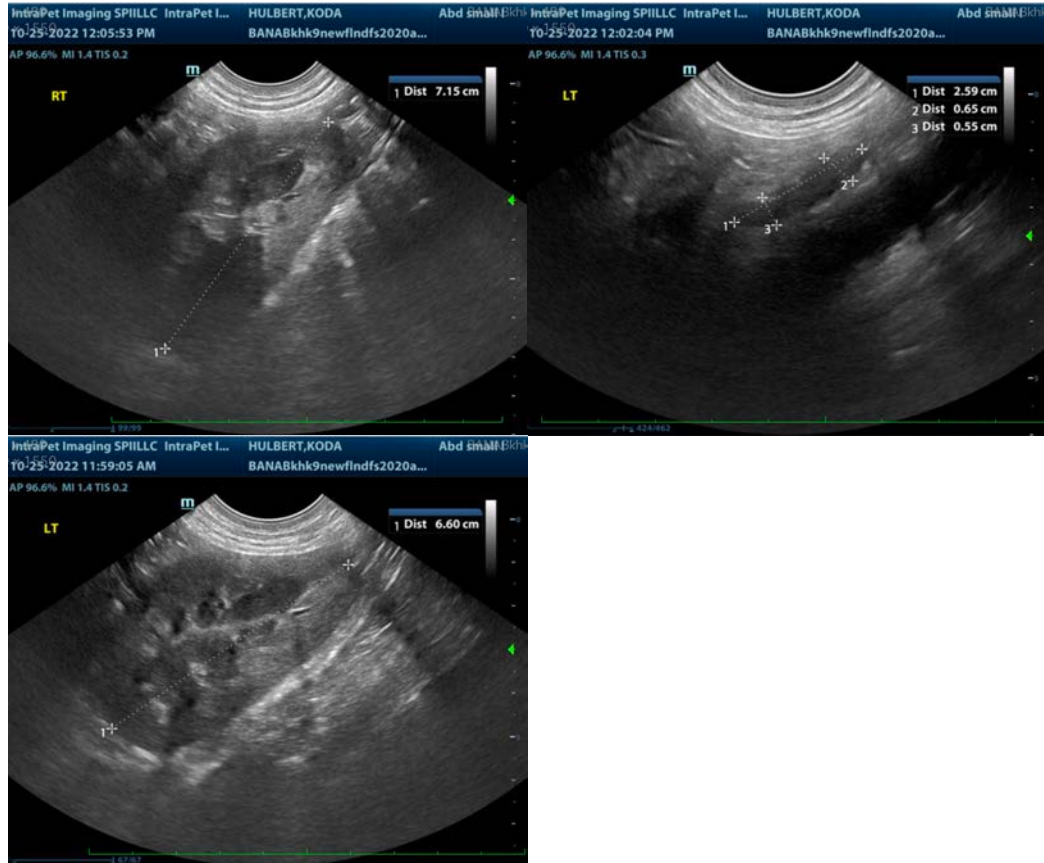
SECONDARY FINDINGS

- **Gallbladder debris** - Cholecystic debris is of unknown clinical significance. It can be seen with biliary stasis from fasting or illness. Cholecystic debris is not necessarily related to hepatobiliary disease. Echogenic bile is most commonly an incidental finding in dogs and should be interpreted in combination with clinical signs such as nausea, inappetence, cranial abdominal discomfort and/or laboratory changes such as increased ALP and/or increased Tbili.
- **Reactive mesenteric lymph nodes** - infiltrative neoplastic disease cannot be ruled out but is considered less likely.

INTERPRETATION OF THE FINDINGS & FURTHER RECOMMENDATIONS

A contrast abdominal CT scan is recommended for confirmation of suspected ectopic ureters and further information about termination, etc. to help determine treatment options such as surgery versus cystoscopy with lasering (if geographically available), etc. In the meantime, given the likelihood of secondary infections, a urinalysis and, if indicated based on urinalysis results, urine culture are recommended. If protein is present in an otherwise quiet sediment, protein quantification with a urine protein to creatinine ration is recommended.





The information and recommendations provided are based on the images presented by the referring veterinarian/sonographer. No evaluation can be communicated regarding pathology that was not visible in the image/video clips provided.

Thank you for this referral. If the clinical or image interpretation does not parallel your findings or if I can be of any further assistance please contact me.

Beth Johnson, DVM, DACVIM
Beth.Johnson@sonopath.com