

**DATE**

10/25/22

**PRESENTING CLINICAL SIGNS****PATIENT**

Juliet Ketzis

History: Since owner adopted her 1 month ago, she hasn't eaten well and has been losing weight. Her previous owner passed away. She was tried on cyproheptadine which didn't work well and then she was tried on Mirataz but that caused a bad reaction with howling/dysphoria. Bloodwork at the shelter in the beginning of September was normal. She presented as a second opinion today and she is icteric with a liver panel that is suggestive of cholangiohepatitis/other hepatic disease with biliary tract involvement. Concerned that this could be neoplastic.

**SPECIES**

Feline

**BREED**

Siamese

**SEX**

Spayed Female

Current Medications: None currently.

Lab Results: ALT=539 U/L (12-130), ALKP=500U/L (14-111), GGT=24 U/L (0-4), T Bili=6.2mg/dL (0-0.9), Chol=359 mg/dL (65-225), Glob 6.2g/dL (2.8-5.1)

Radiographs: Attached.

Date of Previous IntraPet Ultrasound: No previous.

Sedation: Not required to complete full diagnostic ultrasound.

Stat Report: STAT requested.

Imaging Performed By: Rachel Brillhart, RDMS.

**AGE**

10/20/12

**ULTRASONOGRAPHIC EXAMINATION OF THE ABDOMEN****Urinary System**

Urinary bladder is adequately distended with anechoic contents. No masses, inflammatory changes, echogenic sediment or cystoliths are observed. The urinary bladder, trigone and visible pelvic urethra are normal in thickness with a smooth mucosal surface.

**WEIGHT**

5 Pounds

Left kidney is normal is size (2.99 cm), shape and echogenicity. It has smooth peripheral margination. There is a normal 1:3 cortex to medulla ratio with appropriate corticomedullary distinction. There is no evidence of pyelectasia, or infarcts observed. Non-obstructive linear multifocal hyperechoic diverticular foci with acoustic shadowing are noted.

**INTERPRETED BY**Beth Johnson, DVM  
DACVIM

Right kidney is normal is size (3.43 cm), shape and echogenicity. It has smooth peripheral margination. There is a normal 1:3 cortex to medulla ratio with appropriate corticomedullary distinction. There is no evidence of pyelectasia, or infarcts observed. Non-obstructive linear multifocal hyperechoic diverticular foci with acoustic shadowing are noted.

**HOSPITAL NAME**Cat Sense Feline  
Hospital**Adrenal Glands**

Left adrenal gland is normal in size (0.47 cm), shape and overall architecture, echogenicity and echotexture. Visible surrounding vasculature appears normal.

**REFERRING VET**

Dr. Sinclair

Right adrenal gland is normal in size (0.57 cm), shape and overall architecture, echogenicity and echotexture. Visible surrounding vasculature appears normal.

**INVOICE**

17907

**Spleen**

Spleen is subjectively large in size with subtly scalloped or undulating capsular contour. Parenchyma is normal in echogenicity with a mildly coarse/heterogenous echotexture. No focal nodules or masses are observed. Splenic vasculature appears normal.

**Liver**

Liver is subjectively normal in size with normal smooth curvilinear peripheral contour. Parenchyma is appropriately hypoechoic to the spleen in echogenicity and appropriately mildly coarse and homogenous in

echotexture. In the right mid to caudal liver, there is an approximately 1.0 cm in size mass of mixed echogenicity, primarily hyperechoic in echogenicity but containing multiple cysts of varying size. Visible vasculature and biliary tree appear normal without distension or congestion. Gallbladder is moderately distended with anechoic bile as well as suspended and gravity dependent echogenic debris. The wall is smooth without visible thickening. A mildly tortuous but not pathologically distended cystic and common bile duct is noted.

### ***Gastrointestinal***

The visible stomach wall is normal in thickness and layering. The lumen of the stomach is empty with no evidence of obstruction, foreign material or infiltrative disease. Pyloric outflow tract appears patent.

The visible small intestines are normal in wall thickness and layering. Small intestinal motility appears adequate (1-3 contractions per min). The lumen of the small intestine is empty with no evidence of obstruction, foreign material or infiltrative disease.

The visible colon is normal in wall thickness and layering. Contents are consistent with normal formed feces and gas.

### ***Pancreas***

Pancreas is prominent (enlarged) in size, hypoechoic to surrounding tissue and has a mildly irregular undulating contour. Parenchyma is coarse with mixed echogenic remodeling noted. Pancreatic duct dilation is noted.

### ***Free Abdomen***

There is no evidence of peritoneal effusion. There is a small hypoechoic round lymph node just caudal to the liver near the pancreas.

## **ULTRASONOGRAPHIC FINDINGS**

### **Primary Findings**

- Feline biliary cystadenoma – In a senior cat, this liver lesion is most consistent with a/multiple benign biliary cystadenoma(s). Malignancy cannot be ruled out but is considered less likely given lack of clinical signs and/or laboratory changes.
- Scalloped spleen – can be associated with benign or malignant infiltrative disease. Common causes include a reactive spleen secondary to immune stimulus or early infiltrative round cell neoplasia such as lymphoma or mast cell tumor.
- Gallbladder debris- Cholecystic debris is of unknown clinical significance. It can be seen with biliary stasis from fasting or illness, however, it can also be associated with hepatobiliary disease in cats and should be interpreted in combination with clinical signs such as nausea, inappetence, cranial abdominal discomfort and/or laboratory changes such as increased ALP and/or increased Tbili.
- Chronic active pancreatitis. Given the lymphadenopathy and very mildly enhanced hyperechoic mesenteric fat, an acute on chronic process can't be definitively ruled out.

### **Secondary Findings**

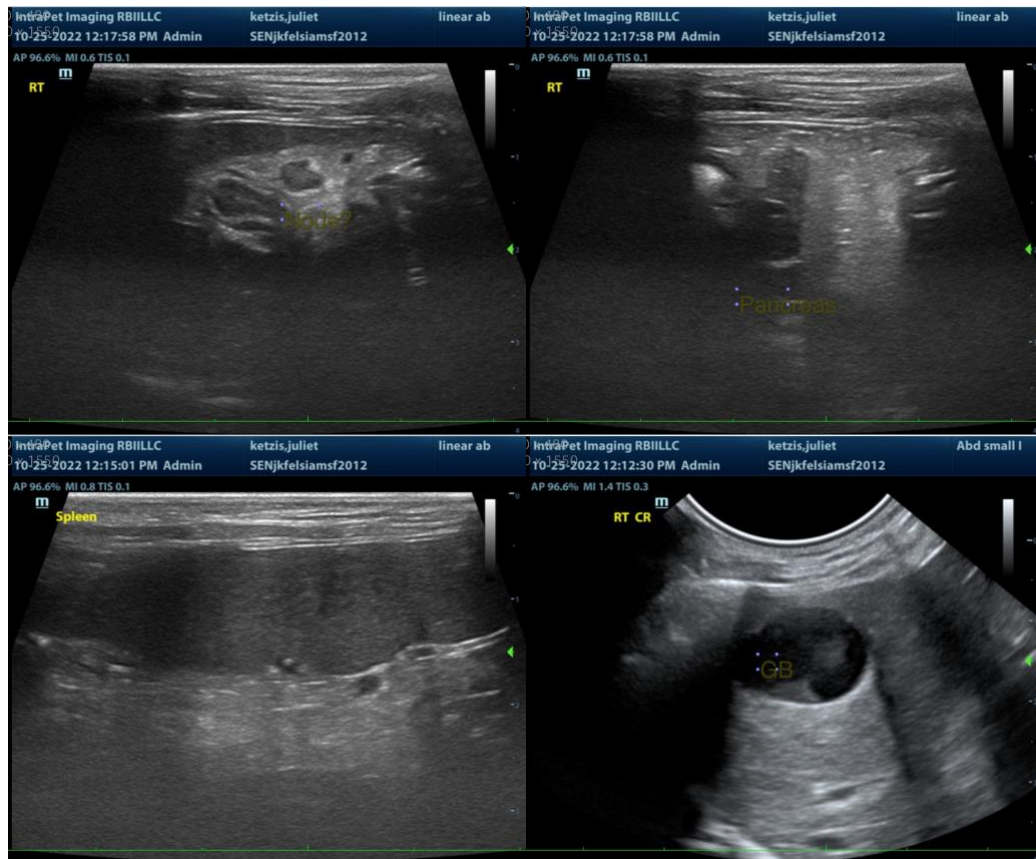
- Nonobstructive dystrophic mineralization bilaterally in the kidneys

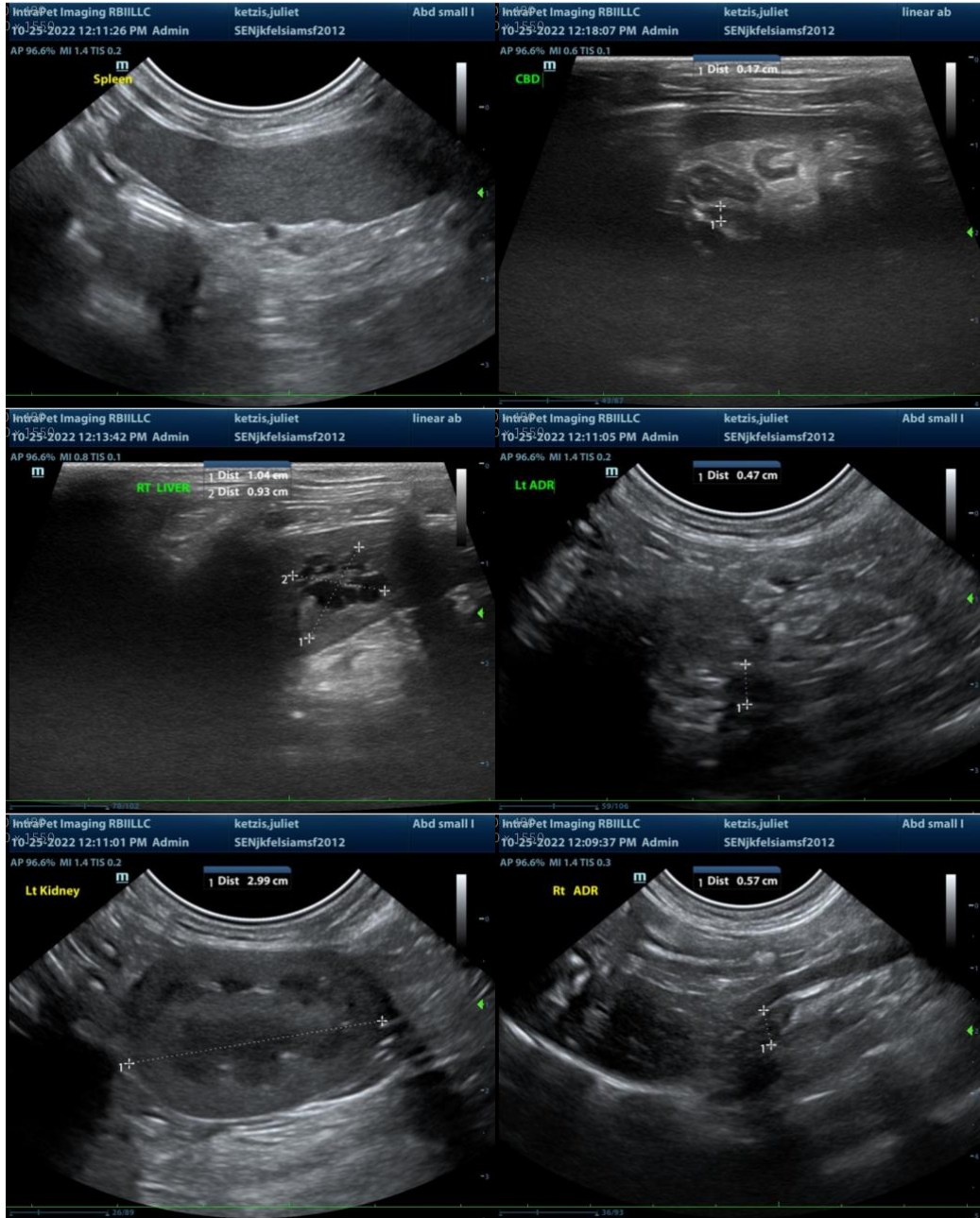
## **INTERPRETATION OF THE FINDINGS & FURTHER RECOMMENDATIONS**

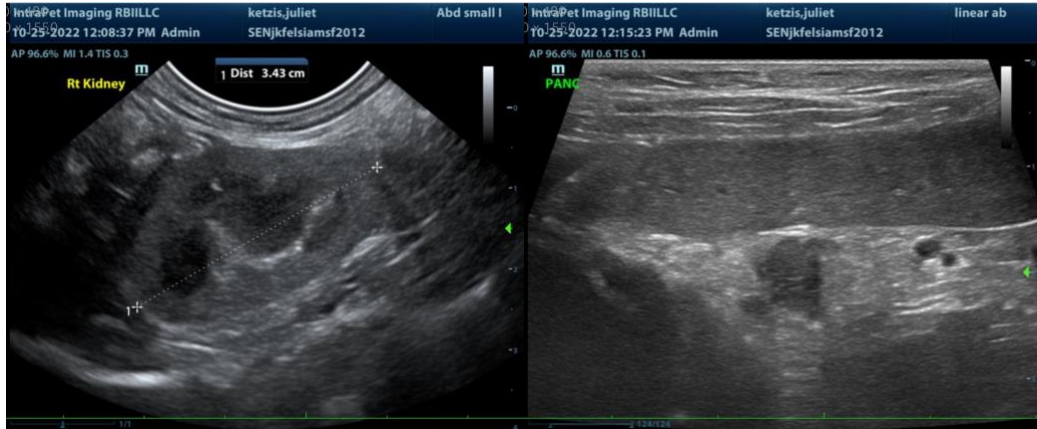
Given this patients reported inappetence prior to liver enzyme changes, combined with pancreatic changes, a gastrointestinal malabsorption panel (including cobalamin, folate, TLI and PLI) to Texas A&M GI Laboratory is recommended for further evaluation of GI and pancreatic function.

The top differential for this patient based on these images, trends toward the benign in the form of cholangitis/cholangiohepatitis or “triaditis”. However, given the appearance of the spleen, a fine needle aspirate of the spleen +/- liver could be considered if patients coagulation status is appropriate.

In the meantime, treatment recommendations include fluid therapy, antiemetics, gastroprotectants, hepatic nutraceuticals, such as ursodiol and/or Denamarin and broad-spectrum antibiotics. Nutritional support is also critically important to prevent progression of and manage suspected current hepatic lipidosis. Additional appetite stimulants and/or given the lack of response previously, feeding tube placement is recommended.







**The information and recommendations provided are based on the images presented by the referring veterinarian. No evaluation can be communicated regarding pathology that was not visible in the image/video clips provided.**

Thank you for this referral. If the clinical or image interpretation does not parallel your findings or if I can be of any further assistance please contact me.

**Beth Johnson, DVM DACVIM**  
Beth.Johnson@SonoPath.com