

**DATE**

10/24/22

PRESENTING CLINICAL SIGNS

History: Indoor only. Chronic soft stool for 3 months. Vomited bile twice the last 2 weeks.

PATIENT

Baby Buttons Ruiz

Current Medications: RC Hydrolyzed HP for last 4 weeks. RC GI diet for 4 weeks prior.

Lab Results: 7/8/22 TT4 2.8 (0.8-4.7). 5/24/22 IOF: All normal except Globulin 5.5 (2.8-5.1), CBC WNL. 6/20/22 Fecal negative.

Date of Previous IntraPet Ultrasound: No previous.

SPECIES

Feline

Sedation: Not required to complete full diagnostic ultrasound.

Stat Report: Not requested.

Imaging Performed By: Stephanie Warga RDCS, RVT.

BREED

DSH

ULTRASONOGRAPHIC EXAMINATION OF THE ABDOMEN**SEX**

Spayed Female

Urinary System

Urinary bladder is adequately distended. It has a normal uniform wall thickness. Contents include primarily anechoic fluid with occasional echogenic non-shadowing debris, most consistent with incidental suspended lipid in a cat, possibly combined with exfoliated cells, mucous and/or small blood clots. Both sterile inflammation as well as urinary tract infection can also present with echogenic debris. No masses or cystoliths are observed. The trigone and visible pelvic urethra are normal in thickness with a smooth mucosal surface.

AGE

6/12/16

Left kidney is normal is size (3.66 cm), shape and echogenicity. It has smooth peripheral margination. There is a normal 1:3 cortex to medulla ratio with appropriate corticomedullary distinction. There is no evidence of pyelectasia, mineral or infarcts observed.

WEIGHT

3.26 Pounds

Right kidney is normal is size (3.64 cm), shape and echogenicity. It has smooth peripheral margination. There is a normal 1:3 cortex to medulla ratio with appropriate corticomedullary distinction. There is no evidence of pyelectasia, mineral or infarcts observed.

INTERPRETED BYBeth Johnson, DVM
DACVIM**Adrenal Glands**

Left adrenal gland is normal in size (0.35 cm), shape and overall architecture, echogenicity and echotexture. Visible surrounding vasculature appears normal.

HOSPITAL NAME

Banfield Columbia

Right adrenal gland is normal in size (0.36 cm), shape and overall architecture, echogenicity and echotexture. Visible surrounding vasculature appears normal.

REFERRING VET

Dr. Landon

Spleen

Spleen is subjectively normal in size with a normal smooth capsular contour. Parenchyma is appropriately finely textured and homogenous with normal echogenicity relative to surrounding tissue (hyperechoic to liver). No focal nodules or masses are observed. Splenic vasculature appears normal.

INVOICE

17896

Liver

Liver is subjectively normal in size with normal smooth curvilinear peripheral contour. Parenchyma is appropriately hypoechoic to the spleen in echogenicity and appropriately mildly coarse and homogenous in echotexture. No focal lesions are observed. Visible vasculature and biliary tree appear normal without distension or congestion.

Gallbladder is non-distended in size. The wall is smooth without visible thickening. Luminal contents are primarily anechoic. There is no evidence of cystic or common bile duct dilation.

Gastrointestinal

The visible stomach wall is normal in thickness and layering. The lumen of the stomach is empty with no evidence of obstruction, foreign material or infiltrative disease. Pyloric outflow tract appears patent.

The visible small intestines are normal in wall thickness and layering. Small intestinal motility appears adequate (1-3 contractions per min). The lumen of the small intestine is empty with no evidence of obstruction, foreign material or infiltrative disease.

The colon wall is diffusely mildly thick, measuring 0.31 cm thick with a disproportionately subjectively thick submucosal layer relative to other layers.

Pancreas

Pancreas is prominent (enlarged) in size, hypoechoic to surrounding tissue and has a mildly irregular undulating contour. Parenchyma is coarse with mixed echogenic remodeling noted. Pancreatic duct dilation is noted.

Free Abdomen

There is no evidence of peritoneal effusion. The mesenteric and colonic/sublumbar lymph nodes are prominent in size with swollen capsular contour. Normal elongated shape (length to width ratio) is maintained. There is no loss of parenchymal detail.

ULTRASONOGRAPHIC FINDINGS

- A mildly diffusely thick colon with a subjectively prominent submucosal layer, which is a finding that can be seen with a variety of inflammatory disorders, as well as infiltrative neoplasia, such as lymphoma, however, is often especially pronounced with parasitic and/or gastrointestinal infectious diseases.
- Reactive mesenteric and colonic/sublumbar lymph nodes – infiltrative neoplastic disease cannot be ruled out but is considered less likely
- Chronic active pancreatitis
- Urinary bladder debris

INTERPRETATION OF THE FINDINGS & FURTHER RECOMMENDATIONS

Given this patient's reported history of mild hyperglobulinemia, recheck chemistry panel is recommended to assess resolution versus progression of the hyperglobulinemia.

In the meantime, a gastrointestinal malabsorption panel (including cobalamin, folate, TLI and PLI) to Texas A&M GI Laboratory is recommended for further evaluation of GI and pancreatic function.

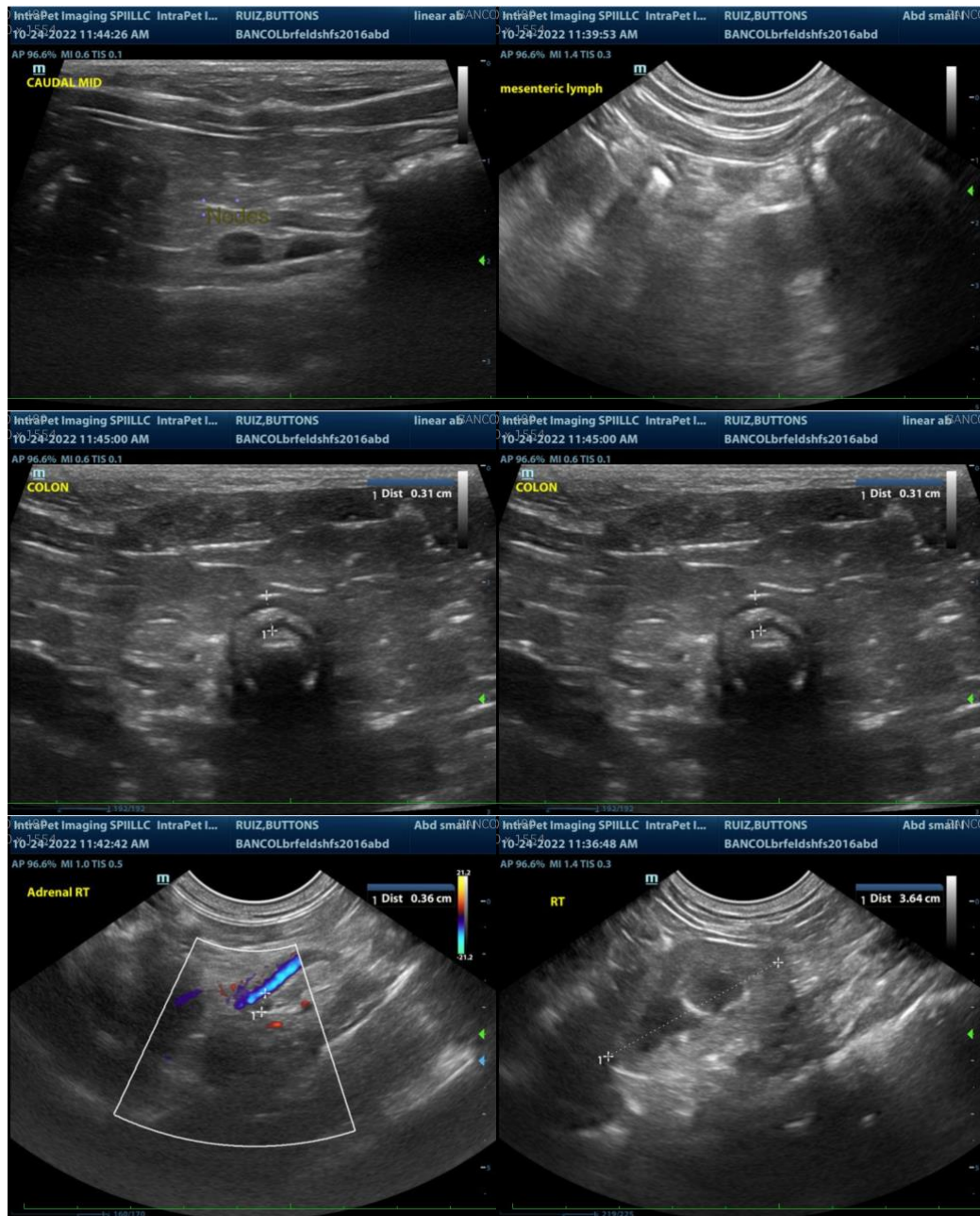
Given the predominantly submucosal thickening, a fecal exam is recommended, as is a fecal enteropathogen PCR panel to Texas A&M GI Laboratory could be considered for further evaluation of possible infectious disease.

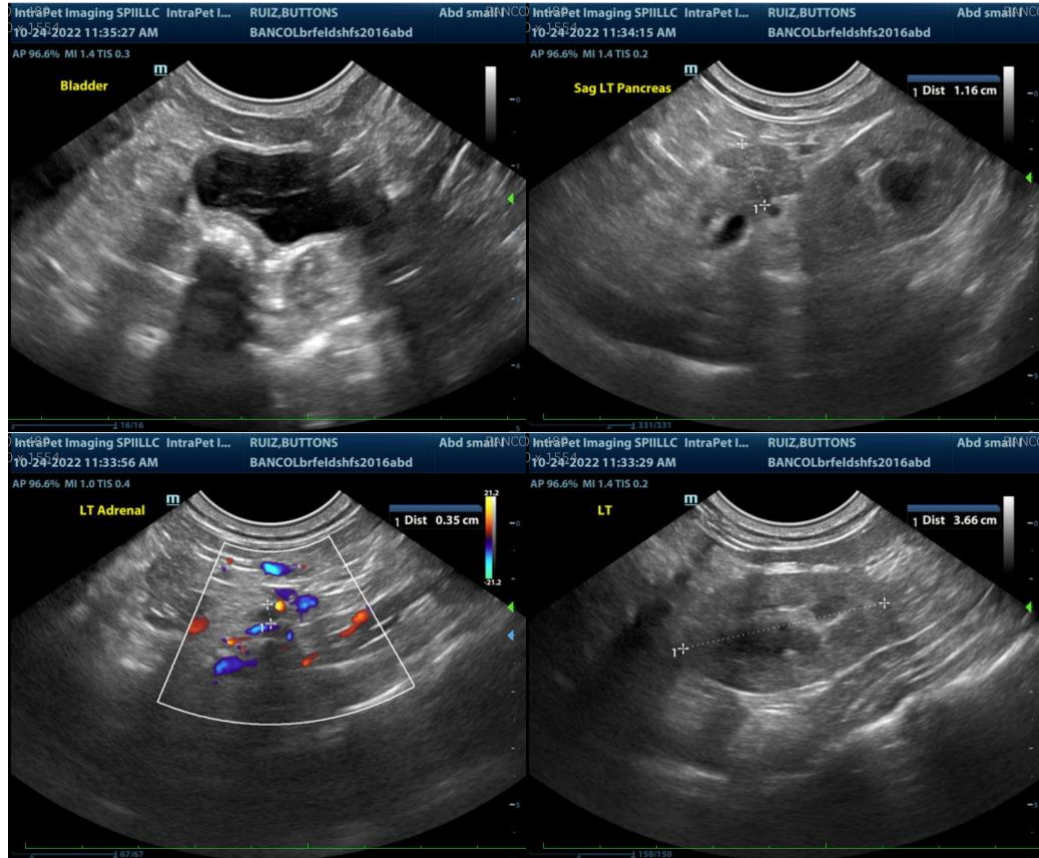
In the meantime, empirical deworming with a 5-day course of Panacur is recommended, as is a probiotic, such as Visbiome or Provable in addition to the reportedly already in place hydrolyzed protein diet.

Ultimately, if clinical signs persist, and a diagnosis is not obtained, both upper and lower

gastroscopy/endoscopy/colonoscopy may be necessary to definitively diagnose and therefore manage the suspected infiltrative bowel disease.

Additionally, if not recently evaluated, a urinalysis and, if indicated based on urinalysis results, urine culture are recommended. If protein is present in an otherwise quiet sediment, protein quantification with a urine protein to creatinine ration is recommended.





The information and recommendations provided are based on the images presented by the referring veterinarian. No evaluation can be communicated regarding pathology that was not visible in the image/video clips provided.

Thank you for this referral. If the clinical or image interpretation does not parallel your findings or if I can be of any further assistance please contact me.

Beth Johnson, DVM DACVIM
Beth.Johnson@SonoPath.com