



| | |
|-----------------------------|--|
| PATIENT | PRESENTING CLINICAL SIGNS |
| Spunky Vander Goor | Weight loss with no explanation. Has been a well-controlled hypothyroid dog on meds and has been doing well on low fat food. History of pancreatitis and osteoarthritis. Is scheduled for a dental next week as well. Has been on Metacam, Gabapentin, Famotidine, Stilbesterol, Amlodipine, Thyro Tabs. Had previous ultrasound (Aug 2019) and had early gallbladder mucocele, moderately severe ileus, chronic active pancreatitis, low grade splenopathy, severe gastroenteropathy and lymphadenopathy. |
| SPECIES | Abnormal PE/Chem/CBC/UA Results: hyaline casts on u/a Urea 11.8 (3.2-11.0) ALP 168 (5-160) Amylase 1754 (337-1469) Lipase 448 (0-250) |
| Canine | |
| BREED | ULTRASONOGRAPHIC EXAMINATION OF THE ABDOMEN |
| Lab x Shep | Urinary System |
| SEX | The urinary bladder is moderately distended with anechoic contents. No masses, inflammatory changes, echogenic sediment or cystoliths are observed. The urinary bladder, trigone and visible pelvic urethra are normal in thickness with a smooth mucosal surface. |
| Spayed Female | |
| AGE | The right kidney is normal in size (6.23 cm), shape and echogenicity. It has smooth peripheral margination. There is a normal 1:3 cortex to medulla ratio with appropriate corticomedullary distinction. There is no evidence of pyelectasia or infarcts observed. Non-obstructive linear multifocal hyperechoic diverticular foci with acoustic shadowing are noted. |
| 12 Years | |
| WEIGHT | The left kidney is normal in size (6.76 cm), shape and echogenicity. It has smooth peripheral margination. There is a normal 1:3 cortex to medulla ratio with appropriate corticomedullary distinction. There is no evidence of pyelectasia or infarcts observed. Non-obstructive linear multifocal hyperechoic diverticular foci with acoustic shadowing are noted. |
| 69 Pounds | |
| INTERPRETED BY | Adrenal Glands |
| Beth Johnson, DVM DACVIM | The right adrenal gland is normal in size (1.9 cm long x 1.8 cm at the cranial pole and 0.80 cm at the caudal pole), shape and contour. Corticomedullary structure is unremarkable. Visible surrounding vasculature appears normal. |
| IMAGING PERFORMED BY | The left adrenal gland is normal in size (2.3 cm long x 0.50 cm at the cranial pole and 0.47 cm at the caudal pole), shape and contour. Corticomedullary structure is unremarkable. Visible surrounding vasculature appears normal. |
| Crystal Hill | |
| HOSPITAL NAME | Spleen |
| Norwich Vet Clinic | Spleen is subjectively large in size with normal smooth margins. Parenchyma is normal in echogenicity with a coarse/heterogenous echotexture. A 1.3 cm x 1.8 cm mixed, partially mineralized, non-capsule disrupting nodule is noted near the head of the spleen. Splenic vasculature appears normal. |
| REFERRING VET | Liver |
| Dr. Kungl | Liver is subjectively enlarged (swollen contour) without disruption of architecture. It has a normal homogenous echotexture. Parenchyma is diffusely hyperechoic characterized by less prominent than normal portal vein walls and increased echogenicity relative to the spleen and falciform fat. No focal lesions are observed. Visible vasculature and biliary tree appear normal without distension or congestion. |
| INVOICE | Gallbladder |
| 42212 | Gallbladder is moderately distended with anechoic bile as well as suspended and gravity dependent echogenic debris. The wall is smooth without visible thickening. There is no evidence of cystic or CBD dilation. There is no evidence of effusion or inflammation. |
| DATE | |
| 10/19/22 | |



PATIENT

Gastrointestinal

Spunky Vander Goor

The stomach wall is normal in thickness (canine < 0.5 cm and feline < 0.4 cm) and layering. The lumen of the stomach is empty with no evidence of obstruction, foreign material or infiltrative disease. Pyloric outflow tract appears patent.

SPECIES

Canine

The visible small intestines are normal in wall thickness and layering (canine duodenum < 0.5 cm and feline duodenum < 0.4 cm; other < 0.3 cm). Small intestinal motility appears adequate (1-3 contractions per min). The lumen of the small intestine is empty with no evidence of obstruction, foreign material or infiltrative disease.

BREED

Lab x Shep

The visible colon is normal in wall thickness (< 0.2 cm) and layering. Contents are consistent with normal formed feces and gas.

SEX

Spayed Female

Pancreas

The pancreatic parenchyma is appropriately isoechoic to surrounding tissue. Visible capsule is smooth and normal in contour. There is no visible pancreatic duct dilation. There is no evidence of active peripancreatic inflammation.

AGE

12 Years

Free Abdomen

There is no evidence of free peritoneal effusion noted in these images.

WEIGHT

69 Pounds

There is no apparent lymphadenopathy noted in these images.

PRIMARY FINDINGS

- **Coarse splenomegaly** – can be associated with congestion caused by sedation (if sedated) but can also be associated with diffuse infiltrative disease. Both benign conditions such as extramedullary hematopoiesis, lymphoid hyperplasia, as well as infiltrative neoplastic diseases such as round cell neoplasia should be considered. The partially mineralized mixed nodule may represent a benign cyst, hematoma, nodular hyperplasia, extramedullary hematopoiesis, or, given the partial suspected mineralization, fibrosis or calcification of an old hematoma or infarct, chronic inflammation, granulomatous disease, etc. Metastatic disease or infiltrative neoplasia is considered possible but less likely.
- **Hyperechoic hepatomegaly** - This appearance is non-specific and most consistent with a benign steroid (endocrine) or vacuolar hepatopathy or reactive or idiopathic hepatopathy. Inflammatory and/or infiltrative disease (such as round cell neoplasia) are also possible, but considered less likely.
- **Gallbladder debris** - Cholecystic debris is of unknown clinical significance. It can be seen with biliary stasis from fasting or illness. Cholecystic debris is not necessarily related to hepatobiliary disease. Echogenic bile is most commonly an incidental finding in dogs and should be interpreted in combination with clinical signs such as nausea, inappetence, cranial abdominal discomfort and/or laboratory changes such as increased ALP and/or increased Tbili.
**This change is very mild and not consistent with this patient's reported previous emerging mucocele.

INTERPRETED BY

Beth Johnson, DVM
DACVIM

IMAGING PERFORMED BY

Crystal Hill

HOSPITAL NAME

Norwich Vet Clinic

REFERRING VET

Dr. Kungl

INVOICE

42212

SECONDARY FINDINGS

- Non-obstructive dystrophic mineralization in the kidneys bilaterally

DATE

10/19/22

**There is no evidence of lymphadenopathy or gastrointestinal disease, as was reported previously.



PATIENT

Spunky Vander Goor

SPECIES

Canine

BREED

Lab x Shep

SEX

Spayed Female

AGE

12 Years

WEIGHT

69 Pounds

INTERPRETED BY

Beth Johnson, DVM
DACVIM

IMAGING PERFORMED BY

Crystal Hill

HOSPITAL NAME

Norwich Vet Clinic

REFERRING VET

Dr. Kungl

INVOICE

42212

DATE

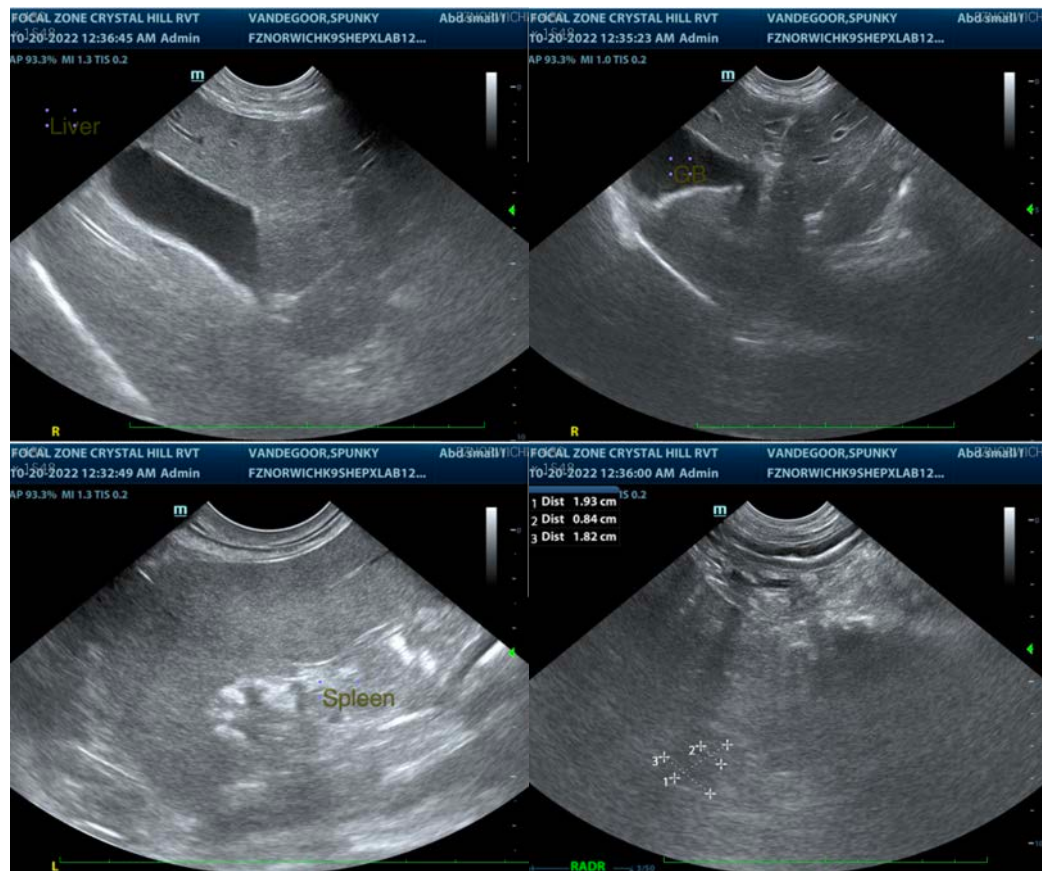
10/19/22

INTERPRETATION OF THE FINDINGS & FURTHER RECOMMENDATIONS

There is not an ultrasonographically obvious explanation for this patient's weight loss. Recommendations include checking a T4 to be sure that the thyroid supplement dose doesn't need to be reduced, if not recently evaluated. Additionally, investigation of caloric intake is recommended to ensure there has not been an inadvertent drop in calories or competitive eating environment, etc.

If the weight loss is persistent despite appropriate calories, and the T4 is not too high, next diagnostic recommendation is a gastrointestinal malabsorption panel (including cobalamin, folate, TLI and PLI) to Texas A&M GI Laboratory for further evaluation of GI and pancreatic function, especially given this patient's history of a previously reported enteropathy.

In the meantime, empirical deworming with a 5-day course of Panacur is recommended.





PATIENT

Spunky Vander Goor

SPECIES

Canine

BREED

Lab x Shep

SEX

Spayed Female

AGE

12 Years

WEIGHT

69 Pounds

INTERPRETED BY

Beth Johnson, DVM
DACVIM

IMAGING PERFORMED BY

Crystal Hill

HOSPITAL NAME

Norwich Vet Clinic

REFERRING VET

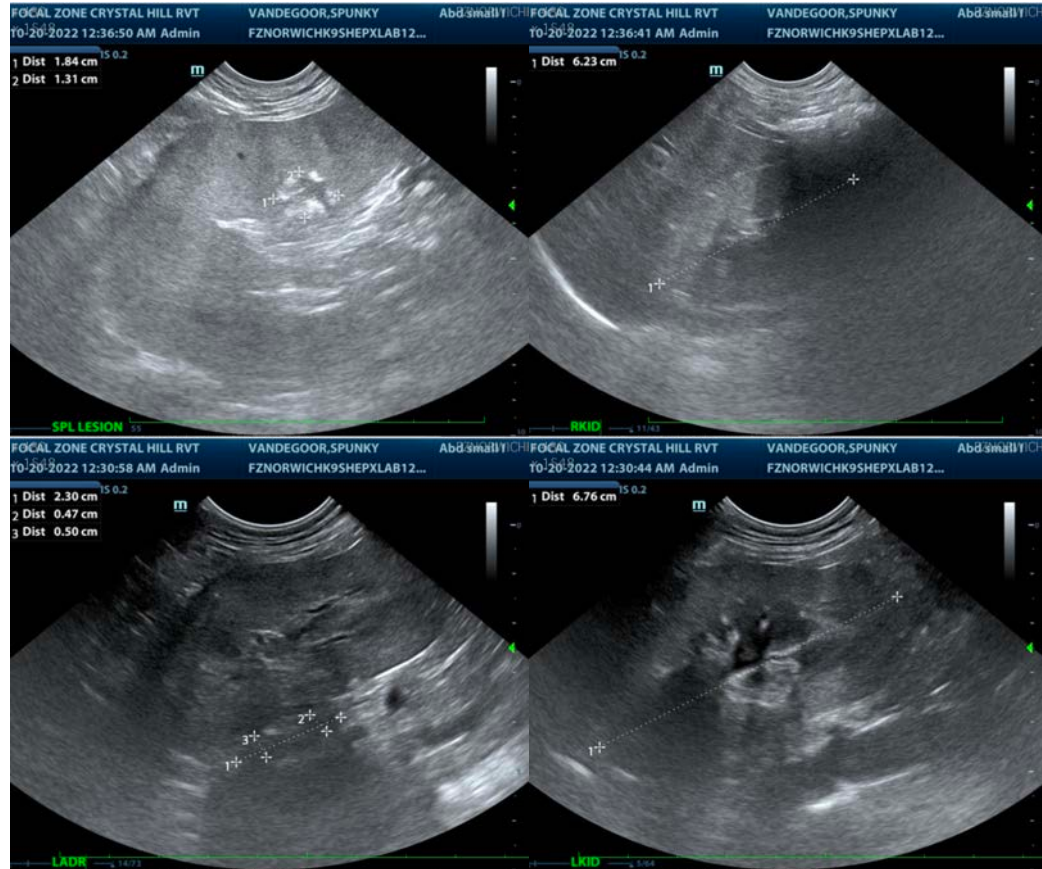
Dr. Kungl

INVOICE

42212

DATE

10/19/22



The information and recommendations provided are based on the images presented by the referring veterinarian/sonographer. No evaluation can be communicated regarding pathology that was not visible in the image/video clips provided.

Thank you for this referral. If the clinical or image interpretation does not parallel your findings or if I can be of any further assistance please contact me.

Beth Johnson, DVM, DACVIM
Beth.Johnson@sonopath.com