



PATIENT

Mason Graves

SPECIES

Feline

BREED

DSH

SEX

Neutered Male

AGE

13 Years

WEIGHT

3.65 kg

INTERPRETED BY

Beth Johnson, DVM
DACVIM

IMAGING PERFORMED BY

Wendy Turner

HOSPITAL NAME

Pennsauken AH & UC

REFERRING VET

Wendy Turner

INVOICE

17654

DATE

10/10/22

PRESENTING CLINICAL SIGNS

History: Weight loss 1 month. Urolithiasis noted >1yr ago. Hematuria noted only on expression of bladder today for urine collection.

Abnormal PE/Chem/CBC/UA Results: BCS 4/9 with moderate generalized muscle atrophy. Small thyroid nodule bilaterally. Edentulous. Labs: WBC's 26K (neutrophils). T4 1.3ug/dl. Urine analysis pending. BW attached.

ULTRASONOGRAPHIC EXAMINATION OF THE ABDOMEN

Urinary System

Urinary bladder is adequately distended with anechoic contents, as well as some echogenic suspended debris, gravity dependent debris and mineral/sand. There is an approximately 1.0 cm irregular echogenic density settled along the dependent wall that does not shadow, consistent with mucus, blood clot or potentially an accumulation of cells and crystal debris. The urinary bladder trigone and visible pelvic urethra are normal in thickness with a smooth mucosal surface.

Left kidney is normal is size (4.03 cm), shape and echogenicity. It has smooth peripheral margination. There is a normal 1:3 cortex to medulla ratio with appropriate corticomedullary distinction. There is no evidence of pyelectasia, or infarcts observed. Non-obstructive linear multifocal hyperechoic diverticular foci with acoustic shadowing are noted.

Right kidney is normal is size (3.56 cm), shape and echogenicity. It has smooth peripheral margination. There is a normal 1:3 cortex to medulla ratio with appropriate corticomedullary distinction. There is no evidence of pyelectasia, or infarcts observed. Non-obstructive linear multifocal hyperechoic diverticular foci with acoustic shadowing are noted.

Adrenal Glands

Left adrenal gland is normal in size (1.0 cm long x 0.31 cm at cranial pole and 0.32 cm at caudal pole), shape and overall architecture, echogenicity and echotexture. Visible surrounding vasculature appears normal.

Right adrenal gland is normal in size (0.31 cm at cranial pole and 0.4 cm at caudal pole), shape and overall architecture, echogenicity and echotexture. Visible surrounding vasculature appears normal.

Spleen

Spleen is subjectively normal in size with a normal smooth capsular contour. Parenchyma is appropriately finely textured and homogenous with normal echogenicity relative to surrounding tissue (hyperechoic to liver). No focal nodules or masses are observed. Splenic vasculature appears normal.

Liver

Liver is subjectively normal in size with normal smooth curvilinear peripheral contour. Parenchyma is appropriately hypoechoic to the spleen in echogenicity and appropriately mildly coarse and homogenous in echotexture. No focal lesions are observed. Visible vasculature and biliary tree appear normal without distension or congestion.

Gallbladder is non-distended in size. The wall is smooth without visible thickening. Luminal contents are primarily anechoic. There is no evidence of cystic or common bile duct dilation.

Gastrointestinal



PATIENT

Mason Graves

The visible stomach wall is normal in thickness and layering. The lumen of the stomach is empty with no evidence of obstruction, foreign material or infiltrative disease. Pyloric outflow tract appears patent.

SPECIES

Feline

The visible small intestines are normal in wall thickness and layering. Small intestinal motility appears adequate (1-3 contractions per min). The lumen of the small intestine is empty with no evidence of obstruction, foreign material or infiltrative disease.

BREED

DSH

The visible colon is normal in wall thickness and layering. Contents are consistent with normal formed feces and gas.

SEX

Neutered Male

Pancreas

The observed pancreas appears appropriately isoechoic to surrounding omental fat. Visible capsule is smooth and normal in contour. Visible pancreatic parenchyma is homogenous and unremarkable. There is no visible pancreatic duct dilation. There is no evidence of active peripancreatic inflammation.

Free Abdomen

AGE

13 Years

There is no evidence of peritoneal effusion. There is no apparent lymphadenopathy.

ULTRASONOGRAPHIC FINDINGS

Primary Findings

WEIGHT

3.65 kg

- Urinary bladder debris, including an approximately 1.0 cm in size echogenic density consistent with mucus, blood clot or accumulation of the above.

Secondary Findings

INTERPRETED BY

Beth Johnson, DVM
DACVIM

- Nonobstructive dystrophic mineralization bilaterally

INTERPRETATION OF THE FINDINGS & FURTHER RECOMMENDATIONS

IMAGING PERFORMED BY

Wendy Turner

There is not an obvious ultrasonographic cause for this patient reported weight loss. The weight loss should be further evaluated in terms of appetite. If this patients appetite is decreased, it could be secondary to chronic urinary signs, however, if the weight loss is in the face of a normal appetite, then maldigestion or malabsorptive condition could be considered and a gastrointestinal malabsorption panel (including cobalamin, folate, TLI and PLI) to Texas A&M GI Laboratory is recommended for further evaluation of GI and pancreatic function. A urinalysis, as is already reportedly pending is recommended, followed by a cystocentesis obtained urine culture if possible.

HOSPITAL NAME

Pennsauken AH & UC

REFERRING VET

Wendy Turner

In the meantime, recommendations include maximizing water consumption with things like water fountains, canned food, etc., as well as reducing stress. Transition to a urinary health diet, such as Royal Canin urinary SO or similar could also be considered. Empirical deworming with a 5-day course of Panacur is recommended to address both fecal parasites, as well as parasites that can affect the urinary tract.

INVOICE

17654

DATE

10/10/22



PATIENT

Mason Graves

SPECIES

Feline

BREED

DSH

SEX

Neutered Male

AGE

13 Years

WEIGHT

3.65 kg

INTERPRETED BY

Beth Johnson, DVM
DACVIM

IMAGING PERFORMED BY

Wendy Turner

HOSPITAL NAME

Pennsauken AH & UC

REFERRING VET

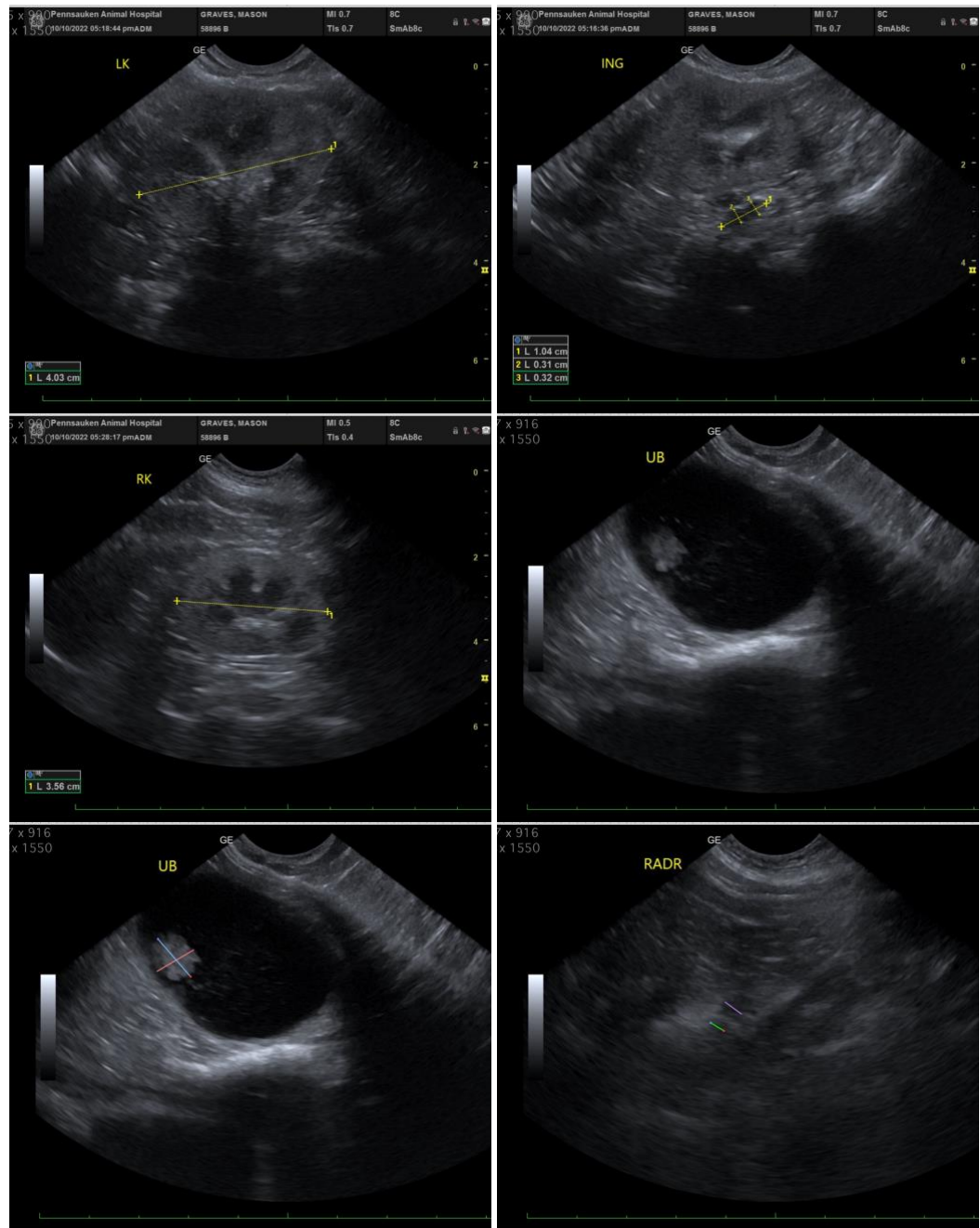
Wendy Turner

INVOICE

17654

DATE

10/10/22



The information and recommendations provided are based on the images presented by the referring veterinarian. No evaluation can be communicated regarding pathology that was not visible in the image/video clips provided.

Thank you for this referral. If the clinical or image interpretation does not parallel your findings or if I can be of any further assistance please contact me.

Beth Johnson, DVM DACVIM



PATIENT

Beth.Johnson@SonoPath.com

Mason Graves

SPECIES

Feline

BREED

DSH

SEX

Neutered Male

AGE

13 Years

WEIGHT

3.65 kg

INTERPRETED BY

Beth Johnson, DVM
DACVIM

**IMAGING
PERFORMED BY**

Wendy Turner

HOSPITAL NAME

Pennsauken AH & UC

REFERRING VET

Wendy Turner

INVOICE

17654

DATE

10/10/22