



PATIENT

Mason Hwang

SPECIES

Canine

BREED

Toy Poodle

SEX

Neutered Male

AGE

10 Years

WEIGHT

16.6 Pounds

INTERPRETED BY

Beth Johnson, DVM
DACVIM

IMAGING PERFORMED BY

Kelly Vazquez

HOSPITAL NAME

Animal Paradise
Hospital

REFERRING VET

Dr. ElShafie

INVOICE

20507

DATE

1/9/23

PRESENTING CLINICAL SIGNS

History: Patient presents for ALP of 403. No current reported meds.

ULTRASONOGRAPHIC EXAMINATION OF THE ABDOMEN

Urinary System

Urinary bladder is adequately distended with anechoic contents. No masses, inflammatory changes, echogenic sediment or cystoliths are observed. The urinary bladder, trigone and visible pelvic urethra are normal in thickness with a smooth mucosal surface.

Prostate is normal in size, echotexture and echogenicity for a neutered male.

Left kidney is normal is size (4.54 cm), shape and echogenicity. It has smooth peripheral margination. There is a normal 1:3 cortex to medulla ratio with appropriate corticomedullary distinction. There is no evidence of pyelectasia, mineral or infarcts observed.

Right kidney is normal is size (5.12 cm), shape and echogenicity. It has smooth peripheral margination. There is a normal 1:3 cortex to medulla ratio with appropriate corticomedullary distinction. There is no evidence of pyelectasia, mineral or infarcts observed.

Adrenal Glands

Left adrenal gland is normal in size (1.68 cm long x 0.58 cm at cranial pole and 0.51 cm at caudal pole), shape and overall architecture, echogenicity and echotexture. Visible surrounding vasculature appears normal.

Right adrenal gland is normal in size (1.56 cm long x 0.75 cm at cranial pole and 0.86 cm at caudal pole), shape and overall architecture, echogenicity and echotexture. Visible surrounding vasculature appears normal.

Spleen

Spleen is subjectively normal in size with a normal smooth capsular contour. Parenchyma is appropriately finely textured and homogenous with normal echogenicity relative to surrounding tissue (hyperechoic to liver). No focal nodules or masses are observed. Splenic vasculature appears normal.

Liver

Liver is subjectively normal in size with normal smooth curvilinear peripheral contour. Parenchyma is appropriately hypoechoic to the spleen in echogenicity and appropriately mildly coarse and homogenous in echotexture. No focal lesions are observed. Visible vasculature and biliary tree appear normal without distension or congestion.

Gallbladder is moderately distended with anechoic bile as well as mild suspended and gravity dependent echogenic debris. The wall is smooth without visible thickening. There is no evidence of cystic or CBD dilation. There is no evidence of effusion or inflammation.

Gastrointestinal

The visible stomach wall is normal in thickness and layering. The lumen of the stomach is empty with no evidence of obstruction, foreign material or infiltrative disease. Pyloric outflow tract appears patent.



PATIENT

Mason Hwang

The visible small intestines are normal in wall thickness and layering. Small intestinal motility appears adequate (1-3 contractions per min). The lumen of the small intestine is empty with no evidence of obstruction, foreign material or infiltrative disease.

SPECIES

Canine

The visible colon is normal in wall thickness and layering. Contents are consistent with normal formed feces and gas.

Pancreas

BREED

Toy Poodle

The observed pancreas is prominent (enlarged) in size, and mildly irregular in shape with a slightly undulating contour. Parenchyma is coarse in echotexture and heterogenous with a primarily hyperechoic echogenicity. Pancreatic duct is mildly dilated.

Free Abdomen

SEX

Neutered Male

There is no evidence of peritoneal effusion. There is no apparent lymphadenopathy.

ULTRASONOGRAPHIC FINDINGS

AGE

10 Years

Primary Findings

- Chronic active pancreatitis with hyperechoic pancreas – This finding is suggestive of pancreatic fibrosis, possibly secondary to chronic pancreatitis. A TLI is recommended to rule out exocrine pancreatic insufficiency (EPI), especially if clinical signs (weight loss, diarrhea, etc.) are present.

WEIGHT

16.6 Pounds

Secondary Findings

- Gallbladder debris - Cholecystic debris is of unknown clinical significance. It can be seen with biliary stasis from fasting or illness. Cholecystic debris is not necessarily related to hepatobiliary disease. Echogenic bile is most commonly an incidental finding in dogs and should be interpreted in combination with clinical signs such as nausea, inappetence, cranial abdominal discomfort and/or laboratory changes such as increased ALP and/or increased Tbili.

INTERPRETED BY

Beth Johnson, DVM
DACVIM

INTERPRETATION OF THE FINDINGS & FURTHER RECOMMENDATIONS

A gastrointestinal malabsorption panel (including cobalamin, folate, TLI and PLI) to Texas A&M GI Laboratory is recommended for further evaluation of GI and pancreatic function.

IMAGING PERFORMED BY

Kelly Vazquez

HOSPITAL NAME

Animal Paradise
Hospital

Pending PLI, TLI results, etc., if tolerated, transition in diet to a low-fat diet could be considered, however, without supporting clinical signs, if ALP remains relatively static, intervention beyond just routine monitoring may not be necessary.

REFERRING VET

Dr. ElShafie

INVOICE

20507

DATE

1/9/23



PATIENT

Mason Hwang

SPECIES

Canine

BREED

Toy Poodle

SEX

Neutered Male

AGE

10 Years

WEIGHT

16.6 Pounds

INTERPRETED BY

Beth Johnson, DVM
DACVIM

IMAGING PERFORMED BY

Kelly Vazquez

HOSPITAL NAME

Animal Paradise
Hospital

REFERRING VET

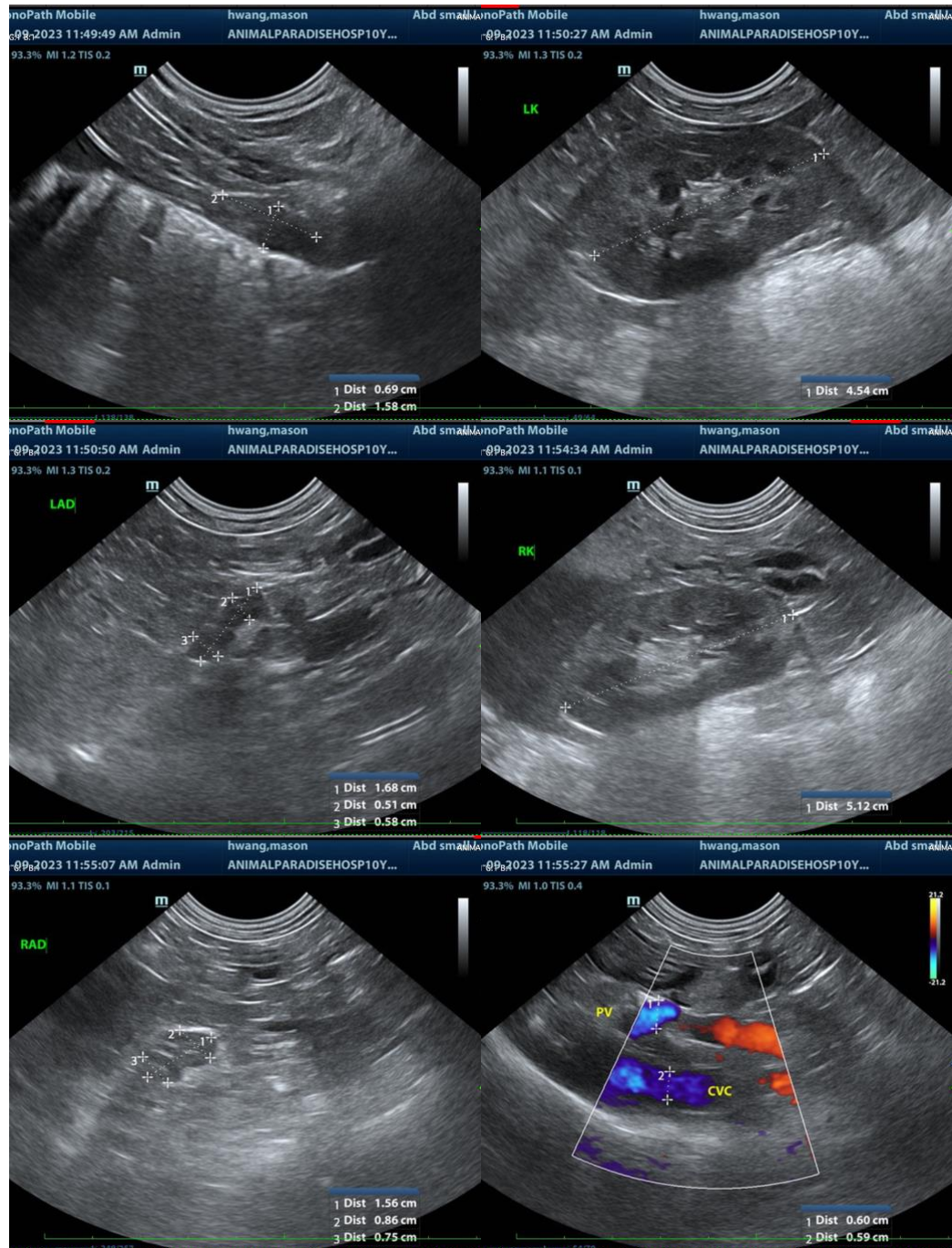
Dr. ElShafie

INVOICE

20507

DATE

1/9/23





PATIENT

Mason Hwang

SPECIES

Canine

BREED

Toy Poodle

SEX

Neutered Male

AGE

10 Years

WEIGHT

16.6 Pounds

INTERPRETED BY

Beth Johnson, DVM
DACVIM

IMAGING PERFORMED BY

Kelly Vazquez

HOSPITAL NAME

Animal Paradise
Hospital

REFERRING VET

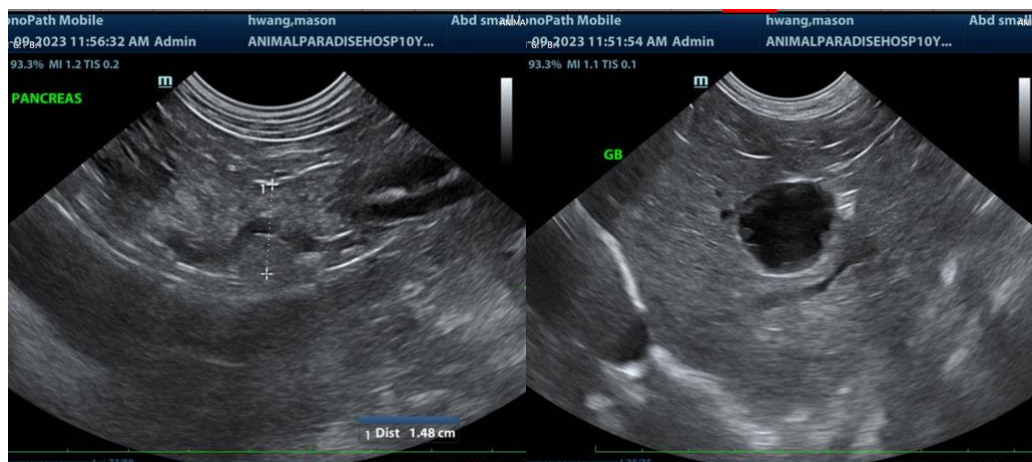
Dr. ElShafie

INVOICE

20507

DATE

1/9/23



The information and recommendations provided are based on the images presented by the referring veterinarian. No evaluation can be communicated regarding pathology that was not visible in the image/video clips provided.

Thank you for this referral. If the clinical or image interpretation does not parallel your findings or if I can be of any further assistance please contact me.

Beth Johnson, DVM DACVIM

Beth.Johnson@SonoPath.com