



PATIENT

Teddy Phillips

SPECIES

Canine

BREED

Cocker Spaniel x

SEX

Neutered Male

AGE

7 Years

WEIGHT

10.3 kg

INTERPRETED BY

Beth Johnson, DVM
 DACVIM

IMAGING PERFORMED BY

Kelly Reschny

HOSPITAL NAME

Aldershot Animal
 Hospital

REFERRING VET

Dr. Wallace

INVOICE

72084

DATE

1/8/26

PRESENTING CLINICAL SIGNS

P receives 6mo abd u/s every 6 months after anal gland Adenocarcinoma diagnosed in 2024.

ULTRASONOGRAPHIC EXAMINATION OF THE ABDOMEN

Urinary System

Urinary bladder is adequately distended. It has a normal uniform wall thickness. Contents include primarily anechoic fluid with a moderate amount of echogenic non-shadowing debris, most consistent with exfoliated cells, mucous and/or small blood clots. Both sterile inflammation as well as urinary tract infection can present with echogenic debris. No masses or cystoliths are observed. The trigone and visible pelvic urethra are normal in thickness with a smooth mucosal surface.

Prostate is normal in size, echotexture and echogenicity for a neutered male.

Kidneys are overall normal in size and shape with smooth peripheral margination. A normal 1:3 cortex to medulla ratio is maintained. The medulla and cortices are uniform in texture with some mild increased cortical echogenicity and mild loss of corticomedullary distinction, expected in this age patient. There is no evidence of pyelectasia or infarcts observed. Left kidney measured 4.87 cm. Right kidney measured 3.96 cm. Punctate non-obstructive mineral densities are noted bilaterally.

Adrenal Glands

The right adrenal gland is normal in size (0.89 cm at cranial pole and 0.41 cm at caudal pole), shape and overall architecture, echogenicity and echotexture. Visible surrounding vasculature appears normal.

The left adrenal gland is normal in size (0.50 cm at cranial pole and 0.45 cm at caudal pole), shape and overall architecture, echogenicity and echotexture. Visible surrounding vasculature appears normal.

Spleen

The spleen is subjectively normal in size with a normal smooth capsular contour. Parenchyma is appropriately finely textured and homogenous with normal echogenicity relative to surrounding tissue (hyperechoic to liver), except for an approximately 0.80 cm in diameter hypo- to anechoic non-capsule disrupting nodule near the cranial medial aspect of the spleen. Splenic vasculature appears normal.

Liver

The liver is subjectively normal in size with normal smooth curvilinear peripheral contour. Parenchyma is appropriately hypoechoic to the spleen in echogenicity and appropriately mildly coarse and homogenous in echotexture. No focal lesions are observed. Visible vasculature and biliary tree appear normal without distension or congestion.

The gallbladder is non-distended in size. The wall is smooth without visible thickening. Luminal contents are primarily anechoic. There is no evidence of cystic or common bile duct dilation.

Gastrointestinal

The visible stomach wall is normal in thickness and layering. The lumen of the stomach is mildly distended with very echogenic reverberation artifact from intraluminal gas. There is no evidence of obstruction, foreign material, or infiltrative disease; however, visualization is partially inhibited by gas.



PATIENT

Teddy Phillips

SPECIES

Canine

BREED

Cocker Spaniel x

SEX

Neutered Male

AGE

7 Years

WEIGHT

10.3 kg

INTERPRETED BY

Beth Johnson, DVM
DACVIM

IMAGING PERFORMED BY

Kelly Reschny

HOSPITAL NAME

Aldershot Animal Hospital

REFERRING VET

Dr. Wallace

INVOICE

72084

DATE

1/8/26

The visible small intestines are normal in wall thickness and layering. Small intestinal motility appears adequate (1-3 contractions per min). The lumen of the small intestine is mildly distended with very echogenic reverberation artifact from intraluminal gas. There is no evidence of obstruction, foreign material, or infiltrative disease; however, visualization is partially inhibited by gas.

The visible colon is normal in wall thickness (< 0.2 cm) and layering. Contents are consistent with normal formed feces and gas.

Pancreas

The pancreas that is observed appears appropriately isoechoic to surrounding omental fat. Visible capsule is smooth and normal in contour. Visible pancreatic parenchyma is homogenous and unremarkable. There is no visible pancreatic duct dilation. There is no evidence of active peripancreatic inflammation.

Free Abdomen

There is no visible free peritoneal effusion noted in these images.

There is no apparent pathologic lymphadenopathy noted in these images.

PRIMARY FINDINGS

- Hypo to anechoic splenic nodule – likely represents a benign lesion such as a cyst, hematoma, nodular hyperplasia, extramedullary hematopoiesis, etc., however while considered less likely, infiltrative neoplasia can mimic benign lesions, and cannot be ruled out.

SECONDARY FINDINGS

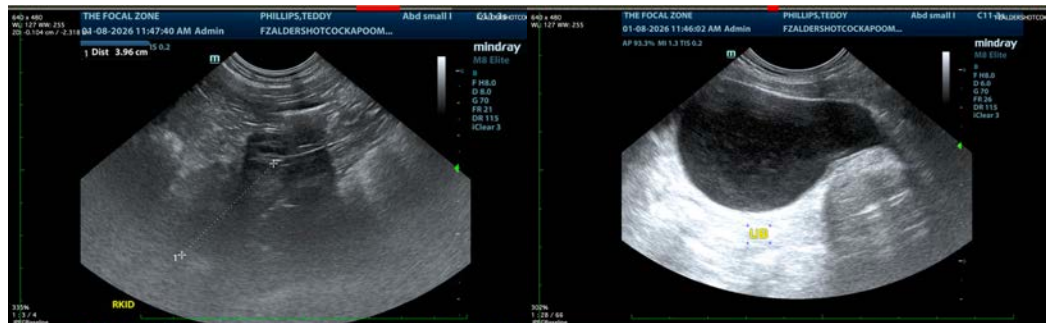
- Age related kidney changes with pinpoint non-obstructive mineral densities noted bilaterally
- Moderate amount of echogenic urinary bladder debris.

INTERPRETATION OF THE FINDINGS & FURTHER RECOMMENDATIONS

The appearance of the splenic nodule is static to previous exams, and there is no definitive ultrasonographically visible evidence of metastatic or progressive disease in these images at this time.

If not recently evaluated, a urinalysis and, if indicated based on urinalysis results, urine culture is recommended. If protein is present in an otherwise quiet sediment, protein quantification with a urine protein to creatinine ratio is recommended.

Otherwise, continued care, monitoring, etc. as is reportedly already in place, is appropriate unless there is a clinical concern or change.





PATIENT

Teddy Phillips

SPECIES

Canine

BREED

Cocker Spaniel x

SEX

Neutered Male

AGE

7 Years

WEIGHT

10.3 kg

INTERPRETED BY

Beth Johnson, DVM
 DACVIM

IMAGING PERFORMED BY

Kelly Reschny

HOSPITAL NAME

Aldershot Animal
 Hospital

REFERRING VET

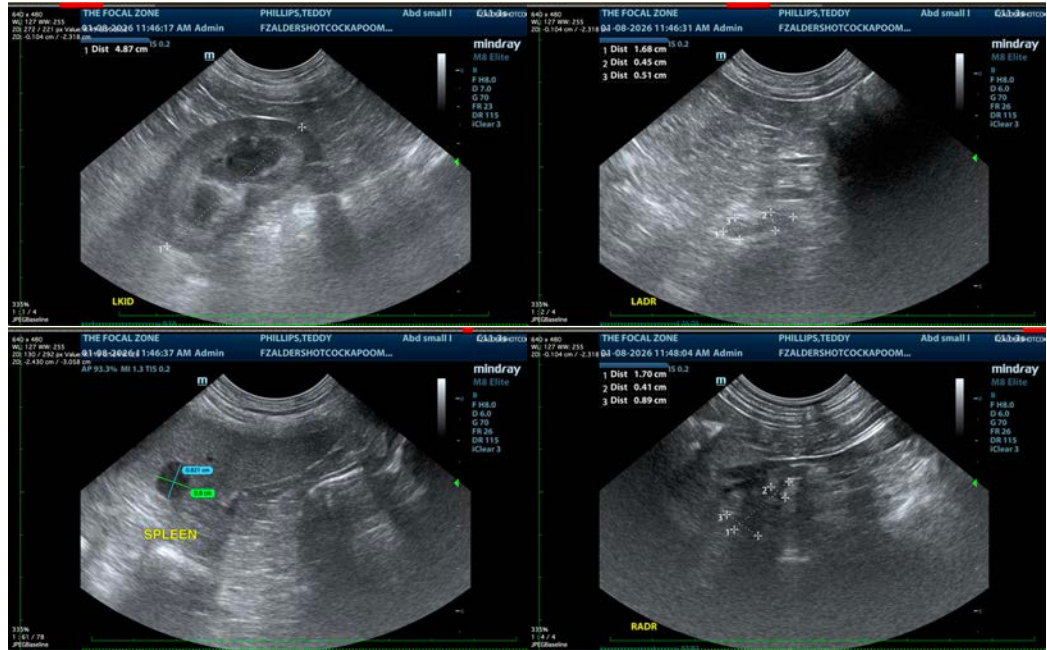
Dr. Wallace

INVOICE

72084

DATE

1/8/26



The information and recommendations provided are based on the images presented by the referring veterinarian/sonographer. No evaluation can be communicated regarding pathology that was not visible in the image/video clips provided.

Thank you for this referral. If the clinical or image interpretation does not parallel your findings or if I can be of any further assistance please contact me.

Beth Johnson, DVM, DACVIM
 info@sonopath.com