



PATIENT

Prince Mulley

SPECIES

Canine

BREED

Bernese Mtn Dog

SEX

Intact Male

AGE

6 Years

WEIGHT

45.6 kg

INTERPRETED BY

Beth Johnson, DVM
 DACVIM

IMAGING PERFORMED BY

Amanda Stewart

HOSPITAL NAME

Big Creek Vet

REFERRING VET

Dr. Wilkinson

INVOICE

72061

DATE

1/8/26

PRESENTING CLINICAL SIGNS

Ongoing UTI since Nov 2025 - still having bloody urine - have done x-rays, urine culture and multiple antibiotics Current Medications none.

Abnormal PE/Chem/CBC/UA Results: See attached SDMA 18.9 (Nov/25) Radiographic Findings NAF Primary Question to Be Answered in This Exam what is going on with u. bladder despite antibiotics

ULTRASONOGRAPHIC EXAMINATION OF THE ABDOMEN

Urinary System

The urinary bladder is adequately distended with anechoic contents. No masses, inflammatory changes, echogenic sediment or cystoliths are observed. The urinary bladder, trigone and visible pelvic urethra are normal in thickness with a smooth mucosal surface.

Prostate is symmetrically enlarged (4.5 cm wide in the sagittal view) with smooth margins that are well differentiated from surrounding tissue. Normal bilobed shape is maintained. Parenchyma is diffusely hyperechoic. Several small anechoic cysts are noted. Several larger sizable anechoic densities are also present. No mineral is noted.

The right kidney is normal is size (7.36 cm), shape and echogenicity. It has smooth peripheral margination. There is a normal 1:3 cortex to medulla ratio with appropriate corticomedullary distinction. There is no evidence of pyelectasia, mineral or infarcts observed.

The left kidney is normal is size (7.76 cm), shape and echogenicity. It has smooth peripheral margination. There is a normal 1:3 cortex to medulla ratio with appropriate corticomedullary distinction. There is no evidence of pyelectasia, mineral or infarcts observed.

Adrenal Glands

The right adrenal gland is unable to be visualized in these images.

The left adrenal gland is normal in size (0.64 cm at cranial pole and 0.64 cm at caudal pole), shape and overall architecture, echogenicity and echotexture. Visible surrounding vasculature appears normal.

Spleen

The spleen is subjectively normal in size with a normal smooth capsular contour. Parenchyma is appropriately finely textured and homogenous with normal echogenicity relative to surrounding tissue (hyperechoic to liver). No focal nodules or masses are observed. Splenic vasculature appears normal.

Liver

The liver is subjectively normal in size with normal smooth curvilinear peripheral contour. Parenchyma is appropriately hypoechoic to the spleen in echogenicity and appropriately mildly coarse and homogenous in echotexture. No focal lesions are observed. Visible vasculature and biliary tree appear normal without distension or congestion.

Gallbladder is moderately distended with anechoic bile as well as suspended and gravity dependent echogenic debris. The wall is smooth without visible thickening. There is no evidence of cystic or CBD dilation. There is no evidence of effusion or inflammation.



PATIENT

Prince Mulley

SPECIES

Canine

BREED

Bernese Mtn Dog

SEX

Intact Male

AGE

6 Years

WEIGHT

45.6 kg

INTERPRETED BY

Beth Johnson, DVM
 DACVIM

IMAGING PERFORMED BY

Amanda Stewart

HOSPITAL NAME

Big Creek Vet

REFERRING VET

Dr. Wilkinson

INVOICE

72061

DATE

1/8/26

Gastrointestinal

The visible stomach wall is normal in thickness and layering. The lumen of the stomach is mildly distended with very echogenic reverberation artifact from intraluminal gas. There is no evidence of obstruction, foreign material, or infiltrative disease; however, visualization is partially inhibited by gas.

The visible small intestines are normal in wall thickness and layering. Small intestinal motility appears adequate (1-3 contractions per min). The lumen is mildly distended with echogenic non-shadowing luminal contents and gas consistent with normal ingesta/chyme. There is no evidence of obstruction, foreign material or infiltrative disease.

The visible colon is normal in wall thickness (< 0.2 cm) and layering. Contents are consistent with normal formed feces and gas.

Pancreas

The pancreas that is observed appears appropriately isoechoic to surrounding omental fat. Visible capsule is smooth and normal in contour. Visible pancreatic parenchyma is homogenous and unremarkable. There is no visible pancreatic duct dilation. There is no evidence of active peripancreatic inflammation.

Free Abdomen

There is no visible free peritoneal effusion noted in these images.

There is no apparent pathologic lymphadenopathy noted in these images.

Both testicles are visualized without evident testicular pathology.

PRIMARY FINDINGS

- Benign Prostatic Hyperplasia with cysts – Prostatic findings are most consistent with Benign Prostatic Hyperplasia (BPH) and concurrent benign prostatic cysts. Active prostatitis cannot be ruled out. Infiltrative neoplasia cannot be ruled out but is considered less likely.

SECONDARY FINDINGS

- Moderate gallbladder debris - Cholecystic debris is of unknown clinical significance. It can be seen with biliary stasis from fasting or illness. Cholecystic debris is not necessarily related to hepatobiliary disease. Echogenic bile is most commonly an incidental finding in dogs and should be interpreted in combination with clinical signs such as nausea, inappetence, cranial abdominal discomfort and/or laboratory changes such as increased ALP and/or increased Tbili.

INTERPRETATION OF THE FINDINGS & FURTHER RECOMMENDATIONS

Given patient's history, my suspicion is that the ongoing hematuria is likely related to prostatic disease, most likely benign prostatic hyperplasia, with, as stated above, prostatitis and/or even much less likely infiltrative neoplasia unable to be definitively ruled out. Therefore, direct sampling of the prostate could be considered via fine needle aspirate if patient's coagulation status is appropriate for cytology, culture and sensitivity, etc. Submission of urine to look for BRAF gene mutation could be considered, but ultimately patient neutering is strongly recommended to prevent ongoing progression of clinical signs.



PATIENT

Prince Mulley

SPECIES

Canine

BREED

Bernese Mtn Dog

SEX

Intact Male

AGE

6 Years

WEIGHT

45.6 kg

INTERPRETED BY

Beth Johnson, DVM
 DACVIM

IMAGING PERFORMED BY

Amanda Stewart

HOSPITAL NAME

Big Creek Vet

REFERRING VET

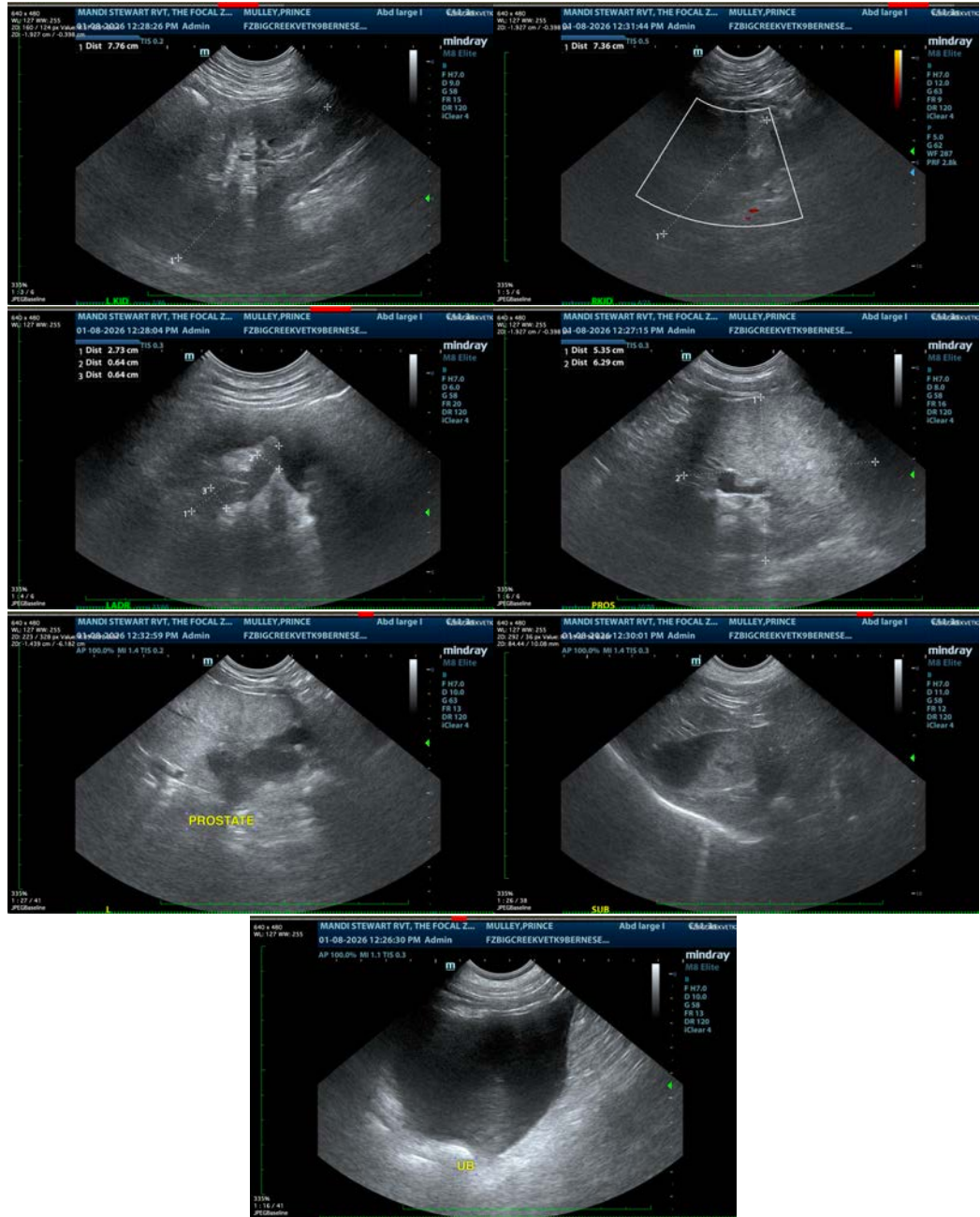
Dr. Wilkinson

INVOICE

72061

DATE

1/8/26



The information and recommendations provided are based on the images presented by the referring veterinarian/sonographer. No evaluation can be communicated regarding pathology that was not visible in the image/video clips provided.

Thank you for this referral. If the clinical or image interpretation does not parallel your findings or if I can be of any further assistance please contact me.

Beth Johnson, DVM, DACVIM info@sonopath.com