



**DATE PRESENTING CLINICAL SIGNS**

1/8/26

**Patient History:** Presenting for lethargy, anorexia, diarrhea and straining to defecate. Stool is loose - brown color, small volume. No c/s/v. Still drinking water. About 1 week ago owner changed food - then he developed diarrhea. Owner transitioned back to previous food. Limited exam due to size, temperament, and patient's unwillingness to stand. But no significant abnormalities aside from obesity, musculoskeletal pain/arthritis, and several skin/staph lesions.

**PATIENT**

Maximus Alisea

**SPECIES**

Canine

**Current Medications:** Initiated treatment with denamarin, augmentin 1500 mg BID, and ondansetron 32 mg BID on the 5th.

**Labwork Results:** Labwork not attached, reported as: ALT 308, ALP 602, GGT 30, BA 32, Tbili 0.8 Neutrophils 17,000, Cre 3.5, Mild elevation TCa 11.8

**BREED**

Cane Corso

**Date of Previous IntraPet Ultrasound:** No previous.

**Sedation:** Not required to complete full diagnostic ultrasound.

**Stat Report:** Declined at this time.

**Imaging Performed by:** Stephanie Warga RDCS, RVT.

**SEX**

Neutered Male

**ULTRASONOGRAPHIC EXAMINATION OF THE ABDOMEN**

**Urinary System**

**AGE**

8/9/17

Urinary bladder is adequately distended. It has a normal uniform wall thickness. Contents include primarily anechoic fluid with occasional echogenic non-shadowing debris, most consistent with exfoliated cells, mucous and/or small blood clots, as well as dependent mineral "sand" (crystals) debris. Both sterile inflammation as well as urinary tract infection can present with echogenic debris. No masses or discrete definitive cystoliths are observed. The trigone and visible pelvic urethra are normal in thickness with a smooth mucosal surface.

**WEIGHT**

200 lbs

**INTERPRETED BY**

Beth Johnson, DVM  
DACVIM

The prostate is unable to be well visualized in these images.

The right kidney is normal is size (8.84 cm), shape and echogenicity. It has smooth peripheral margination. There is a normal 1:3 cortex to medulla ratio with appropriate corticomedullary distinction. There is no evidence of pyelectasia, mineral or infarcts observed.

**HOSPITAL NAME**

Pleasantville Animal  
Hospital of Fallston

The left kidney is normal is size (8.45 cm), shape and echogenicity. It has smooth peripheral margination. There is a normal 1:3 cortex to medulla ratio with appropriate corticomedullary distinction. There is no evidence of pyelectasia, mineral or infarcts observed.

**REFERRING VET**

Dr. Gounaris

**Adrenal Glands**

The right adrenal gland is normal in size (0.69 cm at cranial pole and 0.54 cm at caudal pole), shape and overall architecture, echogenicity and echotexture. Visible surrounding vasculature appears normal.

**INVOICE**

72104

The left adrenal gland is normal in size (0.52 cm at cranial pole and 0.75 cm at caudal pole), shape and overall architecture, echogenicity and echotexture. Visible surrounding vasculature appears normal.

### ***Spleen***

The spleen is subjectively normal in size with a normal smooth capsular contour. Parenchyma is appropriately finely textured and homogenous with normal echogenicity relative to surrounding tissue (hyperechoic to liver). No focal nodules or masses are observed. Splenic vasculature appears normal.

### ***Liver***

Liver is subjectively enlarged with mildly irregular margins. Parenchyma is moderately heterogenous characterized by multiple poorly defined hypoechoic nodules within otherwise hyperechoic liver parenchyma. Visible vasculature and biliary tree appear normal without distension or congestion

The gallbladder is non-distended in size. The wall is smooth without visible thickening. Luminal contents are primarily anechoic. There is no evidence of cystic or common bile duct dilation.

### ***Gastrointestinal***

The visible stomach wall is normal in thickness and layering. The lumen of the stomach is empty with no evidence of obstruction, foreign material or infiltrative disease. Pyloric outflow tract appears patent.

In the mid abdomen/suspect jejunum, there is a 7.2+ cm long loop of small bowel with a markedly thick wall, measuring up to 2.3 cm thick on one side, characterized by a hypoechoic appearance and loss of layering. The remaining visible small intestine demonstrates areas of moderately thick muscularis layer relative to mucosa (disruption of the normal 1:3 muscularis:mucosa ratio). Small intestinal submucosa is slightly irregular, thick and hyperechoic, without evident loss of layering appreciated. The lumen of the small intestine is empty with no evidence of obstruction or foreign material.

The visible colon is normal in wall thickness (< 0.2 cm) and layering. Contents are consistent with normal formed feces and gas.

### ***Pancreas***

The pancreas that is observed appears appropriately isoechoic to surrounding omental fat. Visible capsule is smooth and normal in contour. Visible pancreatic parenchyma is homogenous and unremarkable. There is no visible pancreatic duct dilation. There is no evidence of active peripancreatic inflammation.

### ***Free Abdomen***

There is no visible free peritoneal effusion noted in these images.

Diffusely, lymph nodes are enlarged with swollen irregular capsular contour and loss of normal length to width ratio (rounded in shape). Nodes are hypoechoic with loss of normal parenchymal detail.

### **PRIMARY FINDINGS**

- The focal small bowel mass demonstrates characteristics of malignancy, most concerning for infiltrative neoplasia such as round cell neoplasia i.e., lymphoma, given the concurrent lymphadenopathy, versus carcinoma versus other. A benign inflammatory process is possible but considered less likely. The remaining diffuse changes are more consistent visibly with a benign inflammatory process, but a diffuse round cell neoplasia can't be ruled out.

- Diffusely aggressive lymph nodes – concerning for infiltrative round cell or metastatic neoplasia. A benign aggressive inflammatory response cannot be ruled out without tissue sampling +/- culture.
- Moderately Heterogenous Liver – These changes are most consistent with benign processes such as nodular hyperplasia, steroid (vacuolar) hepatopathy, extramedullary hematopoiesis or possibly chronic inflammatory disease and less commonly infiltrative round cell or metastatic neoplasia.

## SECONDARY FINDINGS

- Mild amount of echogenic urinary bladder mineral/sand debris.

## INTERPRETATION OF THE FINDINGS & FURTHER RECOMMENDATIONS

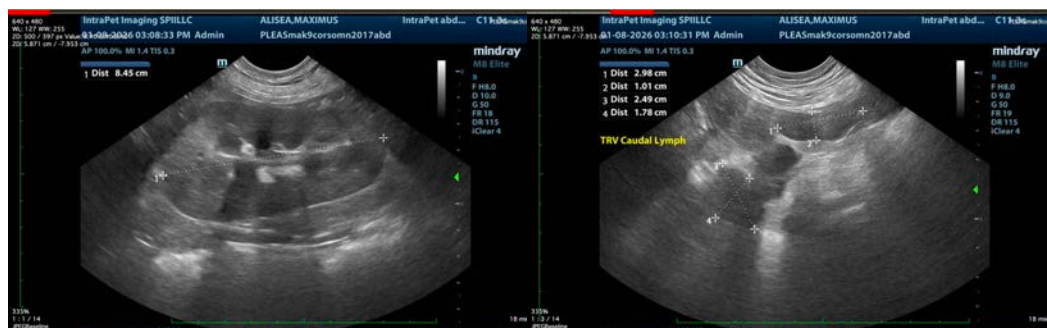
Given patient's reported laboratory changes, a urinalysis and, if indicated based on urinalysis results, urine culture is recommended. If protein is present in an otherwise quiet sediment, protein quantification with a urine protein to creatinine ratio is recommended.

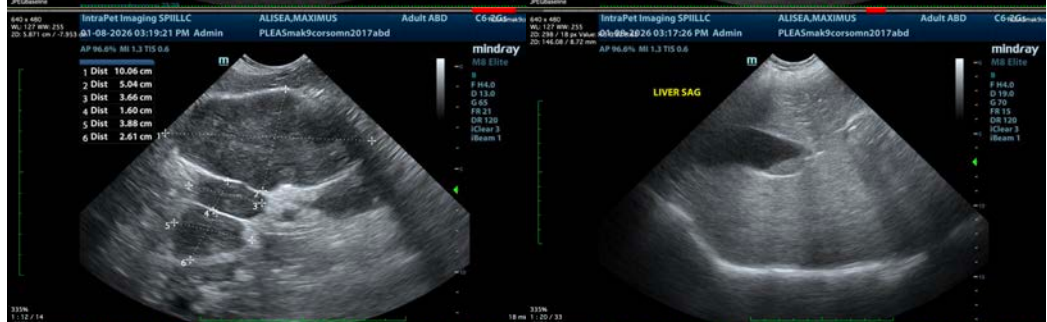
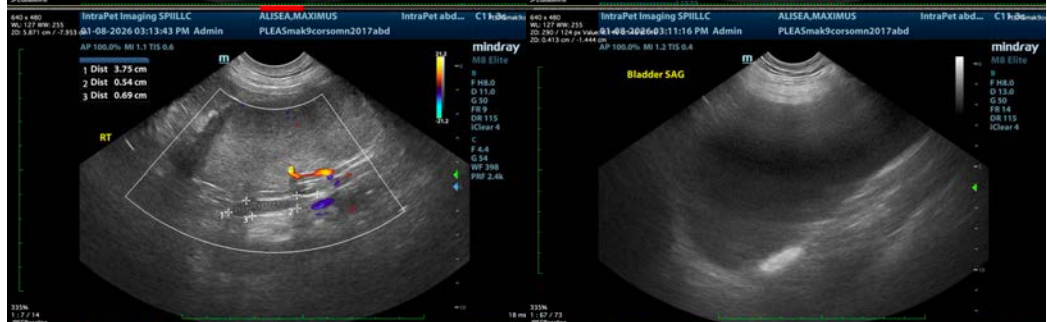
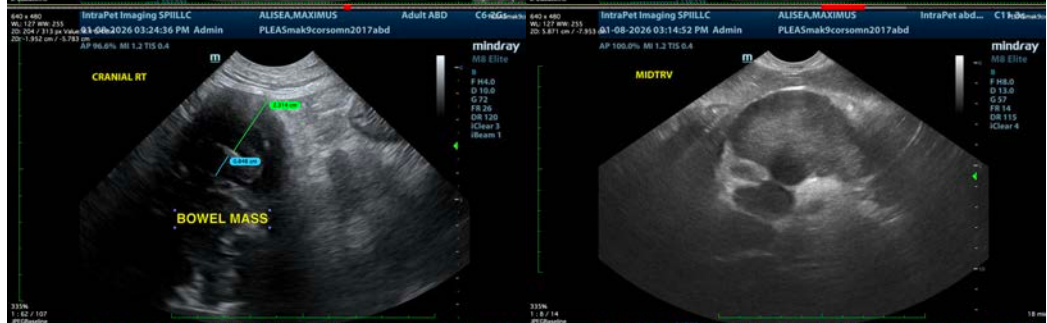
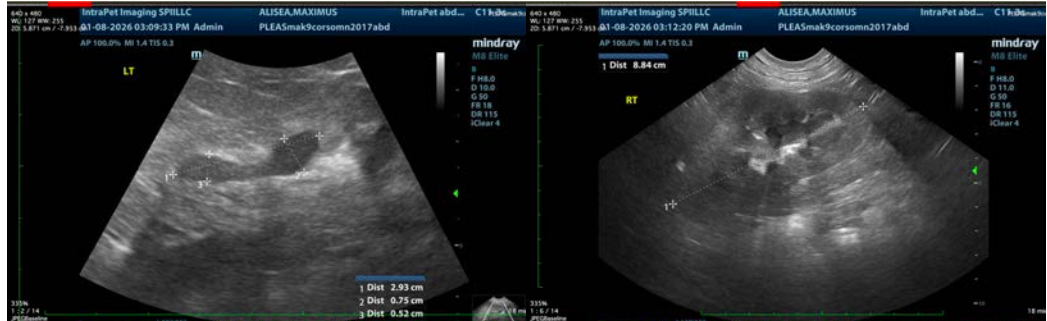
A baseline cortisol is recommended. If baseline cortisol is less than 2, a full ACTH stimulation test is recommended to rule out hypoadrenocorticism.

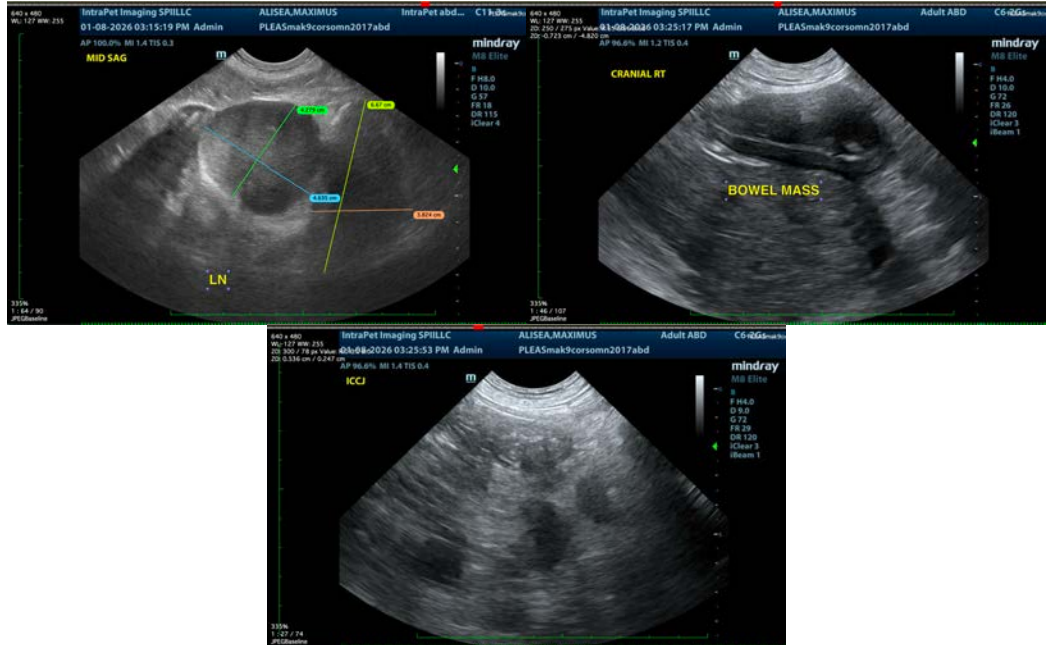
A gastrointestinal malabsorption panel (including cobalamin, folate, TLI and PLI) to Texas A&M GI Laboratory is recommended for further evaluation of GI and pancreatic function.

Ultimately, tissue sampling is recommended to look for evidence of round cell neoplasia. Fine needle aspirates of the lymph nodes, the bowel mass +/- liver could be considered if patient's coagulation status is appropriate.

Other than supportive/symptomatic medical management of clinical signs, further treatment recommendations are largely dependent on results of the above.







The information and recommendations provided are based on the images presented by the referring veterinarian/sonographer. No evaluation can be communicated regarding pathology that was not visible in the image/video clips provided.

Thank you for this referral. If the clinical or image interpretation does not parallel your findings or if I can be of any further assistance please contact me.

**Beth Johnson, DVM, DACVIM**  
info@sonopath.com