



**PATIENT**

Cassanova Brooks

**SPECIES**

Feline

**BREED**

Sphynx

**SEX**

Neutered Male

**AGE**

18 Years

**WEIGHT**

3.2 kg

**INTERPRETED BY**

Beth Johnson, DVM  
 DACVIM

**IMAGING PERFORMED BY**

Kelly Reschny

**HOSPITAL NAME**

Novel Vet Clinic

**REFERRING VET**

Dr. Gibbs

**INVOICE**

72055

**DATE**

1/8/26

**PRESENTING CLINICAL SIGNS**

Urinating blood dx: kidney disease stage 1-2, HCM, coughing fluid occasionally, chronic URI for 3 years, hx of asthma, losing weight. Current Medications gabapentin, solensia, fluids daily.

Abnormal PE/Chem/CBC/UA Results: Labs attached

**ULTRASONOGRAPHIC EXAMINATION OF THE ABDOMEN**

**Urinary System**

The urinary bladder is adequately distended with anechoic contents. No masses, inflammatory changes, echogenic sediment or cystoliths are observed. The urinary bladder, trigone and visible pelvic urethra are normal in thickness with a smooth mucosal surface.

Kidneys are bilaterally irregular and diffusely echogenic with decreased corticomedullary distinction and poor visualization of internal architecture. There is no pyelectasia noted and no mineral is observed. Left kidney is normal in size at 4.25 cm. Right kidney is small-normal at 3.6 cm.

**Adrenal Glands**

The right adrenal gland is normal in size (0.42 cm), shape and overall architecture, echogenicity and echotexture. Visible surrounding vasculature appears normal.

The left adrenal gland is normal in size (0.35 cm), shape and overall architecture, echogenicity and echotexture. Visible surrounding vasculature appears normal.

**Spleen**

The spleen is subjectively normal in size with a normal smooth capsular contour. Parenchyma is appropriately finely textured and homogenous with normal echogenicity relative to surrounding tissue (hyperechoic to liver). No focal nodules or masses are observed. Splenic vasculature appears normal.

**Liver**

The liver is subjectively normal in size with normal smooth curvilinear peripheral contour. Parenchyma is appropriately hypoechoic to the spleen in echogenicity and appropriately mildly coarse and homogenous in echotexture. No focal lesions are observed. Visible vasculature and biliary tree appear normal without distension or congestion.

The gallbladder is non-distended in size. The wall is smooth without visible thickening. Luminal contents are primarily anechoic. There is no evidence of cystic or common bile duct dilation.

**Gastrointestinal**

The visible stomach wall is normal in thickness and layering. The stomach is moderately distended with echogenic non-shadowing luminal contents and gas consistent with normal ingesta. There is no evidence of obstruction, foreign material or infiltrative disease. If patient was appropriately fasted, delayed gastric emptying could be considered. Non-shadowing foreign material is considered less likely but cannot be definitively ruled out.

If clinical signs are consistent (vomiting, etc.), recommendations include supportive medical care, 24 hours fasting and re-image.



**PATIENT**

Cassanova Brooks

**SPECIES**

Feline

**BREED**

Sphynx

**SEX**

Neutered Male

**AGE**

18 Years

**WEIGHT**

3.2 kg

**INTERPRETED BY**

Beth Johnson, DVM  
DACVIM

**IMAGING PERFORMED BY**

Kelly Reschny

**HOSPITAL NAME**

Novel Vet Clinic

**REFERRING VET**

Dr. Gibbs

**INVOICE**

72055

**DATE**

1/8/26

The visible small intestines are normal in wall thickness and layering. Small intestinal motility appears adequate (1-3 contractions per min). The lumen is mildly distended with echogenic non-shadowing luminal contents and gas consistent with normal ingesta/chyme. There is no evidence of obstruction, foreign material or infiltrative disease.

The visible colon is normal in wall thickness (< 0.2 cm) and layering. Contents are consistent with normal formed feces and gas.

**Pancreas**

Pancreas is prominent (enlarged) in size, hypoechoic to surrounding tissue and has a mildly irregular undulating contour. Parenchyma is coarse with mixed echogenic remodeling noted. No pancreatic duct dilation is noted.

**Free Abdomen**

There is no visible free peritoneal effusion noted in these images.

There is no apparent pathologic lymphadenopathy noted in these images.

**ULTRASONOGRAPHIC FINDINGS**

- Chronic kidney disease changes bilaterally, but most visibly significant in the right kidney.
- Chronic low-grade smoldering pancreatitis can't be ruled out and should be suspected in the face of appropriate clinical signs.

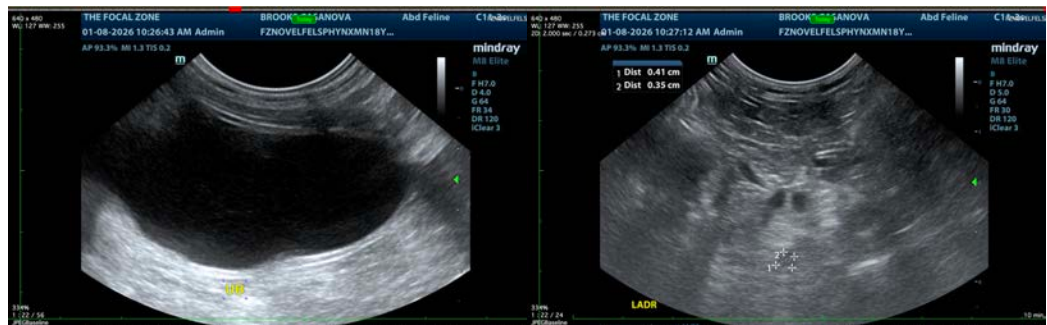
**INTERPRETATION OF THE FINDINGS & FURTHER RECOMMENDATIONS**

Urinalysis and, if indicated based on urinalysis results, urine culture is recommended. If protein is present in an otherwise quiet sediment, protein quantification with a urine protein to creatinine ratio is recommended.

Lab work was not available for review. If not recently evaluated, a full general metabolic health screen is recommended to include CBC, chemistry panel, and electrolytes, as well as coagulation status assessment and T4 +/- free T4.

A blood pressure is recommended if not recently evaluated.

Other than supportive/symptomatic medical management of clinical signs, further diagnostic and treatment recommendations are largely dependent on results of the above.





**PATIENT**

Cassanova Brooks

**SPECIES**

Feline

**BREED**

Sphynx

**SEX**

Neutered Male

**AGE**

18 Years

**WEIGHT**

3.2 kg

**INTERPRETED BY**

Beth Johnson, DVM  
 DACVIM

**IMAGING PERFORMED BY**

Kelly Reschny

**HOSPITAL NAME**

Novel Vet Clinic

**REFERRING VET**

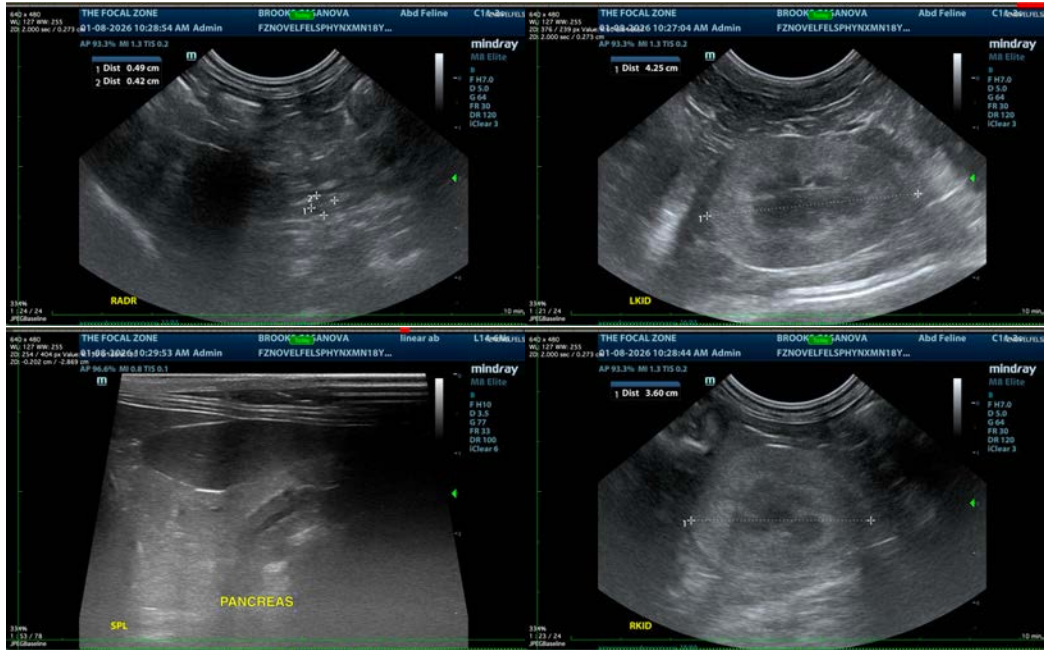
Dr. Gibbs

**INVOICE**

72055

**DATE**

1/8/26



The information and recommendations provided are based on the images presented by the referring veterinarian/sonographer. No evaluation can be communicated regarding pathology that was not visible in the image/video clips provided.

Thank you for this referral. If the clinical or image interpretation does not parallel your findings or if I can be of any further assistance please contact me.

**Beth Johnson, DVM, DACVIM**  
 info@sonopath.com