



PATIENT

Sully Eschuis

SPECIES

Canine

BREED

Golden Retriever/St.
Bernard

SEX

Neutered Male

AGE

5 Years

WEIGHT

32.7 kg

INTERPRETED BY

Beth Johnson, DVM
DACVIM

**IMAGING
PERFORMED BY**

Dr. Kristin Peterson

HOSPITAL NAME

Willvet Salem

REFERRING VET

Dr. Sarah Giambuzzi

INVOICE

20479

DATE

1/8/23

PRESENTING CLINICAL SIGNS

History: Febrile adult neutered male canine with vomiting, anorexia, elevated ALP, Elevated bilirubin, thrombocytopenia and non-regenerative anemia - r/o SPD vs IMHA/ITP vs neoplasia vs tick borne

Abnormal PE/Chem/CBC/UA Results: rDVM labs 1/6/23 CBC - Anemia HCT 25.8%, Thrombocytopenia 29k, Chem - Azotemia CREA 2.0, Hypocalcemia 8.9, Hypocholesterolemia 69, AST 65, ALP 211, TBili 2.5, Hypomagnesaemia 1.4, Hyperkalemia 5.4 - peripheral Lymphadenopathy- all lymph nodes enlarged but soft -Fever 1/7: Wilvet salem Chest radiographs - nsf, not sent out for review CBC - Nonregenerative anemia HCT 24.9%, Thrombocytopenia 12k, rest wnl manual platelet - 0 platelets noted with no clumps Chem17 - Elevated ALP 215, Elevated TBili 2.1, Low Cholesterol 89, rest wnl EPOC - Hypocalcemia iCa 1.09 (artifact Na citrate), Anemia HCT 24%, rest wnl 4DX - negative PT- 17s (wnl) PTT - 95s (wnl) Abdominal US - performed but not yet sent. No abnormalities noted except a small amount of fluid in the stomach and a scant amount of fluid near the tail of the spleen. Will just charge for a AFAST at this point and if we decide to send it can charge for the whole thing. 1/8: EPOC - pH 7.5 (H), Na 135 (L), Cl 99 (L), HCT 19 (L), Platelets - 24K Tbil - 3.0 PCV 22% TS 5g/dl Lepto titer pending

ULTRASONOGRAPHIC EXAMINATION OF THE ABDOMEN

Urinary System

Urinary bladder is adequately distended. It has a normal uniform wall thickness. Contents include primarily anechoic fluid with occasional echogenic non-shadowing debris, most consistent with exfoliated cells, mucous and/or small blood clots. Both sterile inflammation as well as urinary tract infection can also present with echogenic debris. No masses or cystoliths are observed. The trigone and visible pelvic urethra are normal in thickness with a smooth mucosal surface.

The prostate is not well visualized in these images.

Left kidney is normal is size (8.0 cm), shape and echogenicity. It has smooth peripheral margination. There is a normal 1:3 cortex to medulla ratio with appropriate corticomedullary distinction. There is no evidence of pyelectasia, mineral or infarcts observed.

Right kidney is normal is size (7.9 cm), shape and echogenicity. It has smooth peripheral margination. There is a normal 1:3 cortex to medulla ratio with appropriate corticomedullary distinction. There is no evidence of pyelectasia, mineral or infarcts observed.

Adrenal Glands

The adrenal glands are unable to be well visualized in these images.

Spleen

Spleen is subjectively large in size with a mildly swollen but smooth capsule. Parenchyma is normal and homogenous in echogenicity and echotexture. No focal nodules or masses are observed. Splenic vasculature appears normal.

Liver

Liver is subjectively enlarged (swollen contour) without disruption of architecture. It has a normal homogenous echotexture. Parenchyma is diffusely hyperechoic characterized by less prominent than normal portal vein walls and increased echogenicity relative to the spleen and falciform fat. No focal



PATIENT

lesions are observed. Visible vasculature and biliary tree appear normal without distension or congestion.

Sully Eschuis

Gallbladder is non-distended in size. The wall is smooth without visible thickening. Luminal contents are primarily anechoic. There is no evidence of cystic or common bile duct dilation.

SPECIES

Gastrointestinal

Canine

The visible stomach wall is normal in thickness and layering. The lumen of the stomach is mildly fluid distended.

BREED

The visible small intestines are normal in wall thickness and layering. Small intestinal motility appears adequate (1-3 contractions per min). The lumen of the small intestine is empty with no evidence of obstruction, foreign material or infiltrative disease.

Golden Retriever/St.
Bernard

SEX

The visible colon is normal in wall thickness and layering. Contents are consistent with normal formed feces and gas.

Neutered Male

Pancreas

AGE

The observed pancreas appears appropriately isoechoic to surrounding omental fat. Visible capsule is smooth and normal in contour. Visible pancreatic parenchyma is homogenous and unremarkable. There is no visible pancreatic duct dilation. There is no evidence of active peripancreatic inflammation.

5 Years

WEIGHT

Free Abdomen

32.7 kg

There is a scant amount of anechoic free fluid around the tail of the spleen, as well as mild mesenteric lymphadenopathy noted.

INTERPRETED BY

ULTRASONOGRAPHIC FINDINGS

Beth Johnson, DVM
DACVIM

Primary Findings

- Hypersplenism – can be associated with congestion caused by sedation (if sedated) but can also be associated with diffuse infiltrative disease. Both benign conditions such as extramedullary hematopoiesis, lymphoid hyperplasia, as well as infiltrative neoplastic diseases such as round cell neoplasia should be considered.
- Mesenteric lymphadenopathy, both reactive lymphadenopathy, as well as infiltrative neoplasia are differentials and cannot be differentiated without tissue sampling.

IMAGING PERFORMED BY

Dr. Kristin Peterson

HOSPITAL NAME

Willvet Salem

Secondary Findings

- Urinary bladder debris

REFERRING VET

INTERPRETATION OF THE FINDINGS & FURTHER RECOMMENDATIONS

Dr. Sarah Giambuzzi

Given this patients reported laboratory changes, top differential is immune mediated hemolytic anemia/thrombocytopenia/Evans syndrome of unknown underlying cause, if not idiopathic. The pathology described above are all nonspecific changes that could be benign, reactive, EMH, etc., but infiltrative neoplasia, such as lymphoma is also a differential that could affect all of the organs described, as well as the peripheral lymph nodes, and should be ruled out. Given the concurrent azotemia, if not already evaluated, to help determine prerenal vs renal azotemia, urinalysis and, if indicated based on urinalysis results, urine culture is recommended. If protein is present in an

INVOICE

20479

DATE

1/8/23



PATIENT

otherwise quiet sediment, protein quantification with a urine protein to creatinine ration is recommended.

Sully Eschuis

Especially, if azotemia is renal, as is reportedly already pending, testing for Leptospirosis is warranted, in addition to other comprehensive, especially vector borne infectious disease, testing.

SPECIES

Canine

Ideally, fine needle aspirates of the spleen +/- liver and lymph nodes, beginning with the reportedly enlarged peripheral lymph nodes, as a less invasive option, would be obtained if and when patients coagulation status is appropriate to do so.

BREED

Golden Retriever/St. Bernard

In the meantime, potentially safer cytologic sampling could be obtained via bone marrow cytology.

SEX

Finally, given the azotemia, electrolyte abnormalities, etc., if possible, prior to starting steroid, a baseline cortisol is recommended. If baseline cortisol is less than 2, a full ACTH stimulation test is recommended to rule out hypoadrenocorticism.

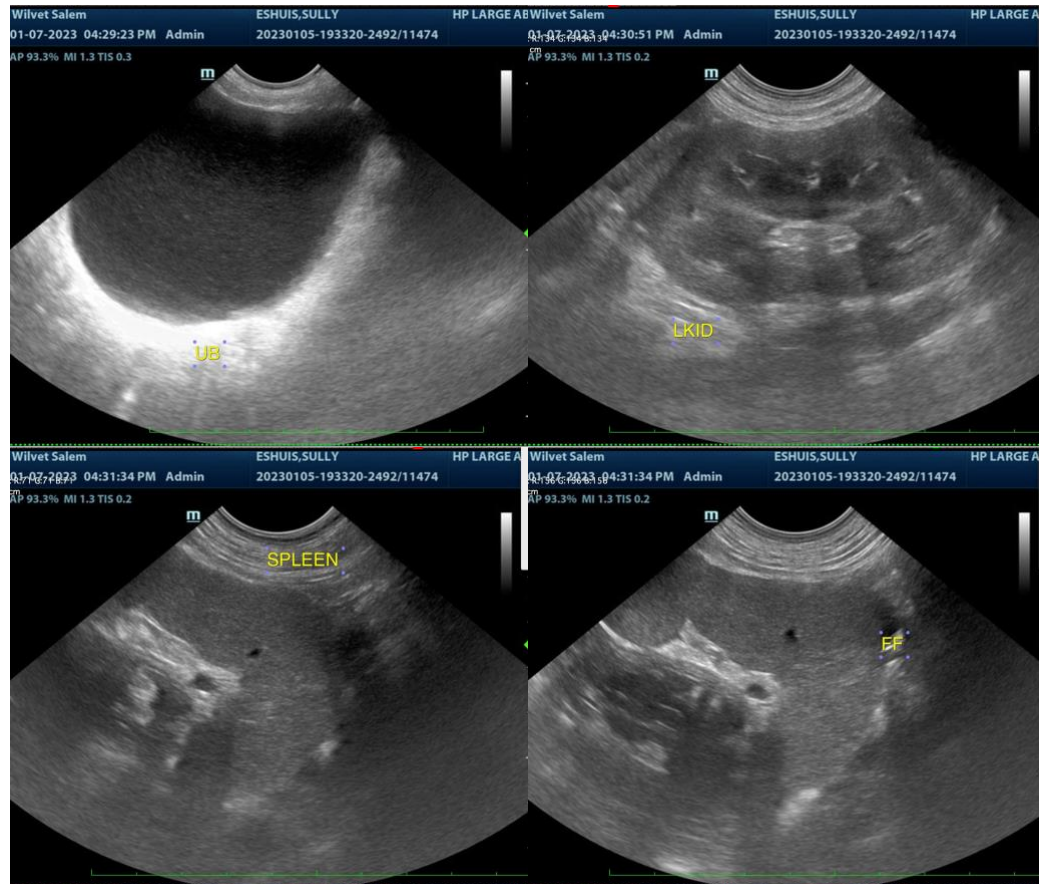
Neutered Male

AGE

5 Years

WEIGHT

32.7 kg



INTERPRETED BY

Beth Johnson, DVM
DACVIM

IMAGING PERFORMED BY

Dr. Kristin Peterson

HOSPITAL NAME

Willvet Salem

REFERRING VET

Dr. Sarah Giambuzzi

INVOICE

20479

DATE

1/8/23



PATIENT

Sully Eschuis

SPECIES

Canine

BREED

Golden Retriever/St. Bernard

SEX

Neutered Male

AGE

5 Years

WEIGHT

32.7 kg

INTERPRETED BY

Beth Johnson, DVM
DACVIM

IMAGING PERFORMED BY

Dr. Kristin Peterson

HOSPITAL NAME

Willvet Salem

REFERRING VET

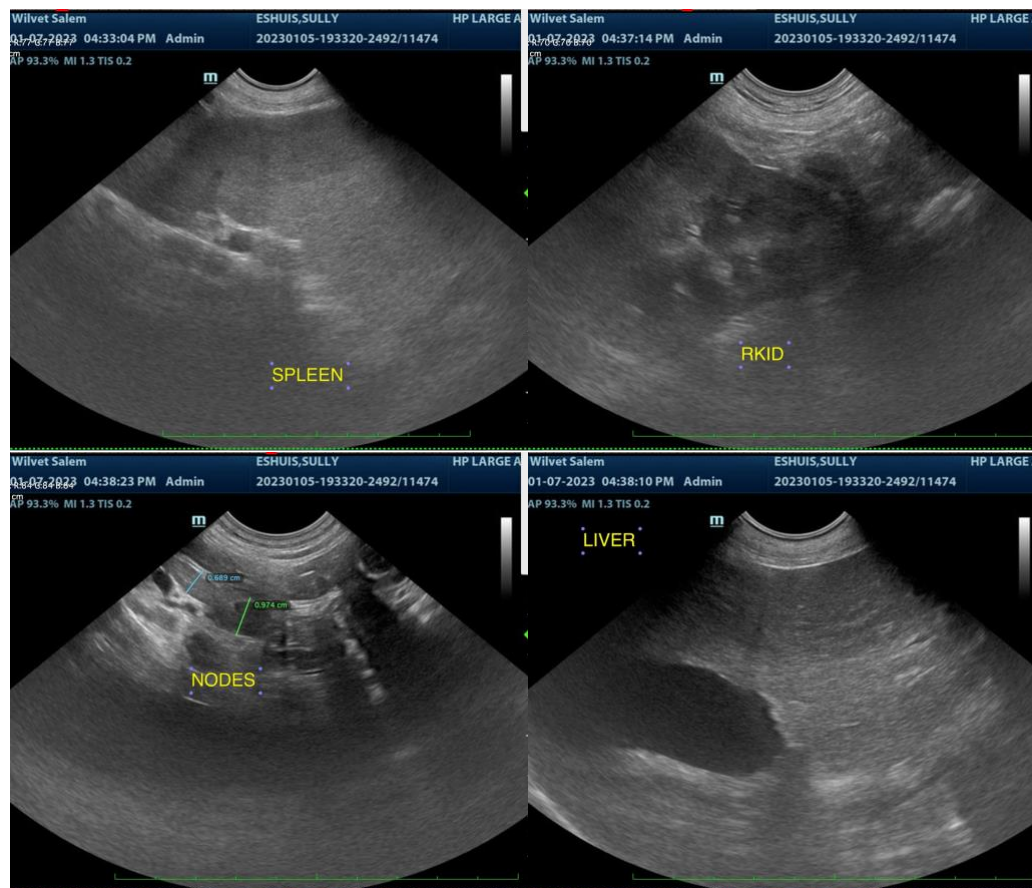
Dr. Sarah Giambuzzi

INVOICE

20479

DATE

1/8/23



The information and recommendations provided are based on the images presented by the referring veterinarian. No evaluation can be communicated regarding pathology that was not visible in the image/video clips provided.

Thank you for this referral. If the clinical or image interpretation does not parallel your findings or if I can be of any further assistance please contact me.

Beth Johnson, DVM DACVIM

Beth.Johnson@SonoPath.com