



PATIENT

Stout Purcell

SPECIES

Canine

BREED

Catahoula Leopard Dog

SEX

MN

AGE

11 years

WEIGHT

78.5 lbs

INTERPRETED BY

Beth Johnson, DVM
DACVIM

IMAGING PERFORMED BY

Pamela Harrigan, RDCS,
Certified Veterinary
Sonographer

HOSPITAL NAME

Falmouth Animal
Hospital

REFERRING VET

Dr. Alyssa Sakmar

INVOICE

11065

DATE

1/7/2026

PRESENTING CLINICAL SIGNS

Elevated liver enzymes noted on routine senior lab work. SDMA 17, Alb 2.5 Glob 4.6, ALT 398, AST 66, ALP 250, Total Bili 0.7. *Sedated with dexdomitor for study.

ULTRASONOGRAPHIC EXAMINATION OF THE ABDOMEN

Urinary System

The urinary bladder is adequately distended with anechoic contents. No masses, inflammatory changes, echogenic sediment or cystoliths are observed. The urinary bladder, trigone and visible pelvic urethra are normal in thickness with a smooth mucosal surface.

Prostate is normal in size, echotexture, and echogenicity for a neutered male.

The right kidney is normal in size (7.09 cm), shape and echogenicity. It has smooth peripheral margination. There is a normal 1:3 cortex to medulla ratio with appropriate corticomedullary distinction. There is no evidence of pyelectasia, mineral or infarcts observed.

The left kidney is normal in size (6.54 cm), shape and echogenicity. It has smooth peripheral margination. There is a normal 1:3 cortex to medulla ratio with appropriate corticomedullary distinction. There is no evidence of pyelectasia, mineral or infarcts observed.

Adrenal Glands

The right adrenal gland is normal in size (0.47 cm at cranial pole and 0.53 cm at caudal pole), shape and overall architecture, echogenicity and echotexture. Visible surrounding vasculature appears normal.

The left adrenal gland is normal in size (0.8 cm at cranial pole and 0.68 cm at caudal pole), shape and overall architecture, echogenicity and echotexture. Visible surrounding vasculature appears normal.

Spleen

The spleen is subjectively normal in size with a normal smooth capsular contour. Parenchyma is appropriately finely textured and homogenous with normal echogenicity relative to surrounding tissue (hyperechoic to liver). No focal nodules or masses are observed. Splenic vasculature appears normal.

Liver

Liver is subjectively enlarged with mildly irregular margins. Parenchyma is moderately heterogenous characterized by multiple poorly defined hypoechoic nodules within otherwise hyperechoic liver parenchyma. Visible vasculature and biliary tree appear normal without distension or congestion.

The gallbladder is non-distended in size. The wall is smooth without visible thickening. Luminal contents are primarily anechoic. There is no evidence of cystic or common bile duct dilation.

Gastrointestinal

The visible stomach wall is normal in thickness and layering. The lumen of the stomach is empty with no evidence of obstruction, foreign material or infiltrative disease. Pyloric outflow tract appears patent.

The visible small intestine demonstrates areas of moderately thick muscularis layer relative to mucosa (disruption of the normal 1:3 muscularis:mucosa ratio). Small intestinal submucosa is slightly irregular,



PATIENT

Stout Purcell

thick and hyperechoic, without evident loss of layering appreciated. The lumen of the small intestine is empty with no evidence of obstruction or foreign material.

SPECIES

Canine

The visible colon is normal in wall thickness (< 0.2 cm) and layering. Contents are consistent with normal formed feces and gas.

BREED

Catahoula Leopard Dog

Pancreas

The pancreas that is observed appears appropriately isoechoic to surrounding omental fat. Visible capsule is smooth and normal in contour. Visible pancreatic parenchyma is homogenous and unremarkable. There is no visible pancreatic duct dilation. There is no evidence of active peripancreatic inflammation.

SEX

MN

Free Abdomen

There is no visible free peritoneal effusion noted in these images.

AGE

11 years

Medial iliac lymph nodes are prominent in size with swollen capsular contour. Normal elongated shape (length to width ratio) is maintained. There is no loss of parenchymal detail.

WEIGHT

78.5 lbs

ULTRASONOGRAPHIC FINDINGS

- Moderate inflammatory bowel disease (IBD) pattern – Thick muscularis has been reported with infiltrative bowel disease including both benign inflammatory disease as well as infiltrative neoplasia such as lymphoma. No loss of layering or distinct characteristics of malignancy are present. Therefore, differentials cannot be further ranked without tissue sampling.
- Mildly reactive medial iliac lymph nodes – infiltrative neoplastic disease cannot be ruled out but is considered less likely.
- An obvious cause for the moderate liver changes is not identified in these images. Microscopic disease such as Leptospirosis, bacterial cholangiohepatitis, chronic active hepatitis, copper-associated hepatotoxicity, other hepatotoxicity, other reactive hepatopathy, infiltrative neoplasia (considered unlikely), etc. cannot be definitively ruled out.

INTERPRETED BY

Beth Johnson, DVM
DACVIM

INTERPRETATION OF THE FINDINGS & FURTHER RECOMMENDATIONS

Given patient's reportedly increased ALT, bile acids could be considered if patient's total bilirubin is not increased.

IMAGING PERFORMED BY

Pamela Harrigan, RDCS,
Certified Veterinary
Sonographer

Testing for leptospirosis could be considered.

HOSPITAL NAME

Falmouth Animal Hospital

Fine needle aspirate of the liver could be evaluated to assess inflammatory cell type ruling out round cell neoplasia, etc., if patient's coagulation status is appropriate, or if a diagnosis is not obtained, ultimately, a liver biopsy including copper level assessment may be required for a definitive diagnosis of any present underlying hepatopathy. If pursued, given the bowel changes, biopsies of the GI tract would be recommended at the same time.

REFERRING VET

Dr. Alyssa Sakmar

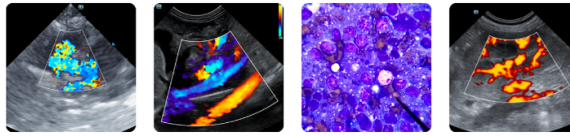
INVOICE

11065

DATE

1/7/2026

In the meantime, a routine fecal/giardia exam is recommended if not recently evaluated, as is a gastrointestinal malabsorption panel (including cobalamin, folate, TLI and PLI) to Texas A&M GI Laboratory is recommended for further evaluation of GI and pancreatic function.



PATIENT

Stout Purcell

A fecal enteropathogen PCR panel to Texas A&M GI Laboratory could be considered for further evaluation of possible infectious disease. Contact lab for recommendations on how long to discontinue antibiotics (if indicated) prior to obtaining a stool sample for submission.

SPECIES

Canine

BREED

Catahoula Leopard
Dog

SEX

MN

AGE

11 years

WEIGHT

78.5 lbs

INTERPRETED BY

Beth Johnson, DVM
DACVIM

**IMAGING
PERFORMED BY**

Pamela Harrigan, RDCS,
Certified Veterinary
Sonographer

HOSPITAL NAME

Falmouth Animal
Hospital

REFERRING VET

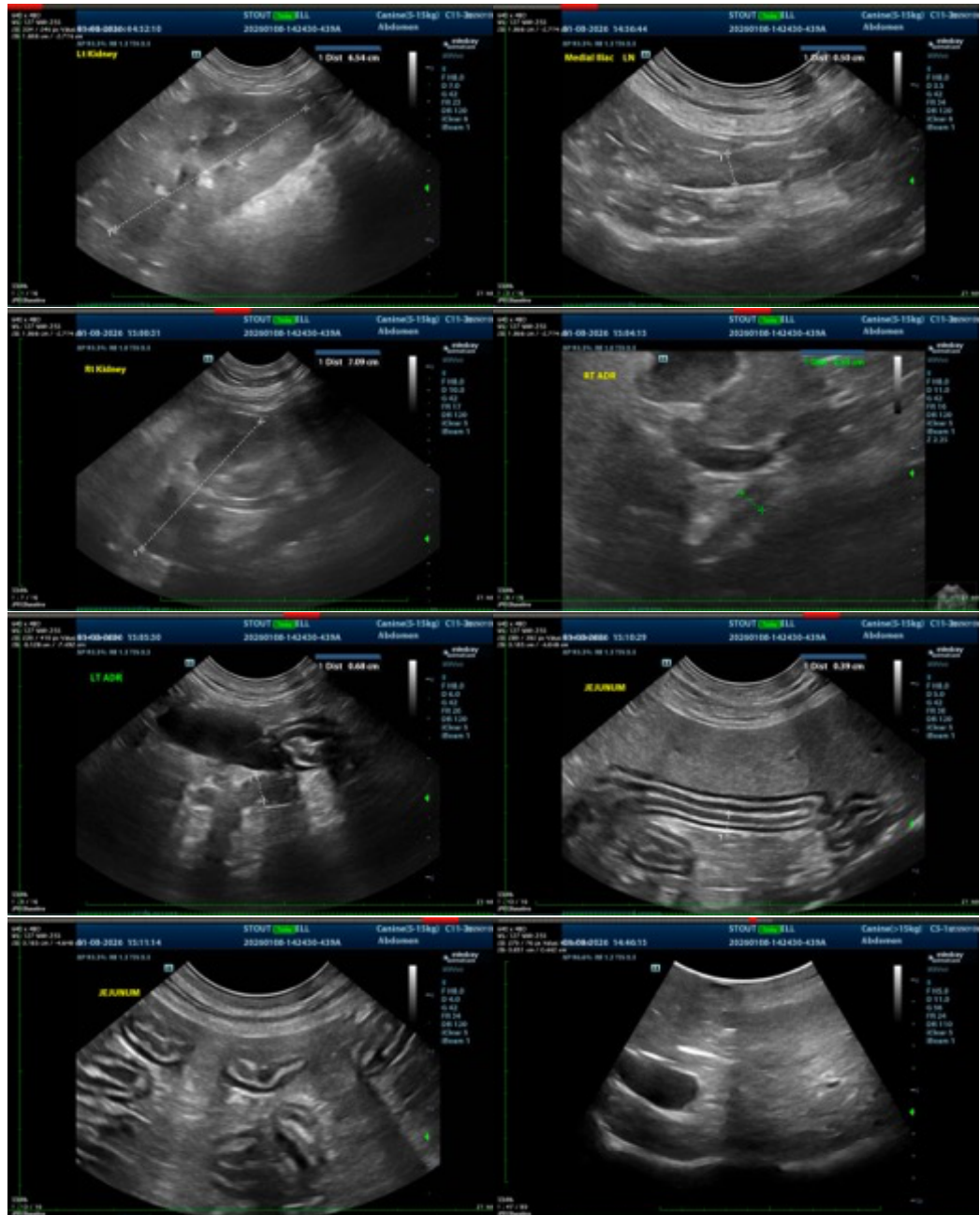
Dr. Alyssa Sakmar

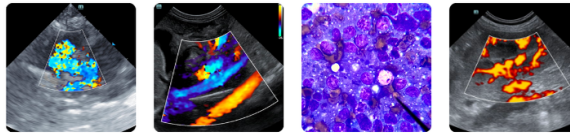
INVOICE

11065

DATE

1/7/2026





PATIENT

Stout Purcell

SPECIES

Canine

BREED

Catahoula Leopard
Dog

SEX

MN

AGE

11 years

WEIGHT

78.5 lbs

INTERPRETED BY

Beth Johnson, DVM
DACVIM

**IMAGING
PERFORMED BY**

Pamela Harrigan, RDCS,
Certified Veterinary
Sonographer

HOSPITAL NAME

Falmouth Animal
Hospital

REFERRING VET

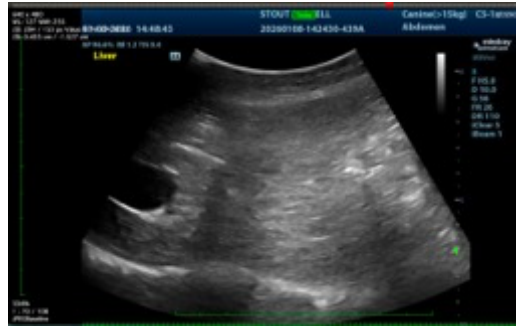Dr. Alyssa Sakmar

INVOICE

11065

DATE

1/7/2026



The information and recommendations provided are based on the images presented by the referring veterinarian/sonographer. No evaluation can be communicated regarding pathology that was not visible in the image/video clips provided.

Thank you for this referral. If the clinical or image interpretation does not parallel your findings or if I can be of any further assistance please contact me.

Beth Johnson, DVM, DACVIM
info@sonopath.com