



**PATIENT**

Stitch Heppler

**SPECIES**

Canine

**BREED**

Aussie x

**SEX**

Neutered Male

**AGE**

11 Years

**WEIGHT**

31.4 kg

**INTERPRETED BY**

Beth Johnson, DVM  
 DACVIM

**IMAGING PERFORMED BY**

Amanda Stewart

**HOSPITAL NAME**

Buck Animal Hospital

**REFERRING VET**

Dr. Galbraith

**INVOICE**

72011

**DATE**

1/7/26

**PRESENTING CLINICAL SIGNS**

Findings: - polydipsia - weight loss - loss of appetite since loss of old dog - non-regenerative anemia - intermittent soft stools.

Abnormal PE/Chem/CBC/UA Results: See attached

**ULTRASONOGRAPHIC EXAMINATION OF THE ABDOMEN**

**Urinary System**

The urinary bladder is adequately distended with anechoic contents. No masses, inflammatory changes, echogenic sediment or cystoliths are observed. The urinary bladder, trigone and visible pelvic urethra are normal in thickness with a smooth mucosal surface.

The area of the prostate is examined without evident prostatic pathology.

The right kidney is normal in size (6.42 cm), shape and echogenicity. It has smooth peripheral margination. There is a normal 1:3 cortex to medulla ratio with appropriate corticomedullary distinction. There is no evidence of pyelectasia, mineral or infarcts observed.

The left kidney is normal in size (6.94 cm), shape and echogenicity. It has smooth peripheral margination. There is a normal 1:3 cortex to medulla ratio with appropriate corticomedullary distinction. There is no evidence of pyelectasia, mineral or infarcts observed.

**Adrenal Glands**

The caudal pole of the right adrenal gland is normal in size (0.70 cm), shape and overall architecture, echogenicity and echotexture. The cranial pole is unable to be well visualized in these images. Visible surrounding vasculature appears normal.

The left adrenal gland is small (flattened contour), measuring 0.52 cm at the cranial pole and 0.52 cm at the caudal pole. Corticomedullary structure is unremarkable. Visible surrounding vasculature appears normal.

**Spleen**

Spleen is subjectively large in size with normal smooth margins. Parenchyma is normal in echogenicity with a diffusely coarse/heterogenous echotexture. No discrete sizable focal nodules or masses are observed. Splenic vasculature appears normal.

**Liver**

Liver is subjectively enlarged with mildly irregular margins. Parenchyma is moderately heterogenous characterized by multiple poorly defined hypoechoic nodules within otherwise hyperechoic liver parenchyma. Visible vasculature and biliary tree appear normal without distension or congestion

Gallbladder is moderately distended with anechoic bile as well as suspended and gravity dependent echogenic debris. The wall of the gallbladder appears as a thin hyperechoic/calcified rim casting a distinct distal acoustic shadow. There is no evidence of cystic or CBD dilation. There is no evidence of effusion or inflammation.



**PATIENT**

Stitch Heppler

**SPECIES**

Canine

**BREED**

Aussie x

**SEX**

Neutered Male

**AGE**

11 Years

**WEIGHT**

31.4 kg

**INTERPRETED BY**

Beth Johnson, DVM  
 DACVIM

**IMAGING PERFORMED BY**

Amanda Stewart

**HOSPITAL NAME**

Buck Animal Hospital

**REFERRING VET**

Dr. Galbraith

**INVOICE**

72011

**DATE**

1/7/26

**Gastrointestinal**

The visible stomach wall is normal in thickness and layering. The lumen of the stomach is empty with no evidence of obstruction, foreign material or infiltrative disease. Pyloric outflow tract appears patent.

The visible small intestines are normal in wall thickness and layering. Small intestinal motility appears adequate (1-3 contractions per min). The lumen of the small intestine is contains fluid.

The visible colon is normal in wall thickness (< 0.2 cm) and layering. Contents are consistent with normal formed feces and gas.

**Pancreas**

The pancreas that is observed appears appropriately isoechoic to surrounding omental fat. Visible capsule is smooth and normal in contour. Visible pancreatic parenchyma is homogenous and unremarkable. There is no visible pancreatic duct dilation. There is no evidence of active peripancreatic inflammation.

**Free Abdomen**

There is a small amount of free fluid primarily in the cranial abdomen, adjacent to the spleen and liver.

There is no apparent pathologic lymphadenopathy noted in these images.

**ULTRASONOGRAPHIC FINDINGS**

- Coarse splenomegaly – can be associated with congestion caused by sedation (if sedated) but can also be associated with diffuse infiltrative disease. Both benign conditions such as extramedullary hematopoiesis, lymphoid hyperplasia, as well as infiltrative neoplastic diseases such as round cell neoplasia should be considered.
- Moderately Heterogenous Liver – These changes are most consistent with benign processes such as nodular hyperplasia, steroid (vacuolar) hepatopathy, extramedullary hematopoiesis or possibly chronic inflammatory disease and less commonly infiltrative round cell or metastatic neoplasia.
- Moderate gallbladder debris - Cholecystic debris is of unknown clinical significance. It can be seen with biliary stasis from fasting or illness. Cholecystic debris is not necessarily related to hepatobiliary disease. Echogenic bile is most commonly an incidental finding in dogs and should be interpreted in combination with clinical signs such as nausea, inappetence, cranial abdominal discomfort and/or laboratory changes such as increased ALP and/or increased Tbili.
- Porcelain gallbladder – Porcelain (calcified) gallbladder is an uncommon finding in companion animals and has been observed as both an incidental finding and associated with biliary neoplasia. In humans, porcelain gallbladder can be a manifestation of chronic gallbladder disease, chronic cholecystitis, intramural hemorrhage with subsequent calcification, imbalances in calcium metabolism, and even giardiasis. This finding should be interpreted in combination with any clinical signs and/or laboratory changes suggestive of biliary disease and/or calcium dysregulation, etc.



**PATIENT**

Stitch Hepler

**SPECIES**

Canine

**BREED**

Aussie x

**SEX**

Neutered Male

**AGE**

11 Years

**WEIGHT**

31.4 kg

**INTERPRETED BY**

Beth Johnson, DVM  
 DACVIM

**IMAGING PERFORMED BY**

Amanda Stewart

**HOSPITAL NAME**

Buck Animal Hospital

**REFERRING VET**

Dr. Galbraith

**INVOICE**

72011

**DATE**

1/7/26

- Flat left adrenal gland – This can be a normal patient variant and/or a sign of exogenous cortisol administration. If exogenous steroids are not being administered, hypoadrenocorticism (either relative or absolute) should be considered.
- The small amount of free fluid is of unknown origin. Differentials (unless already ruled out) could include increased hydrostatic pressure (cardiac disease and/or vascular or lymph blockage), decreased oncotic pressure (low albumin), vasculitis, paraneoplastic fluid, rupture/leakage of/from an organ (GI, GB, UB, other), blood (hemoabdomen), other.

**INTERPRETATION OF THE FINDINGS & FURTHER RECOMMENDATIONS**

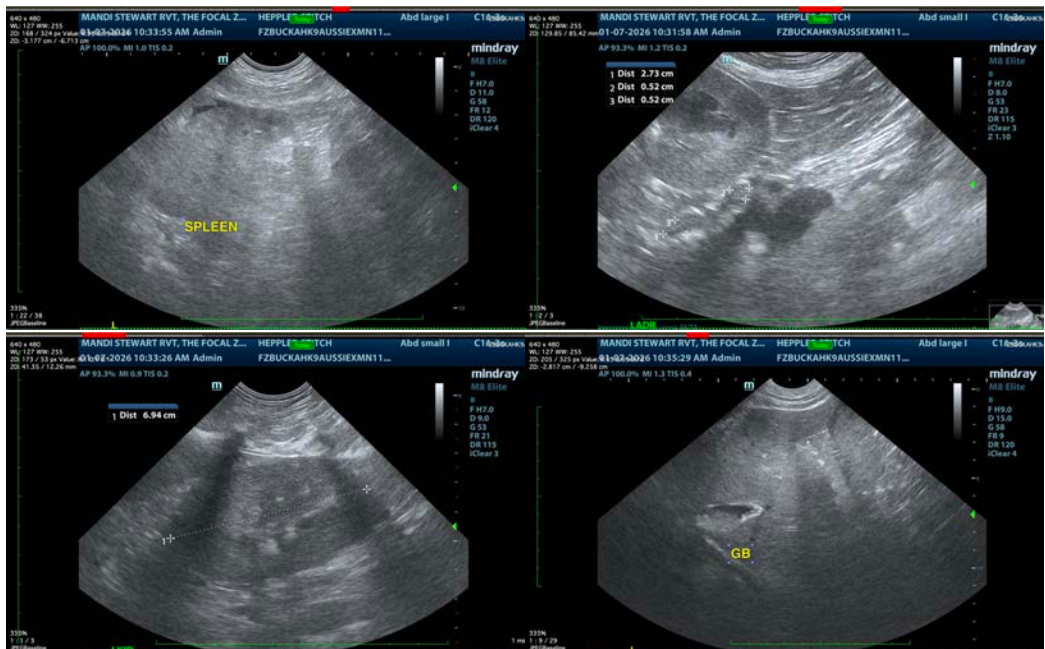Given patient's history, if not recently evaluated, a urinalysis and, if indicated based on urinalysis results, urine culture is recommended. If protein is present in an otherwise quiet sediment, protein quantification with a urine protein to creatinine ratio is recommended.

A baseline cortisol is recommended. If baseline cortisol is less than 2, a full ACTH stimulation test is recommended to rule out hypoadrenocorticism.

Three view thoracic radiographs are recommended for further assessment of cardio-pulmonary status as well as to further evaluate for any evidence of metastatic disease, if not recently evaluated.

Fine needle aspirates of the spleen +/- liver are recommended if patient's coagulation status is appropriate.

Additionally, or pending results of above, a routine fecal/giardia exam is recommended, as is possibly a gastrointestinal malabsorption panel (including cobalamin, folate, TLI and PLI) to Texas A&M GI Laboratory for further evaluation of GI and pancreatic function +/- a fecal enteropathogen PCR panel to Texas A&M GI Laboratory for further evaluation of possible infectious disease. Contact lab for recommendations on how long to discontinue antibiotics (if indicated) prior to obtaining a stool sample for submission.





**PATIENT**

Stitch Hepler

**SPECIES**

Canine

**BREED**

Aussie x

**SEX**

Neutered Male

**AGE**

11 Years

**WEIGHT**

31.4 kg

**INTERPRETED BY**

Beth Johnson, DVM  
 DACVIM

**IMAGING PERFORMED BY**

Amanda Stewart

**HOSPITAL NAME**

Buck Animal Hospital

**REFERRING VET**

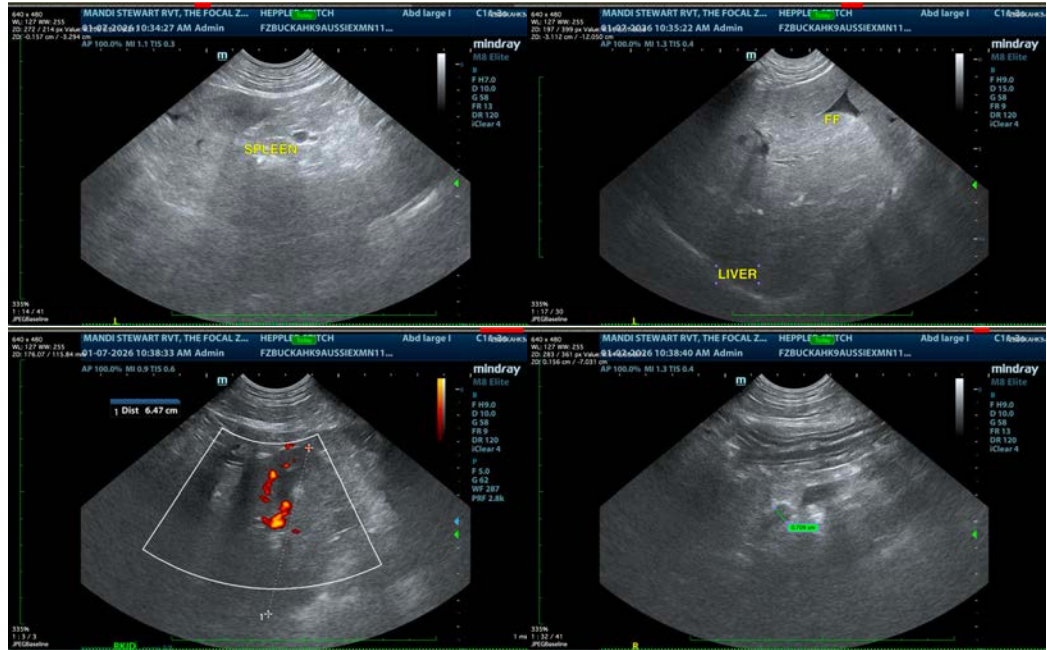
Dr. Galbraith

**INVOICE**

72011

**DATE**

1/7/26



The information and recommendations provided are based on the images presented by the referring veterinarian/sonographer. No evaluation can be communicated regarding pathology that was not visible in the image/video clips provided.

Thank you for this referral. If the clinical or image interpretation does not parallel your findings or if I can be of any further assistance please contact me.

**Beth Johnson, DVM, DACVIM**  
 info@sonopath.com