



PATIENT

Ruby Lysinger

SPECIES

Feline

BREED

DSH

SEX

Spayed Female

AGE

12 Years 1 Months

WEIGHT

9.6 lbs

INTERPRETED BY

Beth Johnson, DVM
DACVIM

IMAGING PERFORMED BY

Kathleen Byrnes

HOSPITAL NAME

Pet Care Clinic of the
High Country

REFERRING VET

Dr. Sturgill

INVOICE

72028

DATE

1/7/26

PRESENTING CLINICAL SIGNS

P presented for US due to loose stools and weight loss.

ULTRASONOGRAPHIC EXAMINATION OF THE ABDOMEN

Urinary System

The urinary bladder is adequately distended with anechoic contents. No masses, inflammatory changes, echogenic sediment or cystoliths are observed. The urinary bladder, trigone and visible pelvic urethra are normal in thickness with a smooth mucosal surface.

The right kidney is normal is size (4.0 cm), shape and echogenicity. It has smooth peripheral margination. There is a normal 1:3 cortex to medulla ratio with appropriate corticomedullary distinction. There is no evidence of pyelectasia, mineral or infarcts observed.

The left kidney is normal is size (3.78 cm), shape and echogenicity. It has smooth peripheral margination. There is a normal 1:3 cortex to medulla ratio with appropriate corticomedullary distinction. There is no evidence of pyelectasia, mineral or infarcts observed.

Adrenal Glands

The right adrenal gland is normal in size (0.40 cm at the cranial pole and 0.32 cm at the caudal pole), shape and overall architecture, echogenicity and echotexture. Visible surrounding vasculature appears normal.

The left adrenal gland is normal in size (0.28 cm), shape and overall architecture, echogenicity and echotexture. Visible surrounding vasculature appears normal.

Spleen

The spleen is subjectively normal in size with a normal smooth capsular contour. Parenchyma is appropriately finely textured and homogenous with normal echogenicity relative to surrounding tissue (hyperechoic to liver). No focal nodules or masses are observed. Splenic vasculature appears normal.

Liver

Liver is subjectively enlarged (swollen contour) without disruption of architecture. It has a normal homogenous echotexture. Parenchyma is diffusely hyperechoic characterized by less prominent than normal portal vein walls and increased echogenicity relative to the spleen and falciform fat. No focal lesions are observed. Visible vasculature and biliary tree appear normal without distension or congestion.

The gallbladder is non-distended in size. The wall is smooth without visible thickening. Luminal contents are primarily anechoic. There is no evidence of cystic or common bile duct dilation.

Gastrointestinal

The visible stomach wall is normal in thickness and layering. The lumen of the stomach is mildly distended with a small to moderate amount of echogenic non-shadowing luminal contents and gas consistent with normal ingesta. There is no evidence of obstruction, foreign material or infiltrative disease. Pyloric outflow tract appears patent.



PATIENT

Ruby Lysinger

SPECIES

Feline

BREED

DSH

SEX

Spayed Female

AGE

12 Years 1 Months

WEIGHT

9.6 lbs

INTERPRETED BY

Beth Johnson, DVM
DACVIM

IMAGING PERFORMED BY

Kathleen Byrnes

HOSPITAL NAME

Pet Care Clinic of the
High Country

REFERRING VET

Dr. Sturgill

INVOICE

72028

DATE

1/7/26

The visible small intestine demonstrates areas of moderately thick muscularis layer relative to mucosa (disruption of the normal 1:3 muscularis:mucosa ratio). Small intestinal submucosa is slightly irregular, thick and hyperechoic. In one view in particular there is a focal area of jejunum that appears to be slightly focally thick and may contain loss of layering, although it is difficult to rule out overlapping or adjacent bowel loops contributing to the change. The change is not visible in additional images and/or with further examination via the linear probe. The lumen of the small intestine is empty with no evidence of obstruction or foreign material.

The visible colon is normal in wall thickness (< 0.2 cm) and layering. Contents are consistent with normal formed feces and gas.

Pancreas

The pancreas that is observed appears appropriately isoechoic to surrounding omental fat. Visible capsule is smooth and normal in contour. Visible pancreatic parenchyma is homogenous and unremarkable. There is no visible pancreatic duct dilation. There is no evidence of active peripancreatic inflammation.

Free Abdomen

There is no visible free peritoneal effusion noted in these images.

There is no apparent pathologic lymphadenopathy noted in these images.

ULTRASONOGRAPHIC FINDINGS

- Moderate inflammatory bowel disease (IBD) pattern – Thick muscularis has been reported with infiltrative bowel disease including both benign inflammatory disease as well as infiltrative neoplasia such as lymphoma. No loss of layering or distinct characteristics of malignancy are present. Therefore, differentials cannot be further ranked without tissue sampling. **As described above, the one focal area of jejunum may represent more significant pathology but it is difficult to rule out overlapping bowel loops in these images.*
- Hyperechoic hepatomegaly (feline) – This appearance is most consistent with benign hepatic lipidosis or endocrine/DM hepatopathy. Infiltrative disease such as amyloidosis or round cell neoplasia, such as mast cell tumor or less likely, lymphoma, is also possible.

INTERPRETATION OF THE FINDINGS & FURTHER RECOMMENDATIONS

If not recently evaluated, a general metabolic health screen (CBC, chemistry panel with electrolytes and urinalysis) is recommended.

A T4 +/- free T4 is recommended if not recently evaluated.

A gastrointestinal malabsorption panel (including cobalamin, folate, TLI and PLI) to Texas A&M GI Laboratory is recommended for further evaluation of GI and pancreatic function.

Biopsies of the GI tract, being sure to include ileum, if possible, as well as close examination and biopsy of the focal jejunal area if it is truly present may be necessary for definitive diagnosis and therefore to further guide medical management.



PATIENT

Ruby Lysinger

SPECIES

Feline

BREED

DSH

SEX

Spayed Female

AGE

12 Years 1 Months

WEIGHT

9.6 lbs

INTERPRETED BY

Beth Johnson, DVM
 DACVIM

IMAGING PERFORMED BY

Kathleen Byrnes

HOSPITAL NAME

Pet Care Clinic of the
 High Country

REFERRING VET

Dr. Sturgill

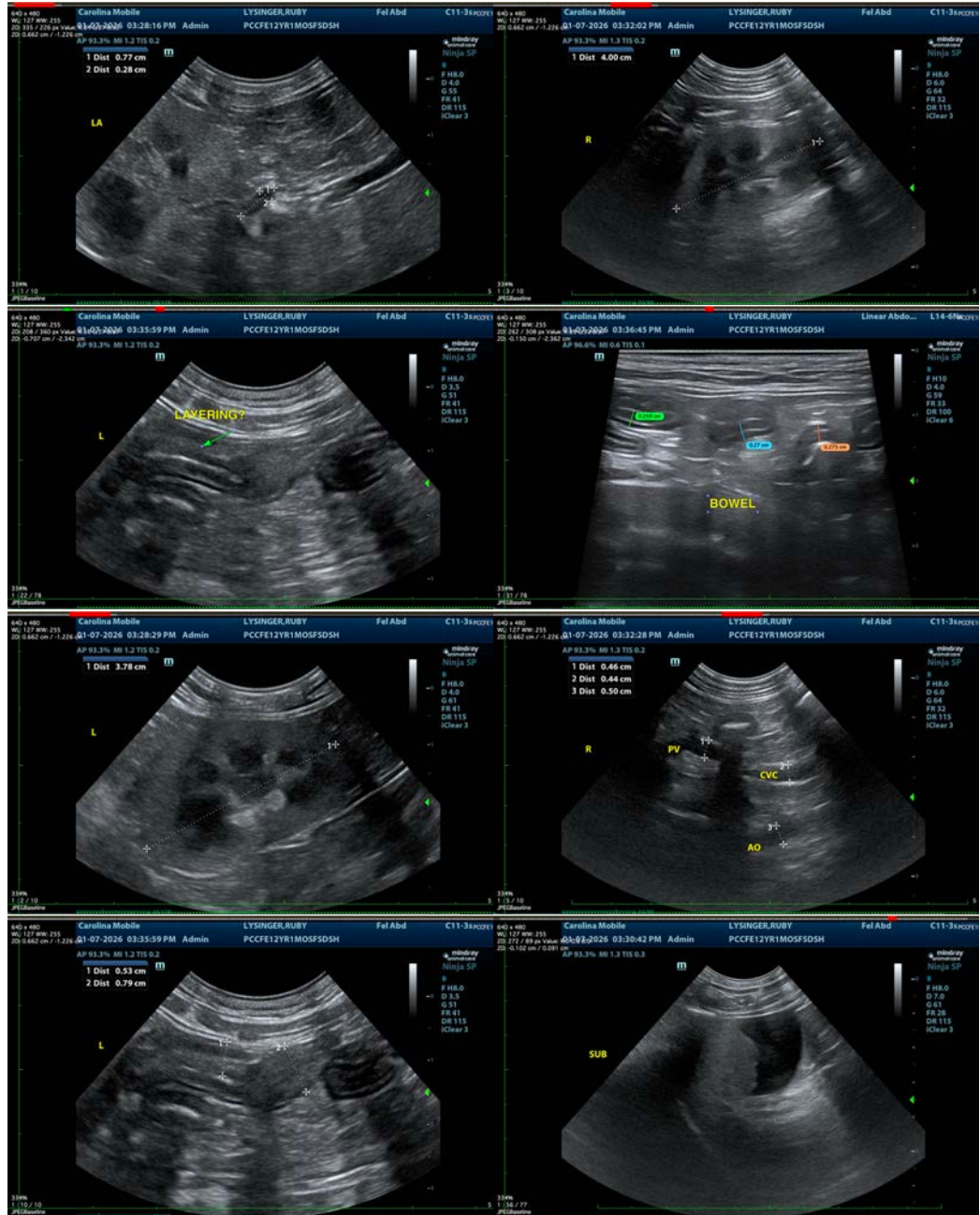
INVOICE

72028

DATE

1/7/26

In the meantime, supportive/symptomatic medical management of clinical signs is recommended, including a probiotic (such as visbiome or proviable), empirical deworming with a 5-day course of Panacur and, if tolerated, a transition in diet, based on trial-and-error response, beginning possibly with a gastrointestinal biome diet vs a hydrolyzed protein diet vs other. Some patients respond to one brand/version of a hydrolyzed protein diet better than another brand, so several brand attempts may be required.





PATIENT

Ruby Lysinger

SPECIES

Feline

BREED

DSH

SEX

Spayed Female

AGE

12 Years 1 Months

WEIGHT

9.6 lbs

INTERPRETED BY

Beth Johnson, DVM
DACVIM

IMAGING PERFORMED BY

Kathleen Byrnes

HOSPITAL NAME

Pet Care Clinic of the
High Country

REFERRING VET

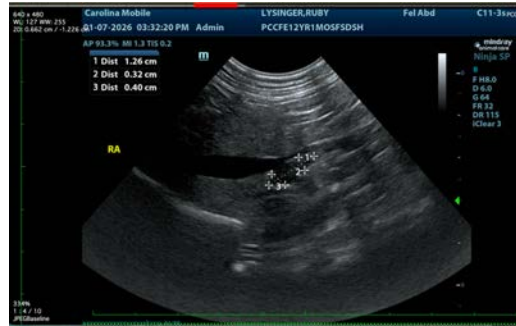
Dr. Sturgill

INVOICE

72028

DATE

1/7/26



The information and recommendations provided are based on the images presented by the referring veterinarian/sonographer. No evaluation can be communicated regarding pathology that was not visible in the image/video clips provided.

Thank you for this referral. If the clinical or image interpretation does not parallel your findings or if I can be of any further assistance please contact me.

Beth Johnson, DVM, DACVIM
info@sonopath.com