



**PATIENT**

Napoleon Corrado

**SPECIES**

Canine

**BREED**

Yorkie

**SEX**

Neutered Male

**AGE**

12 Years

**WEIGHT**

5.1 kg

**INTERPRETED BY**

Beth Johnson, DVM  
DACVIM

**IMAGING PERFORMED BY**

Kerri Becker

**HOSPITAL NAME**

Bond Vet Edgewater

**REFERRING VET**

Dr. Ordonez

**INVOICE**

72032

**DATE**

1/7/26

**PRESENTING CLINICAL SIGNS**

Hx of diarrhea- elev. alp,alt,ggt, chol. Attempted denamarin but no improvement. clavamox, denamarin, ondonsetran.

Abnormal PE/Chem/CBC/UA Results: Elev. bile acids.

**ULTRASONOGRAPHIC EXAMINATION OF THE ABDOMEN**

**Urinary System**

Urinary bladder is only mildly distended (empty). Visible contents are anechoic. Urinary bladder wall is unable to be fully assessed for pathology without further distension. No visible masses or definitive cystoliths are observed. The trigone and visible pelvic urethra are normal thickness with a smooth mucosal surface. In the face of urinary signs and/or suspected urinary bladder pathology, reassessment after complete filling is recommended.

Prostate is normal in size, echotexture and echogenicity for a neutered male.

Kidneys are overall normal in size and shape with smooth peripheral margination. A normal 1:3 cortex to medulla ratio is maintained. The medulla and cortices are uniform in texture with some mild increased cortical echogenicity and mild loss of corticomedullary distinction, expected in this age patient. There is no evidence of pyelectasia, mineral or infarcts observed. Left measures 4.03 cm. Right measures 4.18 cm. Small cortical cysts are present bilaterally.

**Adrenal Glands**

The adrenal glands technically measure normal in size but appear subjectively mildly "plump"/swollen for a small dog. Normal shape and contour are maintained without evidence of capsular invasion. Corticomedullary structure is unremarkable. Visible surrounding vasculature appears normal.

**Spleen**

Spleen is subjectively normal in size with a normal smooth capsular contour. Parenchyma is appropriately finely textured and homogenous with normal echogenicity relative to surrounding tissue (hyperechoic to liver). No focal nodules or masses are observed. Multifocal mineral foci are noted. Splenic vasculature appears normal.

**Liver**

Liver is subjectively enlarged with mildly irregular margins. Parenchyma is moderately heterogenous characterized by multiple poorly defined hypoechoic nodules within otherwise hyperechoic liver parenchyma. Visible vasculature and biliary tree appear normal without distension or congestion

Gallbladder is moderately distended with anechoic bile as well as suspended and gravity dependent echogenic debris. The wall is smooth without visible thickening. There is no evidence of cystic or CBD dilation. There is no evidence of effusion or inflammation. Additionally, there appears to be an approximately 1.3 cm in diameter non-shadowing, non-visibly obstructive mineral density/cholecystolith.



**PATIENT**

Napoleon Corrado

**SPECIES**

Canine

**BREED**

Yorkie

**SEX**

Neutered Male

**AGE**

12 Years

**WEIGHT**

5.1 kg

**INTERPRETED BY**

Beth Johnson, DVM  
 DACVIM

**IMAGING PERFORMED BY**

Kerri Becker

**HOSPITAL NAME**

Bond Vet Edgewater

**REFERRING VET**

Dr. Ordonez

**INVOICE**

72032

**DATE**

1/7/26

**Gastrointestinal**

The visible stomach wall is normal in thickness and layering. The lumen of the stomach is mildly distended with very echogenic reverberation artifact from intraluminal gas. There is no evidence of obstruction, foreign material, or infiltrative disease; however, visualization is partially inhibited by gas.

The visible small intestines are normal in wall thickness and layering. Hyperechoic mucosal fogging or speckling is noted. Small intestinal motility appears adequate (1-3 contractions per min). The lumen of the small intestine is empty with no evidence of obstruction or foreign material.

The visible colon is normal in wall thickness (< 0.2 cm) and layering. Contents are consistent with normal formed feces and gas.

**Pancreas**

The pancreas that is observed appears appropriately isoechoic to surrounding omental fat. Visible capsule is smooth and normal in contour. Visible pancreatic parenchyma is homogenous and unremarkable. There is no visible pancreatic duct dilation. There is no evidence of active peripancreatic inflammation.

**Free Abdomen**

There is no visible free peritoneal effusion noted in these images.

There is no apparent pathologic lymphadenopathy noted in these images.

**PRIMARY FINDINGS**

- Mild to moderate mucosal speckling – Mucosal speckling is often present with inflammatory bowel disease (IBD). It is not specific for type or severity of disease. Mild speckling change can occur as a normal patient variant in the post-prandial state.
- Subjective mild bilateral adrenomegaly – In a patient diagnosed with hyperadrenocorticism, this finding is most consistent with adrenal hyperplasia secondary to pituitary dependent hyperadrenocorticism. This finding can also be seen with stress and/or normal patient variant. Interpret in combination with clinical signs of hyperadrenocorticism and/or other adrenal disease.
- Moderately Heterogenous Liver – These changes are most consistent with benign processes such as nodular hyperplasia, steroid (vacuolar) hepatopathy, extramedullary hematopoiesis or possibly chronic inflammatory disease and less commonly infiltrative round cell or metastatic neoplasia.
- Moderate gallbladder debris - Cholecystic debris is of unknown clinical significance. It can be seen with biliary stasis from fasting or illness. Cholecystic debris is not necessarily related to hepatobiliary disease. Echogenic bile is most commonly an incidental finding in dogs and should be interpreted in combination with clinical signs such as nausea, inappetence, cranial abdominal discomfort and/or laboratory changes such as increased ALP and/or increased Tbili. A non-shadowing, non-visibly obstructive cholecystolith is suspected.
- Spleen mineralization – This is a benign change but can be associated with endocrinopathies, especially hyperadrenocorticism.



**PATIENT**

Napoleon Corrado

**SPECIES**

Canine

**BREED**

Yorkie

**SEX**

Neutered Male

**AGE**

12 Years

**WEIGHT**

5.1 kg

**INTERPRETED BY**

Beth Johnson, DVM  
 DACVIM

**IMAGING PERFORMED BY**

Kerri Becker

**HOSPITAL NAME**

Bond Vet Edgewater

**REFERRING VET**

Dr. Ordonez

**INVOICE**

72032

**DATE**

1/7/26

**SECONDARY FINDINGS**

- Age related kidney changes with bilateral cortical cysts.

**INTERPRETATION OF THE FINDINGS & FURTHER RECOMMENDATIONS**

Further gastrointestinal workup recommendations, given patient's reported diarrhea, include a routine fecal/giardia exam if not recently evaluated.

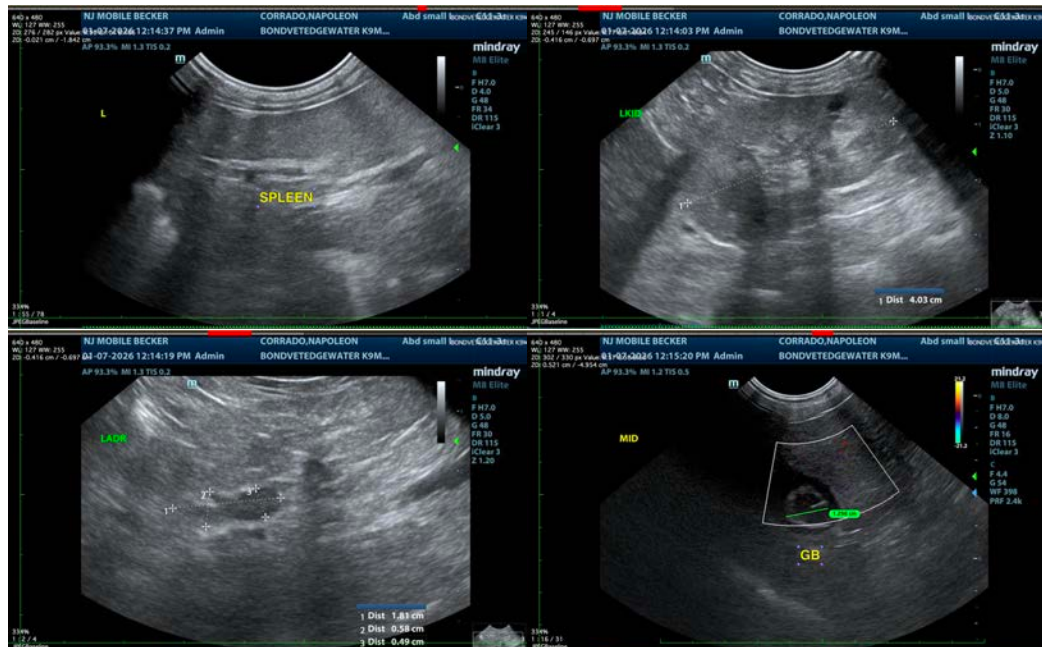
A gastrointestinal malabsorption panel (including cobalamin, folate, TLI and PLI) to Texas A&M GI Laboratory is recommended for further evaluation of GI and pancreatic function.

A fecal enteropathogen PCR panel to Texas A&M GI Laboratory could be considered for further evaluation of possible infectious disease. Contact lab for recommendations on how long to discontinue antibiotics (if indicated) prior to obtaining a stool sample for submission.

In the meantime, supportive/symptomatic medical management of clinical signs is recommended, including a probiotic (such as visbiome or proviable), empirical deworming with a 5-day course of Panacur and, if tolerated, a transition in diet, based on trial-and-error response, beginning possibly with a gastrointestinal biome diet vs a hydrolyzed protein diet vs other. Some patients respond to one brand/version of a hydrolyzed protein diet better than another brand, so several brand attempts may be required.

Ultimately, if clinical signs persist and a diagnosis is not made, biopsies of the GI tract may be necessary for definitive diagnosis and therefore to further guide medical management.

Further recommendations regarding patient's reportedly increased liver enzymes are largely dependent on the degree of increase, clinical history, etc.





**PATIENT**

Napoleon Corrado

**SPECIES**

Canine

**BREED**

Yorkie

**SEX**

Neutered Male

**AGE**

12 Years

**WEIGHT**

5.1 kg

**INTERPRETED BY**

Beth Johnson, DVM  
 DACVIM

**IMAGING PERFORMED BY**

Kerri Becker

**HOSPITAL NAME**

Bond Vet Edgewater

**REFERRING VET**

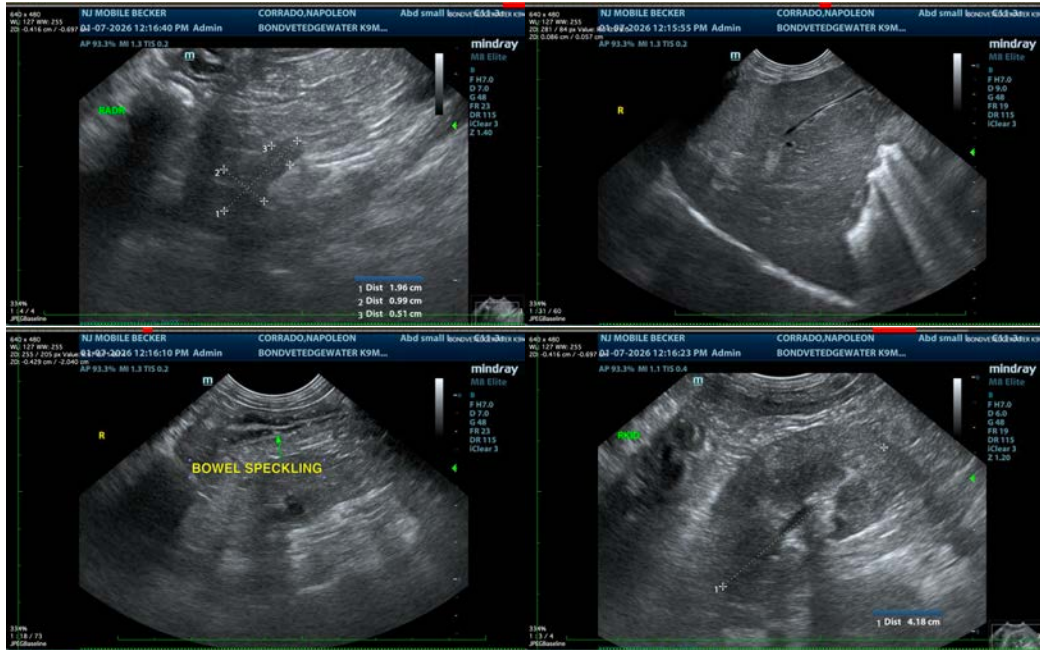
Dr. Ordonez

**INVOICE**

72032

**DATE**

1/7/26



The information and recommendations provided are based on the images presented by the referring veterinarian/sonographer. No evaluation can be communicated regarding pathology that was not visible in the image/video clips provided.

Thank you for this referral. If the clinical or image interpretation does not parallel your findings or if I can be of any further assistance please contact me.

**Beth Johnson, DVM, DACVIM**  
 info@sonopath.com