



PATIENT PRESENTING CLINICAL SIGNS

Moxy Brens O said hasn't pooped since New years eve. -Seen here Friday January 2nd for two enemas (admitted for afternoon). Enemas included lactulose in the mixture and lactulose to take orally at home. Took 1 xray to see how backed up she was., -Seen here Monday January 5th for recheck - still no pooping and occasional vomit in house after going outside straingning. Admitted for the day and Put on IV. fluids and another enema given. Outside walks were no BM but LOTS OF GAS AND FARTING. Ate readily for us. we Took xrays after admitting before starting on fluids. Did another xray in the evening before sending home with iv cath port in place still. - Seen here Tuesday January 6th for recheck around 2pm. Repeated xray. still lots of gas. Gave bolus of IV fluids sent home with gabapentin capsules Current Medications Gabapentin capsules - 300mg . Give 1 cap BID.

SPECIES Canine

BREED Bulldog

SEX Abnormal PE/Chem/CBC/UA Results: Rads attached.

Spayed Female * We think it's appropriate that this exam is significantly limited by the large amount of intraabdominal gastrointestinal gas. *

AGE ULTRASONOGRAPHIC EXAMINATION OF THE ABDOMEN

11 years **Urinary System**

WEIGHT Urinary bladder is adequately distended with primarily anechoic contents and occasional echogenic non-shadowing debris. Apical urinary bladder wall is diffusely thick (0.49 cm). Mucosa is hyperechoic and irregular. No masses or cystoliths are observed. Beginning in the trigone, extending into the pelvis, there is some mildly heterogenous, thick tissue that could represent a thick, irregular, heterogenous urethra. Although, the entire caudal abdomen demonstrates a similar appearance with poor detail between tissues and versus true associates or origination from the urinary tract, this change could be other pathology and/or iatrogenic as the result of multiple recent enemas.

INTERPRETED BY
 Beth Johnson, DVM
 DACVIM

Kidneys are overall normal in size and shape with smooth peripheral margination. A normal 1:3 cortex to medulla ratio is maintained. The medulla and cortices are uniform in texture with some mild increased cortical echogenicity and mild loss of corticomedullary distinction, expected in this age patient. There is no evidence of mineral or infarcts observed. Mild to moderate pyelectasia is noted bilaterally measuring 0.48 cm sagittal view in the left, and 0.65 cm sagittal view in the right. Additionally, there is approximately 1.0 cm in diameter anechoic density in the caudal pole of the right kidney. Left kidney measures 6.23 cm. Right kidney measures 6.29 cm.

IMAGING PERFORMED BY

Kelly Reschny

HOSPITAL NAME

Beamsville AH

Adrenal Glands

REFERRING VET

Dr. Josan

The right adrenal gland is normal in size (1.9 cm at cranial pole and 0.92 cm at caudal pole), shape and overall architecture, echogenicity and echotexture. Visible surrounding vasculature appears normal.

INVOICE

11041

The left adrenal gland is normal in size (0.69 cm at cranial pole and 0.66 cm at caudal pole), shape and overall architecture, echogenicity and echotexture. Visible surrounding vasculature appears normal.

DATE

1/7/2026

Spleen

The spleen is unable to be visualized in these images.

Liver

The liver is subjectively normal in size with normal smooth curvilinear peripheral contour. Parenchyma is appropriately hypoechoic to the spleen in echogenicity and appropriately mildly coarse and



PATIENT	homogenous in echotexture. No focal lesions are observed. Visible vasculature and biliary tree appear normal without distension or congestion.
Moxy Brens	
SPECIES	The gallbladder is non-distended in size. The wall is smooth without visible thickening. Luminal contents are primarily anechoic. There is no evidence of cystic or common bile duct dilation.
Canine	
BREED	<i>Gastrointestinal</i>
Bulldog	The visible stomach wall is normal in thickness and layering. The lumen of the stomach is mildly distended with very echogenic reverberation artifact from intraluminal gas. There is no evidence of obstruction, foreign material, or infiltrative disease; however, visualization is partially inhibited by gas. Pyloric outflow tract appears patent.
SEX	The visible small intestines are normal in wall thickness and layering. Small intestinal motility appears adequate (1-3 contractions per min). The lumen of the small intestine is mildly distended with very echogenic reverberation artifact from intraluminal gas. There is no evidence of obstruction, foreign material, or infiltrative disease; however, visualization is partially inhibited by gas.
Spayed Female	
AGE	The colon wall is difficult to assess due to the large amount of reverberation artifact from gas. No definitive gastrointestinal wall, including colon wall, pathology is noted in these images but it can't be ruled out.
11 years	
WEIGHT	<i>Pancreas</i>
68 lbs	The pancreas that is observed appears appropriately isoechoic to surrounding omental fat. Visible capsule is smooth and normal in contour. Visible pancreatic parenchyma is homogenous and unremarkable. There is no visible pancreatic duct dilation. There is no evidence of active peripancreatic inflammation.
INTERPRETED BY	<i>Free Abdomen</i>
Beth Johnson, DVM DACVIM	There is no visible free peritoneal effusion noted in these images.
IMAGING PERFORMED BY	There is no apparent pathologic lymphadenopathy noted in these images.
Kelly Reschny	
HOSPITAL NAME	ULTRASONOGRAPHIC FINDINGS
Beamsville AH	<ul style="list-style-type: none"> The urinary bladder wall changes could indicate some chronic low grade smoldering cystitis, and if the changes in the pelvic area are in fact urethra, infiltrative neoplasia can't be definitively ruled out. As stated above, however, the changes in the pelvis could be non-pathologic changes and potentially iatrogenic change/inflammation as a result of multiple enemas.
REFERRING VET	<ul style="list-style-type: none"> Age related kidney changes with moderate bilateral pyelectasia, and a suspect cortical cyst in the right kidney.
Dr. Josan	<ul style="list-style-type: none"> A large amount of gastrointestinal gas.
INVOICE	
11041	
DATE	<u>INTERPRETATION OF THE FINDINGS & FURTHER RECOMMENDATIONS</u>
1/7/2026	A full general metabolic health screen is recommended to include CBC, chemistry panel, and electrolytes.



PATIENT

Moxy Brens

Additionally, Urinalysis and, if indicated based on urinalysis results, urine culture is recommended. If protein is present in an otherwise quiet sediment, protein quantification with a urine protein to creatinine ration is recommended.

SPECIES

Canine

Especially if any of patient's straining could be urinary versus GI, submission of urine to look for BRAF gene mutation could be considered.

BREED

Bulldog

Otherwise, again, while full evaluation of the colon is partially limited in this study due to gas, there is no definitively visible evidence of constipation. Therefore, continued feeding, supportive/symptomatic medical management of nausea, etc., for the next day or so may result in a bowel movement and resolution of the gas. If not, alternative imaging such as contrast radiography, potentially an abdominal CT scan versus other may be warranted.

SEX

Spayed Female

AGE

11 years

WEIGHT

68 lbs

INTERPRETED BY

Beth Johnson, DVM
DACVIM

IMAGING PERFORMED BY

Kelly Reschny

HOSPITAL NAME

Beamsville AH

REFERRING VET

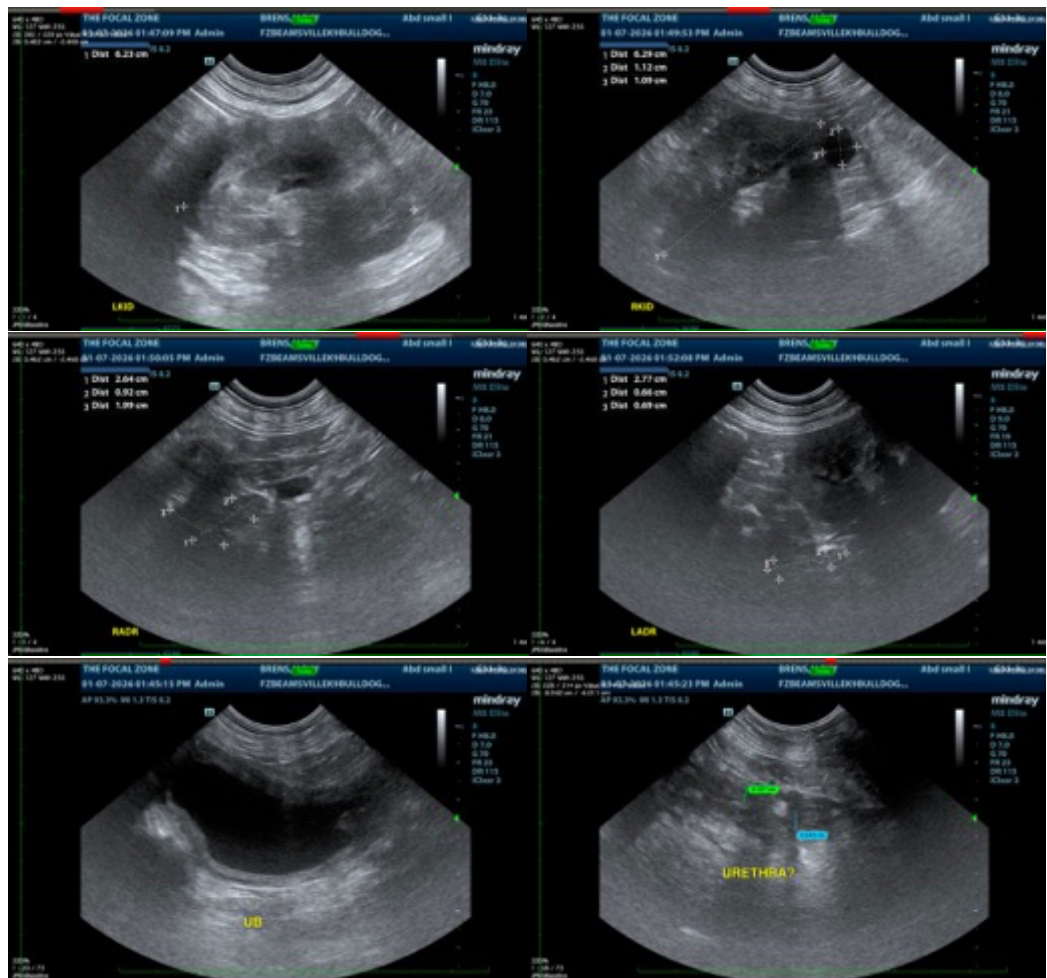
Dr. Josan

INVOICE

11041

DATE

1/7/2026





PATIENT

Moxy Brens

SPECIES

Canine

BREED

Bulldog

SEX

Spayed Female

AGE

11 years

WEIGHT

68 lbs

INTERPRETED BY

Beth Johnson, DVM
 DACVIM

IMAGING PERFORMED BY

Kelly Reschny

HOSPITAL NAME

Beamsville AH

REFERRING VET

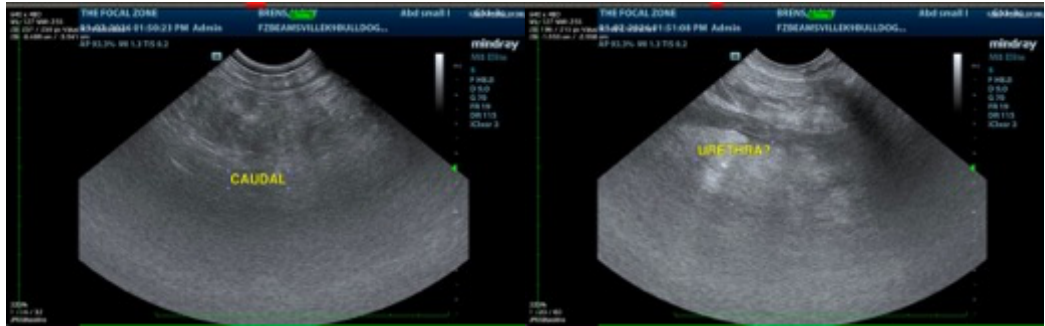
Dr. Josan

INVOICE

11041

DATE

1/7/2026



The information and recommendations provided are based on the images presented by the referring veterinarian/sonographer. No evaluation can be communicated regarding pathology that was not visible in the image/video clips provided.

Thank you for this referral. If the clinical or image interpretation does not parallel your findings or if I can be of any further assistance please contact me.

Beth Johnson, DVM, DACVIM
 info@sonopath.com