



**PATIENT**

Elvis Wilson

**SPECIES**

Canine

**BREED**

Boxer x

**SEX**

Neutered Male

**AGE**

1 Year

**WEIGHT**

70 lbs

**INTERPRETED BY**

Beth Johnson, DVM  
 DACVIM

**IMAGING PERFORMED BY**

Kelly Reschny

**HOSPITAL NAME**

Hamilton Region  
 Veterinary Emergency  
 Clinic

**REFERRING VET**

Dr. Ho

**INVOICE**

72987

**DATE**

1/7/26

**PRESENTING CLINICAL SIGNS**

ADR today, not wanting to eat, lethargic at home, vomited water today; O concerned it pancreatitis vomited a fabric chicken toy foot in clinic today Current Medications Cerenia, metronidazole

**ULTRASONOGRAPHIC EXAMINATION OF THE ABDOMEN**

**Urinary System**

The urinary bladder is adequately distended with anechoic contents. No masses, inflammatory changes, echogenic sediment or cystoliths are observed. The urinary bladder, trigone and visible pelvic urethra are normal in thickness with a smooth mucosal surface.

Prostate is normal in size, echotexture and echogenicity for a neutered male.

The right kidney is normal is size (6.84 cm), shape and echogenicity. It has smooth peripheral margination. There is a normal 1:3 cortex to medulla ratio with appropriate corticomedullary distinction. There is no evidence of pyelectasia, mineral or infarcts observed.

The left kidney is normal is size (6.24 cm), shape and echogenicity. It has smooth peripheral margination. There is a normal 1:3 cortex to medulla ratio with appropriate corticomedullary distinction. There is no evidence of pyelectasia, mineral or infarcts observed.

**Adrenal Glands**

The right adrenal gland is normal in size (2.3 cm at cranial pole and 0.79 cm at caudal pole), shape and overall architecture, echogenicity and echotexture. Visible surrounding vasculature appears normal.

The left adrenal gland is normal in size (0.52 cm at cranial pole and 0.56 cm at caudal pole), shape and overall architecture, echogenicity and echotexture. Visible surrounding vasculature appears normal.

**Spleen**

The spleen is subjectively normal in size with a normal smooth capsular contour. Parenchyma is appropriately finely textured and homogenous with normal echogenicity relative to surrounding tissue (hyperechoic to liver). No focal nodules or masses are observed. Splenic vasculature appears normal.

**Liver**

The liver is subjectively normal in size with normal smooth curvilinear peripheral contour. Parenchyma is appropriately hypoechoic to the spleen in echogenicity and appropriately mildly coarse and homogenous in echotexture. No focal lesions are observed. Visible vasculature and biliary tree appear normal without distension or congestion.

The gallbladder is non-distended in size. The wall is smooth without visible thickening. Luminal contents are primarily anechoic. There is no evidence of cystic or common bile duct dilation.

**Gastrointestinal**

The visible stomach wall is normal in thickness and layering. The lumen of the stomach is mildly fluid distended with an additional non-shadowing echogenic density most consistent visually with ingesta, although non-shadowing, non- or intermittently obstructive foreign material can't be definitively ruled out.



**PATIENT**

Elvis Wilson

**SPECIES**

Canine

**BREED**

Boxer x

**SEX**

Neutered Male

**AGE**

1 Year

**WEIGHT**

70 lbs

**INTERPRETED BY**

Beth Johnson, DVM  
 DACVIM

**IMAGING PERFORMED BY**

Kelly Reschny

**HOSPITAL NAME**

Hamilton Region  
 Veterinary Emergency  
 Clinic

**REFERRING VET**

Dr. Ho

**INVOICE**

72987

**DATE**

1/7/26

Similarly, the visible small intestines are normal in wall thickness and layering. Small intestinal motility appears adequate (1-3 contractions per min). The lumen of the small intestine is diffusely mildly distended with fluid and echogenic non-shadowing contents most consistent with normal ingesta/chyme. Having said that, non-fully obstructive, non-shadowing foreign material, while thought less likely can't be definitively ruled out.

The visible colon is normal in wall thickness (< 0.2 cm) and layering. Contents are consistent with normal formed feces and gas.

***Pancreas***

The pancreas that is observed appears appropriately isoechoic to surrounding omental fat. Visible capsule is smooth and normal in contour. Visible pancreatic parenchyma is homogenous and unremarkable. There is no visible pancreatic duct dilation. There is no evidence of active peripancreatic inflammation.

***Free Abdomen***

There is no visible free peritoneal effusion noted in these images.

Mesenteric lymph nodes are prominent in size with swollen capsular contour. Normal elongated shape (length to width ratio) is maintained. There is no loss of parenchymal detail.

**ULTRASONOGRAPHIC FINDINGS**

- Reactive mesenteric lymph nodes – infiltrative neoplastic disease cannot be ruled out but is considered less likely.
- As described above, the gastrointestinal contents appear visibly most consistent with normal ingesta, although non-fully or intermittently obstructive non-shadowing foreign material, while thought less likely, can't be definitively ruled out.
- Additionally, while there is no definitive ultrasonographically visible evidence of pancreatitis, mild or emerging pancreatitis can't be definitively ruled out.

**INTERPRETATION OF THE FINDINGS & FURTHER RECOMMENDATIONS**

If not recently evaluated, a general metabolic health screen (CBC, chemistry panel with electrolytes and urinalysis) is recommended.

A gastrointestinal malabsorption panel (including cobalamin, folate, TLI and PLI) to Texas A&M GI Laboratory is recommended for further evaluation of GI and pancreatic function.

In the meantime, supportive/symptomatic medical management of clinical signs is recommended, including anti-emetics, gastroprotectants (+/- sucralfate, especially with any history of hematemesis), an appetite stimulant and fluid therapy if indicated, etc.

Additionally, empirical deworming with a 5-day course of Panacur is recommended as is a full course of empirical Helicobacter triple therapy.

Finally, if tolerated, a transition in diet could be considered, based on trial-and-error response with some options to consider including a gastrointestinal biome diet vs a hydrolyzed protein diet



**PATIENT**

Elvis Wilson

**SPECIES**

Canine

**BREED**

Boxer x

**SEX**

Neutered Male

**AGE**

1 Year

**WEIGHT**

70 lbs

**INTERPRETED BY**

Beth Johnson, DVM  
DACVIM

**IMAGING PERFORMED BY**

Kelly Reschny

**HOSPITAL NAME**

Hamilton Region  
Veterinary Emergency  
Clinic

**REFERRING VET**

Dr. Ho

**INVOICE**

72987

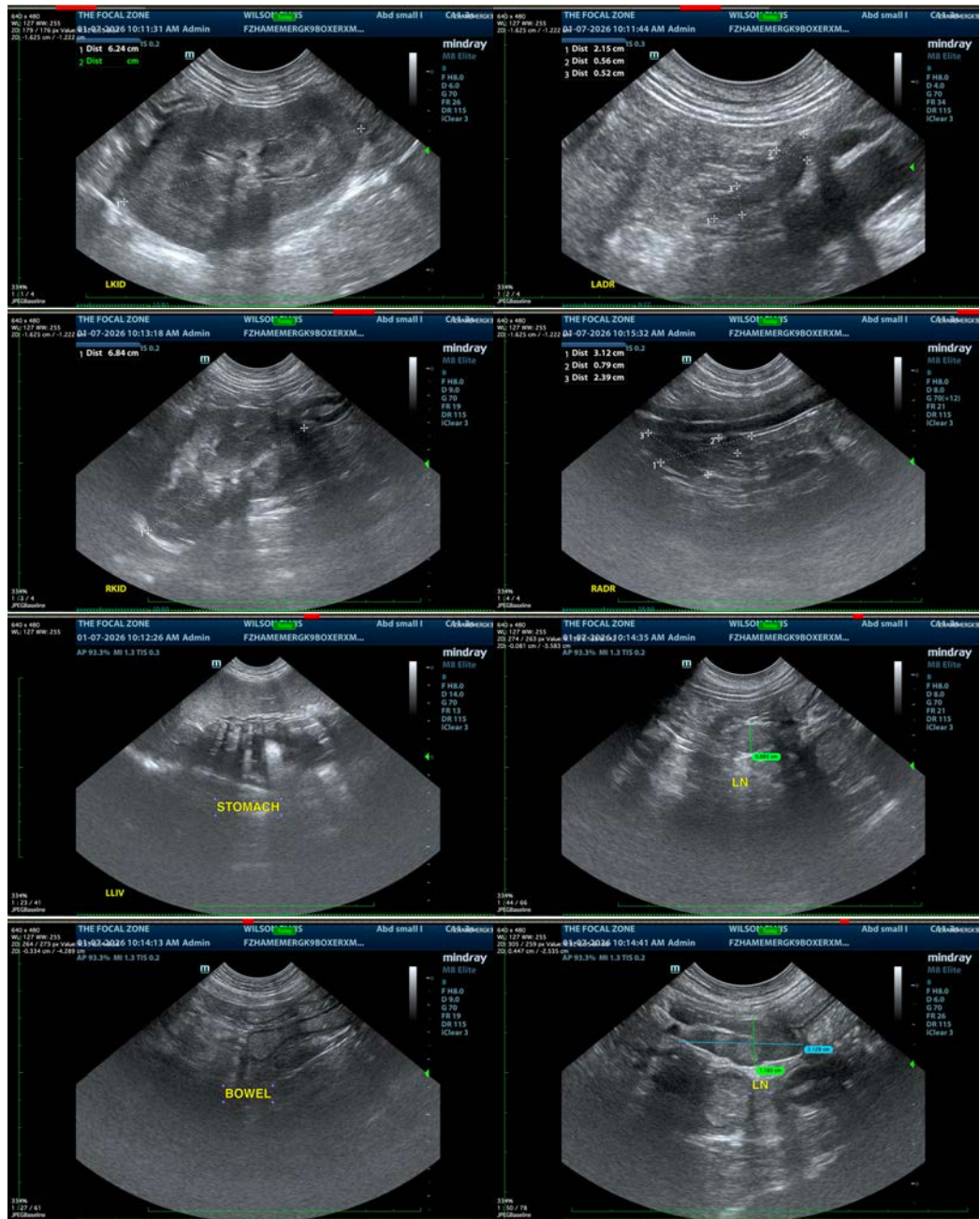
**DATE**

1/7/26

(sometimes several trials with different brands are necessary) vs an easy to digest, bland or low-fat diet vs other.

If clinical signs persist and a diagnosis is not made, recheck imaging ideally following an additional 12-24 hour fast and/or additional imaging such as contrast radiography, gastroscopy, etc. could be considered.

Additionally, sampling of the enlarged lymph nodes via fine needle aspirates could also be considered if patient's coagulation status is appropriate.





**PATIENT**

Elvis Wilson

The information and recommendations provided are based on the images presented by the referring veterinarian/sonographer. No evaluation can be communicated regarding pathology that was not visible in the image/video clips provided.

**SPECIES**

Canine

Thank you for this referral. If the clinical or image interpretation does not parallel your findings or if I can be of any further assistance please contact me.

**BREED**

Boxer x

**Beth Johnson, DVM, DACVIM**  
[info@sonopath.com](mailto:info@sonopath.com)

**SEX**

Neutered Male

**AGE**

1 Year

**WEIGHT**

70 lbs

**INTERPRETED BY**

Beth Johnson, DVM  
DACVIM

**IMAGING PERFORMED BY**

Kelly Reschny

**HOSPITAL NAME**

Hamilton Region  
Veterinary Emergency  
Clinic

**REFERRING VET**

Dr. Ho

**INVOICE**

72987

**DATE**

1/7/26