



PATIENT

Crystal Lee

SPECIES

Feline

BREED

DMH

SEX

FS

AGE

8 years 10 months

WEIGHT

4.14 kg

INTERPRETED BY

Beth Johnson, DVM
DACVIM

IMAGING PERFORMED BY

Loetitia Saint-Jacques,
LVT

HOSPITAL NAME

Four Paws Animal
Clinic

REFERRING VET

Dr. Susan Lester

INVOICE

11069

DATE

1/7/2026

PRESENTING CLINICAL SIGNS

P presented to establish care 1.2.26: ADR. App down starting about 2 months ago, sudden change. Weight loss. Hiding (usually affectionate). Weak, will fall. Has had for about 10y (age we have in system is about 9y). V more than usual for the last few weeks - v about once a day, yellow/white liquid. Indoor only. MEDS- 5mg Prednisolone q 24hrs x 3 days, now finished. 0.45mLs Convenia 1.2.26, 150mLs LRS SQ q 24 hrs starting 1.2.26 Icteric.

Abnormal PE/Chem/CBC/UA Results: Icteric 1.2.26: Sodium 137 (150 - 165 mmol/L) Potassium 3.4 (3.5 - 5.8 mmol/L) Chloride 94 (112 - 129 mmol/L) ALT 349 (12 - 130 U/L) ALP 1,275 (14 - 111 U/L) GGT 9 (0 - 4 U/L) Bilirubin - Total 15.2 (0.0 - 0.9 mg/dL) Cholesterol 253 (65 - 225 mg/dL) Pancreatic Lipase 7.0 (0.0 - 4.4 U/L)

ULTRASONOGRAPHIC EXAMINATION OF THE ABDOMEN

Urinary System

The urinary bladder is adequately distended with anechoic contents. No masses, inflammatory changes or echogenic sediment is observed. The urinary bladder, trigone and visible pelvic urethra are normal in thickness with a smooth mucosal surface. Multiple cystoliths are noted settled along the interdependent wall. The largest of which appears to measure approximately 0.38 cm to 0.4 cm in size. However, the cystoliths are laying in clumps making exact measurement difficult.

The right kidney is normal is size (3.96 cm), shape and echogenicity. It has smooth peripheral margination. There is a normal 1:3 cortex to medulla ratio with appropriate corticomedullary distinction. There is no evidence of pyelectasia, mineral or infarcts observed.

The left kidney is normal is size (3.78 cm), shape and echogenicity. It has smooth peripheral margination. There is a normal 1:3 cortex to medulla ratio with appropriate corticomedullary distinction. There is no evidence of pyelectasia, mineral or infarcts observed.

Adrenal Glands

The right adrenal gland is normal in size (0.41 cm), shape and overall architecture, echogenicity and echotexture. Visible surrounding vasculature appears normal.

The left adrenal gland is normal in size (0.34 cm), shape and overall architecture, echogenicity and echotexture. Visible surrounding vasculature appears normal.

Spleen

Spleen measures at the upper ends of normal limits for thickness, at 1 cm thick at the hilus with a mildly swollen but smooth capsule. Parenchyma is normal and homogenous in echogenicity and echotexture. No focal nodules or masses are observed. Splenic vasculature appears normal.

Liver

Liver is subjectively enlarged (swollen contour) without disruption of architecture. It has a normal homogenous echotexture. Parenchyma is diffusely hyperechoic characterized by less prominent than normal portal vein walls and increased echogenicity relative to the spleen and falciform fat. No focal lesions are observed. Visible vasculature and biliary tree appear normal without distension or congestion.



PATIENT

Crystal Lee

SPECIES

Feline

BREED

DMH

SEX

FS

AGE

8 years 10 months

WEIGHT

4.14 kg

INTERPRETED BY

Beth Johnson, DVM
DACVIM

**IMAGING
PERFORMED BY**

Loetitia Saint-Jacques,
LVT

HOSPITAL NAME

Four Paws Animal
Clinic

REFERRING VET

Dr. Susan Lester

INVOICE

11069

DATE

1/7/2026

Gallbladder is moderately distended with anechoic bile as well as suspended and gravity dependent echogenic debris. The wall is smooth without visible thickening. The cystic and common bile duct are diffusely tortuous in appearance without pathologic distension noted in these images at this time. Multifocal punctate mineral densities are noted throughout the connection system most prominently in the proximal duct with no distension noted to make obstruction a definitive concern. Partial or intermittent obstruction however can't be ruled out.

Gastrointestinal

The visible stomach wall is normal in thickness and layering. The lumen of the stomach is empty with no evidence of obstruction, foreign material or infiltrative disease. Pyloric outflow tract appears patent.

The visible small intestine demonstrates areas of moderately thick muscularis layer relative to mucosa (disruption of the normal 1:3 muscularis:mucosa ratio). Small intestinal submucosa is slightly irregular, thick and hyperechoic, without evident loss of layering appreciated. The lumen of the small intestine is empty with no evidence of obstruction or foreign material.

The visible colon is normal in wall thickness (< 0.2 cm) and layering. Contents are consistent with normal formed feces and gas.

Pancreas

Pancreas is prominent (enlarged) in size, hypoechoic to surrounding tissue and has a mildly irregular undulating contour. Parenchyma is coarse with mixed echogenic remodeling noted. No pancreatic duct dilation is noted.

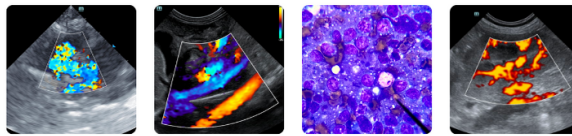
Free Abdomen

There is a very scant/trace pocket of free fluid noted caudal to the spleen.

There is no apparent pathologic lymphadenopathy noted in these images.

ULTRASONOGRAPHIC FINDINGS

- Moderate inflammatory bowel disease (IBD) pattern – Thick muscularis has been reported with infiltrative bowel disease including both benign inflammatory disease as well as infiltrative neoplasia such as lymphoma. No loss of layering or distinct characteristics of malignancy are present. Therefore, differentials cannot be further ranked without tissue sampling.
- Hyperechoic hepatomegaly – This appearance is most consistent with benign hepatic lipidosis or endocrine/DM hepatopathy. Infiltrative disease such as amyloidosis or round cell neoplasia, such as mast cell tumor or less likely, lymphoma, is also possible.
- The biliary mineral and duct mineral could suggest concurrent chronic low grade smoldering cholangitis with partial or intermittent obstruction from the mineral, unable to be definitively ruled out.
- Mild/early splenomegaly– can be associated with congestion caused by sedation (if sedated) but can also be associated with diffuse infiltrative disease. Both benign conditions such as



PATIENT

Crystal Lee

SPECIES

Feline

BREED

DMH

SEX

FS

AGE

8 years 10 months

WEIGHT

4.14 kg

INTERPRETED BY

Beth Johnson, DVM
DACVIM

IMAGING PERFORMED BY

Loetitia Saint-Jacques,
LVT

HOSPITAL NAME

Four Paws Animal
Clinic

REFERRING VET

Dr. Susan Lester

INVOICE

11069

DATE

1/7/2026

extramedullary hematopoiesis, lymphoid hyperplasia, amyloidosis as well as infiltrative neoplastic diseases such as round cell neoplasia should be considered.

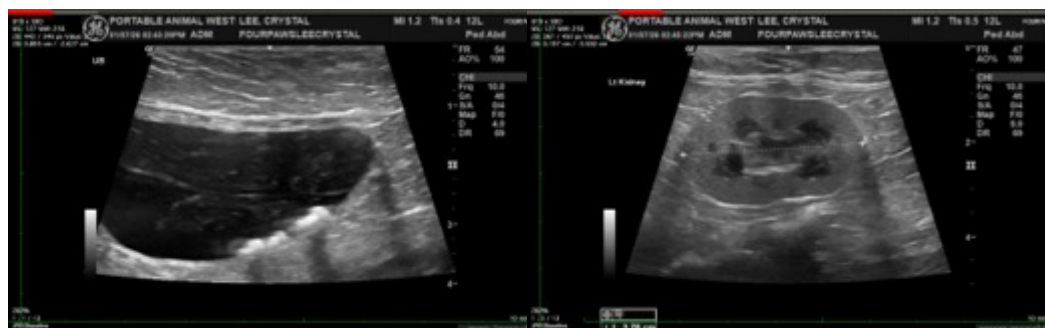- Chronic low grade smoldering pancreatitis can't be ruled out and should be suspected in the face of appropriate clinical signs.
- Scant/trace pocket of free fluid is of unknown origin. Differentials (unless already ruled out) could include increased hydrostatic pressure (cardiac disease and/or vascular or lymph blockage), decreased oncotic pressure (low albumin), vasculitis, paraneoplastic fluid, rupture/leakage of/from an organ (GI, GB, UB, other), blood (hemoabdomen), other.
- Multiple urinary bladder cystoliths.

INTERPRETATION OF THE FINDINGS & FURTHER RECOMMENDATIONS

The appearance of this abdomen is consistent with possible triaditis involving the bowel, pancreas, and hepatobiliary system. Infiltrative neoplastic disease affecting one or all three organs, however, can't be definitively ruled out. Therefore, recommendations include:

- A gastrointestinal malabsorption panel (including cobalamin, folate, TLI and PLI) to Texas A&M GI Laboratory is recommended for further evaluation of GI and pancreatic function.
- Fine needle aspirates of the liver +/- spleen, are recommended if patient's coagulation status is appropriate.
- Ultimately, however, a definitive diagnosis may require biopsies of the GI tract being sure to include ileum, if possible.

In the meantime, treatment recommendations include fluid therapy, anti-emetics, gastroprotectants, hepatic nutraceuticals such as ursodiol and/or Denamarin, and broad-spectrum antibiotics. Nutritional support is critical to prevent/manage concurrent hepatic lipidosis, so appetite stimulants and/or, if indicated, feeding tube placement is also recommended.



Imaging performed by



Four Paws Animal Wellness Services, Inc.
pawsonography@gmail.com
530-786-8340



Clinical Sonography & Telectology
Educational Teleconsultation Services™

SonoPath

FOSTERING THE ART OF VETERINARY MEDICINE™

SonoPath.com info@sonopath.com 1.800.838.4268

PATIENT

Crystal Lee

SPECIES

Feline

BREED

DMH

SEX

FS

AGE

8 years 10 months

WEIGHT

4.14 kg

INTERPRETED BY

Beth Johnson, DVM
DACVIM

IMAGING PERFORMED BY

Loetitia Saint-Jacques,
LVT

HOSPITAL NAME

Four Paws Animal
Clinic

REFERRING VET

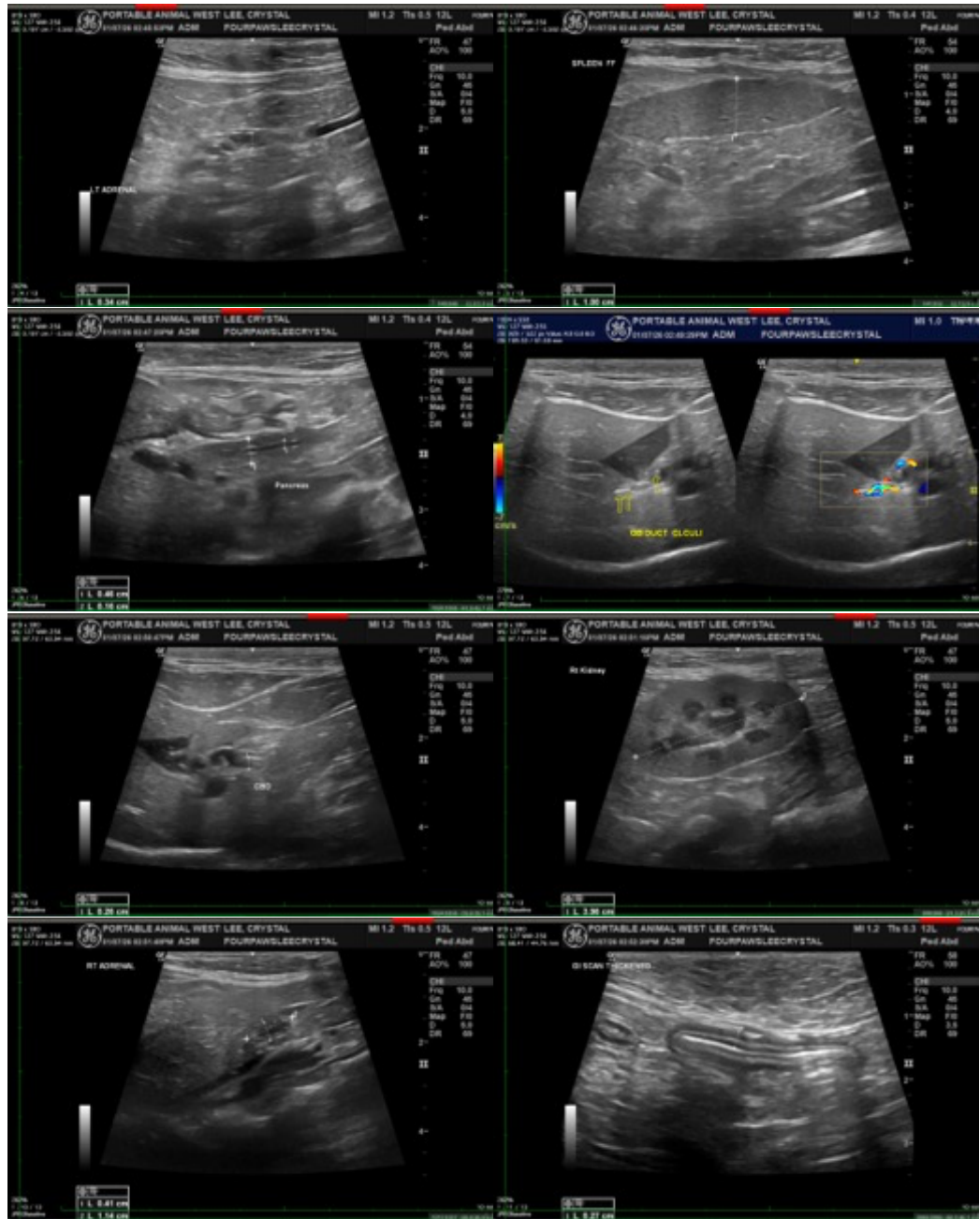
Dr. Susan Lester

INVOICE

11069

DATE

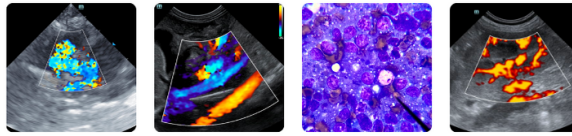
1/7/2026



Imaging
performed by



Four Paws Animal Wellness Sonography, Inc.
pawsonography@gmail.com
530-786-8340



Clinical Sonography & Telectology
Educational Teleconsultation Services™

SonoPath

FOSTERING THE ART OF VETERINARY MEDICINE™

SonoPath.com info@sonopath.com 1.800.838.4268

PATIENT

Crystal Lee

SPECIES

Feline

BREED

DMH

SEX

FS

AGE

8 years 10 months

WEIGHT

4.14 kg

INTERPRETED BY

Beth Johnson, DVM
DACVIM

**IMAGING
PERFORMED BY**

Loetitia Saint-Jacques,
LVT

HOSPITAL NAME

Four Paws Animal
Clinic

REFERRING VET

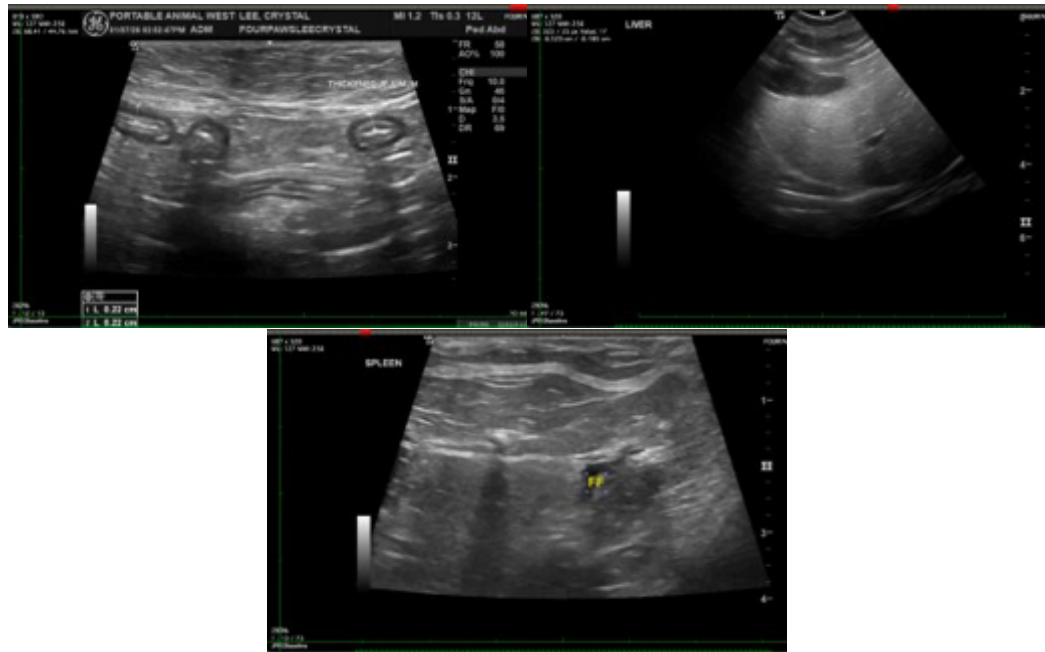
Dr. Susan Lester

INVOICE

11069

DATE

1/7/2026



The information and recommendations provided are based on the images presented by the referring veterinarian/sonographer. No evaluation can be communicated regarding pathology that was not visible in the image/video clips provided.

Thank you for this referral. If the clinical or image interpretation does not parallel your findings or if I can be of any further assistance please contact me.

Beth Johnson, DVM, DACVIM
info@sonopath.com