IMAGING PERFORMED BY
SVS Mobile Imaging MI 734 - 637 - 7711
svsimagingmi@gmail.com

SVS IMAGING

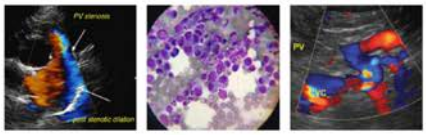

SonoPath
Clinical Sonography & Telecytology
EDUCATIONAL TELECONSULTATION SERVICES™
1-800-838-4268 info@sonopath.com SonoPath.com

PATIENT
Vinnie Noveck

SPECIES
Canine

BREED
Coton de Tulear

SEX
Neutered Male

AGE
9 Years

WEIGHT
15 Pounds

INTERPRETED BY
Beth Johnson, DVM DACVIM

IMAGING PERFORMED BY
Amy Mayhew, LVT

HOSPITAL NAME
SVS Imaging MI

REFERRING VET
DePorre Vet Hospital – Dr. DeHondt

INVOICE
44030

DATE
1/6/23

PRESENTING CLINICAL SIGNS

Chronic intermittent vomiting

Abnormal PE/Chem/CBC/UA Results: Grade IV/VI heart murmur. Exam otherwise unremarkable. CBC/Chem unremarkable.

ULTRASONOGRAPHIC EXAMINATION OF THE ABDOMEN

Urinary System

The urinary bladder is moderately distended with anechoic contents. No masses, inflammatory changes, echogenic sediment or cystoliths are observed. The urinary bladder, trigone and visible pelvic urethra are normal in thickness with a smooth mucosal surface.

Prostate is normal in size, echotexture and echogenicity for a neutered male.

The right kidney is normal in size (4.36 cm), shape and echogenicity. It has smooth peripheral margination. There is a normal 1:3 cortex to medulla ratio with appropriate corticomedullary distinction. There is no evidence of pyelectasia, mineral or infarcts observed. A vague hyperechoic band parallel to the corticomedullary border is present.

The left kidney is normal in size (4.29 cm), shape and echogenicity. It has smooth peripheral margination. There is a normal 1:3 cortex to medulla ratio with appropriate corticomedullary distinction. There is no evidence of pyelectasia, mineral or infarcts observed. A vague hyperechoic band parallel to the corticomedullary border is present.

Adrenal Glands

The right adrenal gland is normal in size (0.43 cm at the cranial pole and 0.49 cm at the caudal pole), shape and contour. Corticomedullary structure is unremarkable. Visible surrounding vasculature appears normal.

The left adrenal gland is normal in size (0.43 cm at the cranial pole and 0.38 cm at the caudal pole), shape and contour. Corticomedullary structure is unremarkable. Visible surrounding vasculature appears normal.

Spleen

The spleen is subjectively normal in size with a normal smooth capsular contour. Parenchyma is appropriately finely textured and homogenous with normal echogenicity relative to surrounding tissue (hyperechoic to liver). No focal nodules or masses are observed. Splenic vasculature appears normal.

Liver

The liver is subjectively normal in size with normal smooth curvilinear peripheral contour. Parenchyma is appropriately hypoechoic to the spleen in echogenicity and appropriately mildly coarse and homogenous in echotexture. No focal lesions are observed. Visible vasculature and biliary tree appear normal without distension or congestion.

The gallbladder is non-distended in size. The wall is smooth without visible thickening. Luminal contents are primarily anechoic. There is no evidence of cystic or common bile duct dilation.

Gastrointestinal

The stomach wall is normal in thickness (canine < 0.5 cm and feline < 0.4 cm) and layering. The lumen of the stomach is empty with no evidence of obstruction, foreign material or infiltrative disease. Pyloric outflow tract appears patent.

IMAGING PERFORMED BY
SVS Mobile Imaging MI 734 - 637 - 7711
svsimagingmi@gmail.com

SVS IMAGING

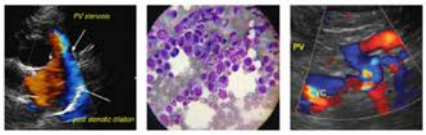

SonoPath
Clinical Sonography & Telecytology
EDUCATIONAL TELECONSULTATION SERVICES™
1-800-838-4268 info@sonopath.com SonoPath.com

PATIENT
Vinnie Noveck

SPECIES
Canine

BREED
Coton de Tulear

SEX
Neutered Male

AGE
9 Years

WEIGHT
15 Pounds

INTERPRETED BY
Beth Johnson, DVM DACVIM

IMAGING PERFORMED BY
Amy Mayhew, LVT

HOSPITAL NAME
SVS Imaging MI

REFERRING VET
DePorre Vet Hospital – Dr. DeHondt

INVOICE
44030

DATE
1/6/23

The visible small intestines are normal in wall thickness and layering (canine duodenum < 0.5 cm and feline duodenum < 0.4 cm; other < 0.3 cm). Small intestinal motility appears adequate (1-3 contractions per min). The lumen of the small intestine is empty with no evidence of obstruction, foreign material or infiltrative disease.

The visible colon is normal in wall thickness (< 0.2 cm) and layering. Contents are consistent with normal formed feces and gas.

Pancreas

The observed pancreas appears appropriately isoechoic to surrounding omental fat. The capsule is mildly irregular in shape. Parenchyma is mildly heterogenous and coarse. There is no visible pancreatic duct dilation. There is no evidence of active peripancreatic inflammation.

Free Abdomen

There is no evidence of free peritoneal effusion noted in these images.

The medial iliac lymph nodes are prominent in size with swollen capsular contour. Normal elongated shape (length to width ratio) is maintained. There is no loss of parenchymal detail.

ULTRASONOGRAPHIC FINDINGS

- **Vague bilateral medullary rim sign -** This finding is of unknown clinical significance and can be a normal variant, often idiopathic. Medullary rim sign can be present with renal disease including FIP, lymphoma, hypercalcemic nephropathy, Leptospirosis, tubular disease, other and should be interpreted in combination with other more specific indications of kidney disease such as isosthenuria, proteinuria, azotemia, etc. This is a common incidental finding in patients with diabetes mellitus.

- **Reactive medial iliac lymph nodes –** infiltrative neoplastic disease cannot be ruled out but is considered less likely.

INTERPRETATION OF THE FINDINGS & FURTHER RECOMMENDATIONS

In the face of reportedly normal lab work. This is a relatively unremarkable/normal abdomen without a visible ultrasonographic cause for the chronic vomiting. A normal ultrasound does not rule out gastrointestinal and/or pancreatic disease. Therefore, recommendations include:

A gastrointestinal malabsorption panel (including cobalamin, folate, TLI and PLI) to Texas A&M GI Laboratory is recommended for further evaluation of GI and pancreatic function.

A baseline cortisol is recommended. If baseline cortisol is less than 2, a full ACTH stimulation test is recommended to rule out hypoadrenocorticism.

In the meantime, empirical supportive/symptomatic medical management with antiemetics, gastroprotectants, a probiotic such as Visbiome or Proviable, empirical deworming with a 5-day course of Panacur, and if tolerated, transition in diet, beginning potentially with a hydrolyzed protein diet or moving on to a bland, easy to digest diet etc. based on trial and error patient response.

IMAGING PERFORMED BY
SVS Mobile Imaging MI 734 - 637 - 7711
svsimagingmi@gmail.com

SVS IMAGING

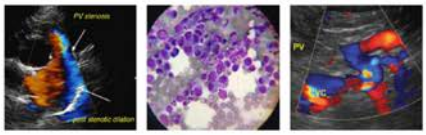

SonoPath
Clinical Sonography & Telecytology
EDUCATIONAL TELECONSULTATION SERVICES™
1-800-838-4268 info@sonopath.com SonoPath.com

PATIENT

Vinnie Noveck

SPECIES

Canine

BREED

Coton de Tulear

SEX

Neutered Male

AGE

9 Years

WEIGHT

15 Pounds

INTERPRETED BY

Beth Johnson, DVM
DACVIM

IMAGING PERFORMED BY

Amy Mayhew, LVT

HOSPITAL NAME

SVS Imaging MI

REFERRING VET

DePorre Vet Hospital –
Dr. DeHondt

INVOICE

44030

DATE

1/6/23

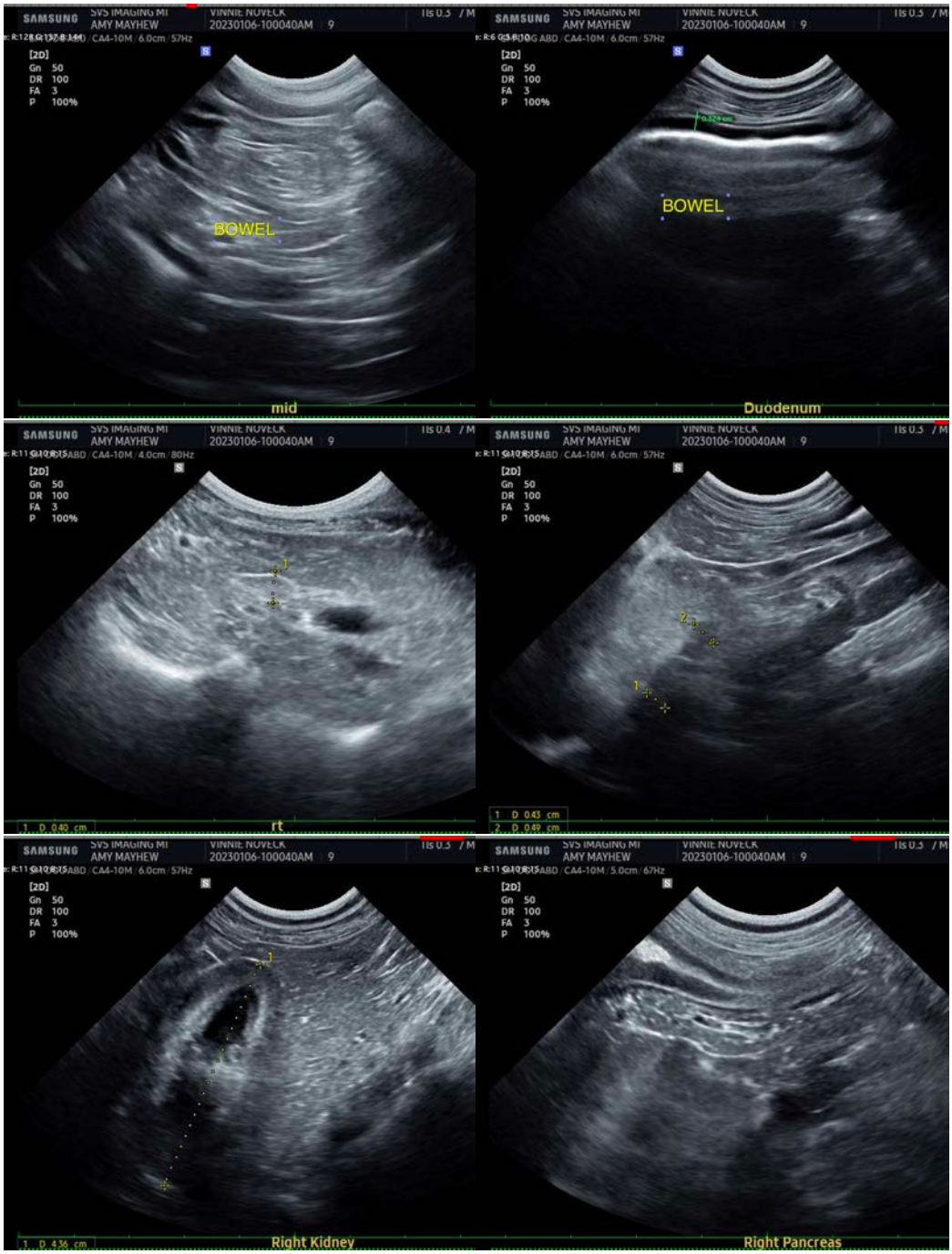

IMAGING PERFORMED BY
SVS Mobile Imaging MI 734 - 637 - 7711
svsimagingmi@gmail.com

SVS IMAGING

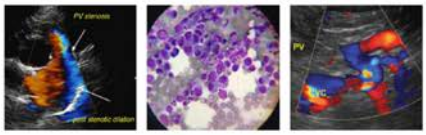

SonoPath
Clinical Sonography & Telecytology
EDUCATIONAL TELECONSULTATION SERVICES™
1-800-838-4268 info@sonopath.com SonoPath.com

PATIENT

Vinnie Noveck

SPECIES

Canine

BREED

Coton de Tulear

SEX

Neutered Male

AGE

9 Years

WEIGHT

15 Pounds

INTERPRETED BY

Beth Johnson, DVM DACVIM

IMAGING PERFORMED BY

Amy Mayhew, LVT

HOSPITAL NAME

SVS Imaging MI

REFERRING VET

DePorre Vet Hospital – Dr. DeHondt

INVOICE

44030

DATE

1/6/23

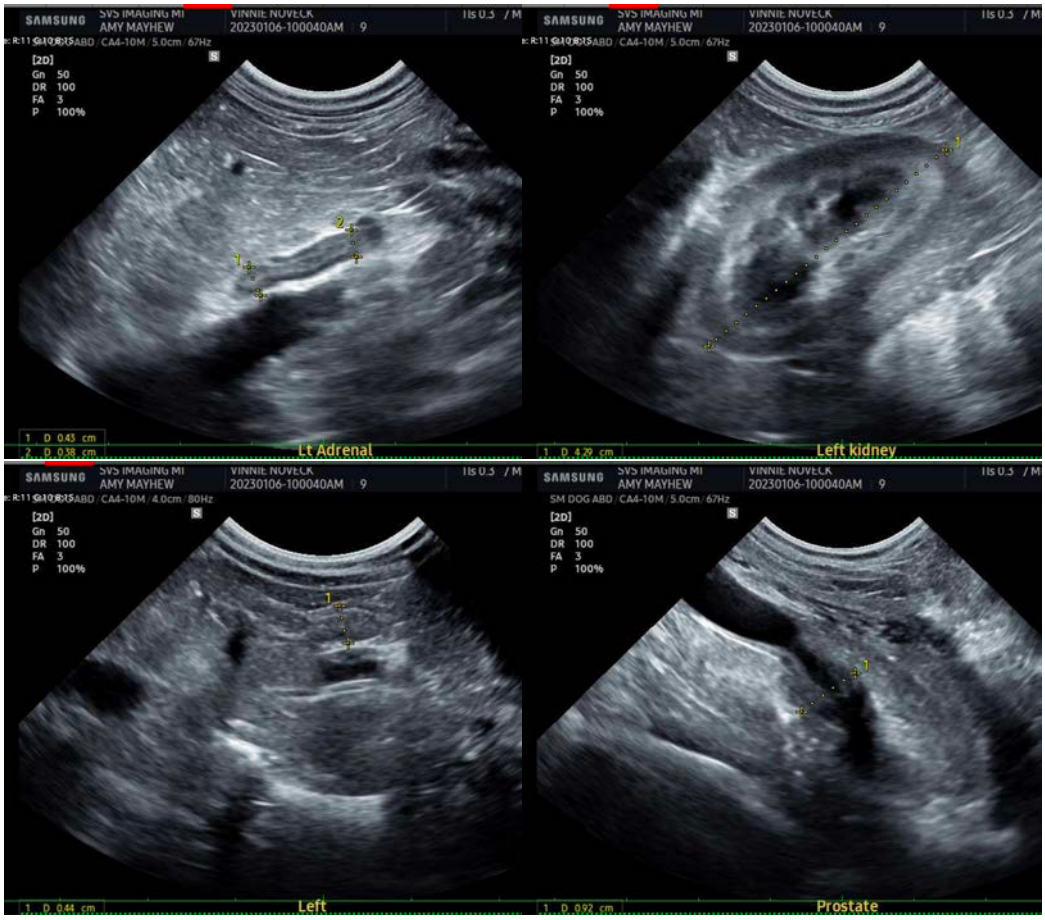

The information and recommendations provided are based on the images presented by the referring veterinarian/sonographer. No evaluation can be communicated regarding pathology that was not visible in the image/video clips provided.

Thank you for this referral. If the clinical or image interpretation does not parallel your findings or if I can be of any further assistance please contact me.

Beth Johnson, DVM, DACVIM
Beth.Johnson@sonopath.com