



PATIENT

Tide Freeborn

SPECIES

Canine

BREED

Schnauzer

SEX

Neutered Male

AGE

9 Years 6 Months

WEIGHT

9.7 kg

INTERPRETED BY

Beth Johnson, DVM
DACVIM

IMAGING PERFORMED BY

Dr. Jill Rankin

HOSPITAL NAME

Beddington Trail Vet

REFERRING VET

Dr. Diksha

INVOICE

35251

DATE

1/5/26

PRESENTING CLINICAL SIGNS

History: Tide presents with a chronic history of multiple bladder stones and a large bladder mass of undetermined origin, presenting for recurrent hematuria. A diagnostic ultrasound performed approximately one year ago in December 2024 first confirmed the presence of multiple bladder stones and a possible mass reported to occupy about 50% of the bladder. At that time, the mass was noted to be in an atypical location for a transitional cell carcinoma (TCC), though a BRAF test was still recommended. Surgery was considered high-risk due to the patient's age. A recent brief in-house ultrasound scan confirmed the mass and stones are still present. The primary differential diagnoses for the mass remain a bladder tumor such as a TCC or an inflammatory polyp. The patient presented recently for hematuria that occurred over two days. This is assessed to be secondary to the chronic urolithiasis and bladder mass, likely caused by mechanical irritation and ulceration of the bladder wall. The patient also had a past presentation in March for blood in the stool. The current plan is to repeat the ultrasound to assess the size of the mass and the burden of the uroliths, with a potential referral to internal medicine or CARE, as requested by the owner. The patient was recently prescribed a seven-day course of antibiotics.

ULTRASONOGRAPHIC EXAMINATION OF THE ABDOMEN

Urinary System

Urinary bladder is adequately distended with primarily anechoic contents and occasional echogenic nonshadowing debris, as well as multiple (4+) shadowing cystoliths, ranging in size between 0.3+ cm – 0.8 cm in diameter. Apical urinary bladder wall is diffusely thick with a hyperechoic and irregular mucosa, as well as 2 pedunculated masses, extending into the lumen of the bladder, measuring 2.3 cm ling x 0.66 cm thick, and 1.9 cm long x 0.8 cm thick. The trigone and visible pelvic urethra are normal in thickness with a smooth mucosal surface.

Prostate is normal in size, echotexture and echogenicity for a neutered male.

Left kidney is normal in size (4.74 cm), shape and echogenicity. It has smooth peripheral margination. There is a normal 1:3 cortex to medulla ratio with appropriate corticomedullary distinction. There is no evidence of pyelectasia, mineral or infarcts observed.

Right kidney is normal in size (4.8 cm), shape and echogenicity. It has smooth peripheral margination. There is a normal 1:3 cortex to medulla ratio with appropriate corticomedullary distinction. There is no evidence of pyelectasia, mineral or infarcts observed.

Adrenal Glands

The area of the left adrenal gland is examined without evident adrenal gland pathology, but it's difficult to full visualize/isolate for measurement.

Right adrenal gland is normal in size (0.5 cm at cranial pole and 0.5 cm at caudal pole), shape and overall architecture, echogenicity and echotexture. Visible surrounding vasculature appears normal.

Spleen

Spleen is subjectively normal in size with a normal smooth capsular contour. Parenchyma is appropriately finely textured and homogenous with normal echogenicity relative to surrounding tissue (hyperechoic to liver). No focal nodules or masses are observed. Splenic vasculature appears normal.



PATIENT

Tide Freeborn

SPECIES

Canine

BREED

Schnauzer

SEX

Neutered Male

AGE

9 Years 6 Months

WEIGHT

9.7 kg

INTERPRETED BY

Beth Johnson, DVM
DACVIM

IMAGING PERFORMED BY

Dr. Jill Rankin

HOSPITAL NAME

Beddington Trail Vet

REFERRING VET

Dr. Diksha

INVOICE

35251

DATE

1/5/26

Liver

Liver is subjectively enlarged with mildly irregular margins. Parenchyma is mildly heterogenous characterized by multiple poorly defined hypoechoic nodules within otherwise hyperechoic liver parenchyma. Visible vasculature and biliary tree appear normal without distension or congestion.

Gallbladder is moderately distended with anechoic bile as well as moderate suspended and gravity dependent echogenic debris. The wall is mildly thick, hyperechoic and irregular with subjectively benign polypoid changes. Infiltrative neoplasia cannot be ruled out but is considered less likely. There is no evidence of effusion or inflammation.

Gastrointestinal

The visible stomach wall is normal in thickness and layering. The lumen of the stomach is mildly distended with very echogenic reverberation artifact from intraluminal gas. There is no evidence of obstruction, foreign material or infiltrative disease; however, complete visualization of far wall is partially inhibited by gas. Pyloric outflow tract appears patent.

The visible small intestines are normal in wall thickness and layering. Small intestinal motility appears adequate (1-3 contractions per min). The lumen of the small intestine is mildly distended with very echogenic reverberation artifact from intraluminal gas. There is no evidence of obstruction, foreign material, or infiltrative disease; however, visualization is partially inhibited by gas.

The visible colon is normal in wall thickness (< 0.2 cm) and layering. Contents are consistent with normal formed feces and gas.

Pancreas

The pancreas that is observed appears appropriately isoechoic to surrounding omental fat. Visible capsule is smooth and normal in contour. Visible pancreatic parenchyma is homogenous and unremarkable. There is no visible pancreatic duct dilation. There is no evidence of active peripancreatic inflammation.

Free Abdomen

There is no visible free peritoneal effusion noted in these images.

There is no apparent pathologic lymphadenopathy noted in these images.

ULTRASONOGRAPHIC FINDINGS

Primary Findings

- The pedunculated urinary bladder masses could represent benign inflammatory changes, such as polypoid cystitis, especially given the concurrent cystoliths. Having said that, infiltrative uroepithelial neoplasia can't be ruled out without additional information.

Secondary Findings

- Mildly heterogenous liver- These changes are most consistent with benign processes such as nodular hyperplasia, steroid (vacuolar) hepatopathy, extramedullary hematopoiesis or possibly chronic inflammatory disease and less commonly infiltrative round cell or metastatic neoplasia.



PATIENT

Tide Freeborn

SPECIES

Canine

BREED

Schnauzer

SEX

Neutered Male

AGE

9 Years 6 Months

WEIGHT

9.7 kg

INTERPRETED BY

Beth Johnson, DVM
DACVIM

IMAGING PERFORMED BY

Dr. Jill Rankin

HOSPITAL NAME

Beddington Trail Vet

REFERRING VET

Dr. Diksha

INVOICE

35251

DATE

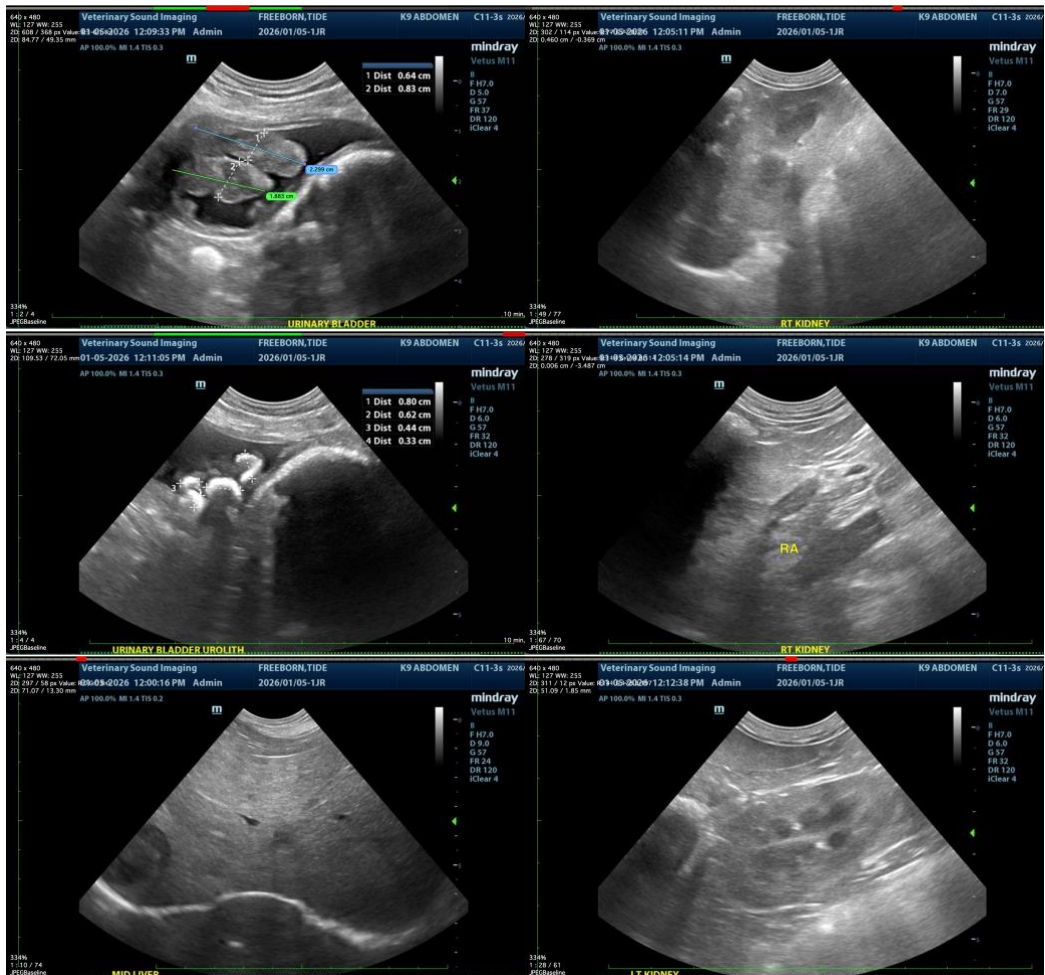
1/5/26

- Polypoid gallbladder hyperplasia- This change is most consistent with benign polypoid changes. Infiltrative neoplasia cannot be ruled out but is considered less likely.

INTERPRETATION OF THE FINDINGS & FURTHER RECOMMENDATIONS

Urinalysis and urine culture, if indicated based on urinalysis results, are recommended. Submission of urine to look for BRAF gene mutation, which is associated with urinary bladder/prostate cancer, could be considered. Other diagnostic options include traumatic catheterization, fine needle aspirate (with small risk of tumor seeding/trailing) or cystoscopy for further sampling. In the meantime, empirical therapy with a broad-spectrum antibiotic (or ideally an antibiotic based on culture and sensitivity results) as well as an anti-inflammatory (unless otherwise contraindicated based on patient co-morbidities) may begin to help alleviate clinical signs.

Pending results of above, three view thoracic radiographs are recommended for further assessment of cardio-pulmonary status as well as to further evaluate for any evidence of metastatic disease, if not recently evaluated.





PATIENT

Tide Freeborn

SPECIES

Canine

BREED

Schnauzer

SEX

Neutered Male

AGE

9 Years 6 Months

WEIGHT

9.7 kg

INTERPRETED BY

Beth Johnson, DVM
DACVIM

IMAGING PERFORMED BY

Dr. Jill Rankin

HOSPITAL NAME

Beddington Trail Vet

REFERRING VET

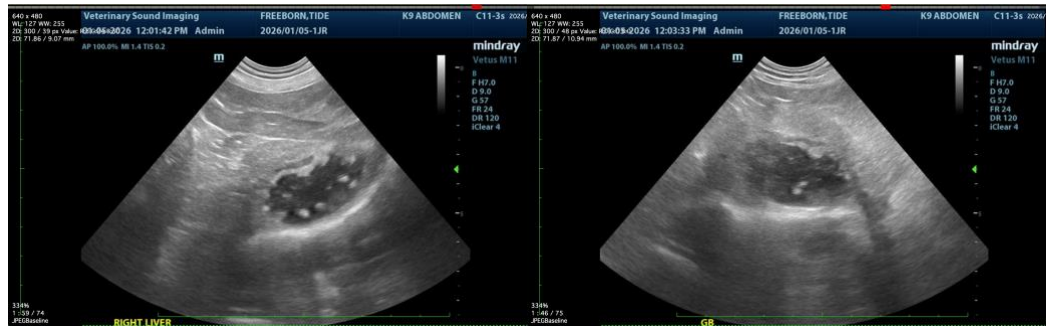Dr. Diksha

INVOICE

35251

DATE

1/5/26



The information and recommendations provided are based on the images presented by the referring veterinarian/sonographer. No evaluation can be communicated regarding pathology that was not visible in the image/video clips provided.

Thank you for this referral. If the clinical or image interpretation does not parallel your findings or if I can be of any further assistance please contact me.

Beth Johnson, DVM DACVIM

info@sonopath.com