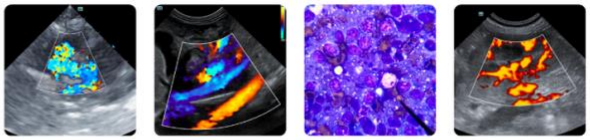

PATIENT
Margo Storm

SPECIES
Canine

BREED
Brittany Spaniel

SEX
Spayed Female

AGE
10 Years 4 Months

WEIGHT
42.2 Pounds

INTERPRETED BY
Beth Johnson, DVM, DACVIM (SAIM)

IMAGING PERFORMED BY
Dr. Lucas Budden

HOSPITAL NAME
Frontier VH

REFERRING VET
Dr. Lucas Budden

INVOICE
35252

DATE
1/5/26

PRESENTING CLINICAL SIGNS

History: Clinical signs: Chronic vomiting, recent worsening History: History of chronic vomiting. Seen on 12/12/25 for wellness and owner noticed increase in vomiting (once every 2-3 days). Chronic vomiting has been present a couple years. Appetite normal, stable weight, no diarrhea. History of recurrent UTI's and bladder stones. Had abdominal x-rays in August of 2025 and no stones were noted. Current medications: Fortiflora Bravecto, Sentinel Trazodone and Butorphanol to facilitate imaging,

Abnormal PE/Chem/CBC/UA Results: Physical exam: BCS 5/9, multiple SC/round lumbs on ventral abdomen, mild dental tartar, peripheral LNs normal, normal exam otherwise Lab work: senior labs 12/12/25 ALT high 126 Magnesium high 2.8 Triglyceride high 681 Hemolysis 4+ Lipemia 4+ Remainder of chemistry normal CBC normal Thyroid normal 1.4 USG 1.022 Quiet sediment Fecal negative Accu Plex all negative GI panel pending.

ULTRASONOGRAPHIC EXAMINATION OF THE ABDOMEN

Urinary System

Urinary bladder is adequately distended with anechoic contents. No masses, inflammatory changes, echogenic sediment or cystoliths are observed. The urinary bladder, trigone and visible pelvic urethra are normal in thickness with a smooth mucosal surface.

Left kidney is normal in size (5.98 cm), shape and echogenicity. It has smooth peripheral margination. There is a normal 1:3 cortex to medulla ratio with appropriate corticomedullary distinction. There is no evidence of pyelectasia, mineral or infarcts observed. A subtle hyperechoic band parallel to the corticomedullary border is present

Right kidney is normal in size (5.68 cm), shape and echogenicity. It has smooth peripheral margination. There is a normal 1:3 cortex to medulla ratio with appropriate corticomedullary distinction. There is no evidence of pyelectasia, mineral or infarcts observed. A subtle hyperechoic band parallel to the corticomedullary border is present.

Adrenal Glands

Left adrenal gland is normal in size (0.57 cm at cranial pole and 0.7 cm at caudal pole), shape and overall architecture, echogenicity and echotexture. Visible surrounding vasculature appears normal.

Right adrenal gland is normal in size (1.2 cm at cranial pole and 0.67 cm at caudal pole), shape and overall architecture, echogenicity and echotexture. Visible surrounding vasculature appears normal.

Spleen

Spleen is subjectively normal in size (1.5 cm thick at the hilus) with a normal smooth capsular contour. Parenchyma is appropriately finely textured and homogenous with normal echogenicity relative to surrounding tissue (hyperechoic to liver). A subtle discrete homogenous hyperechoic density is noted near the hilus. Additionally, an approximately 0.5 cm x 0.6 cm in diameter hypo- to anechoic non-capsule-disrupting nodule is noted near the cranial aspect of the spleen. splenic vasculature appears normal.

Liver

PATIENT
Margo Storm

SPECIES
Canine

BREED
Brittany Spaniel

SEX
Spayed Female

AGE
10 Years 4 Months

WEIGHT
42.2 Pounds

INTERPRETED BY
Beth Johnson, DVM, DACVIM (SAIM)

IMAGING PERFORMED BY
Dr. Lucas Budden

HOSPITAL NAME
Frontier VH

REFERRING VET
Dr. Lucas Budden

INVOICE
35252

DATE
1/5/26

Liver is subjectively normal in size with normal smooth curvilinear peripheral contour. Parenchyma is appropriately hypoechoic to the spleen in echogenicity and appropriately mildly coarse and homogenous in echotexture. No focal lesions are observed. Visible vasculature and biliary tree appear normal without distension or congestion.

Gallbladder is non-distended in size. The wall is smooth without visible thickening. Luminal contents are primarily anechoic. There is no evidence of cystic or common bile duct dilation.

Gastrointestinal

The visible stomach wall is normal in thickness and layering. The lumen of the stomach is empty with no evidence of obstruction, foreign material or infiltrative disease. Pyloric outflow tract appears patent.

The visible small intestines are normal in wall thickness and layering. Small intestinal motility appears adequate (1-3 contractions per min). The lumen of the small intestine is empty with no evidence of obstruction, foreign material or infiltrative disease.

The visible colon is normal in wall thickness (< 0.2 cm) and layering. Contents are consistent with normal formed feces and gas.

Pancreas

The observed pancreas appears appropriately isoechoic to surrounding omental fat. The capsule is mildly irregular in shape. Parenchyma is mildly heterogenous and coarse. There is no visible pancreatic duct dilation. There is no evidence of active peripancreatic inflammation.

Free Abdomen

There is no visible free peritoneal effusion noted in these images.

The mesenteric lymph nodes are prominent in size with swollen capsular contour. Normal elongated shape (length to width ratio) is maintained. There is no loss of parenchymal detail.

ULTRASONOGRAPHIC FINDINGS

Primary Findings

- Subtle bilateral medullary rim sign- This finding is of unknown clinical significance and can be a normal variant, often idiopathic. Medullary rim sign can be present with renal disease including lymphoma, hypercalcemic nephropathy, Leptospirosis, tubular disease, other and should be interpreted in combination with other more specific indications of kidney disease such as isosthenuria, proteinuria, azotemia, etc. This is a common incidental finding in patients with diabetes mellitus.
- Age-related pancreatic remodeling- Mild irregularities are consistent with benign age-related change. Low-grade smoldering chronic pancreatitis cannot be ruled out and should be suspected in the face of appropriate clinical signs.
- Mildly reactive mesenteric lymphadenopathy- infiltrative neoplastic disease cannot be ruled out but is considered less likely.

Secondary Findings

PATIENT

Margo Storm

SPECIES

Canine

BREED

Brittany Spaniel

SEX

Spayed Female

AGE

10 Years 4 Months

WEIGHT

42.2 Pounds

INTERPRETED BY

Beth Johnson, DVM, DACVIM (SAIM)

IMAGING PERFORMED BY

Dr. Lucas Budden

HOSPITAL NAME

Frontier VH

REFERRING VET

Dr. Lucas Budden

INVOICE

35252

DATE

1/5/26

- Hypo- to anechoic splenic nodule- likely represents a benign lesion such as a cyst, hematoma, nodular hyperplasia, extramedullary hematopoiesis, etc., however while considered less likely, infiltrative neoplasia can mimic benign lesions and cannot be ruled out.
- Hyperechoic splenic nodule- most consistent with benign myelolipoma. Other differentials such as fibrosis or calcification caused by old hematoma or infarct, chronic inflammation, granulomatous disease or metastatic disease cannot be ruled out, but are considered less likely.

INTERPRETATION OF THE FINDINGS & FURTHER RECOMMENDATIONS

As is reportedly already pending, a gastrointestinal malabsorption panel (including cobalamin, folate, TLI and PLI) to Texas A&M GI Laboratory is recommended for further evaluation of GI and pancreatic function.

A baseline cortisol is recommended. If baseline cortisol is less than 2, a full ACTH stimulation test is recommended to rule out hypoadrenocorticism.

In the meantime, supportive/symptomatic medical management of clinical signs is recommended, including anti-emetics, gastroprotectants (+/- sucralfate, especially with any history of hematemesis), an appetite stimulant and fluid therapy if indicated, etc.

Additionally, empirical deworming with a 5-day course of Panacur is recommended as is a full course of empirical Helicobacter triple therapy.

Finally, if tolerated, a transition in diet could be considered, based on trial-and-error response with some options to consider including a gastrointestinal biome diet vs a hydrolyzed protein diet (sometimes several trials with different brands are necessary) vs an easy to digest, bland or low-fat diet vs other.

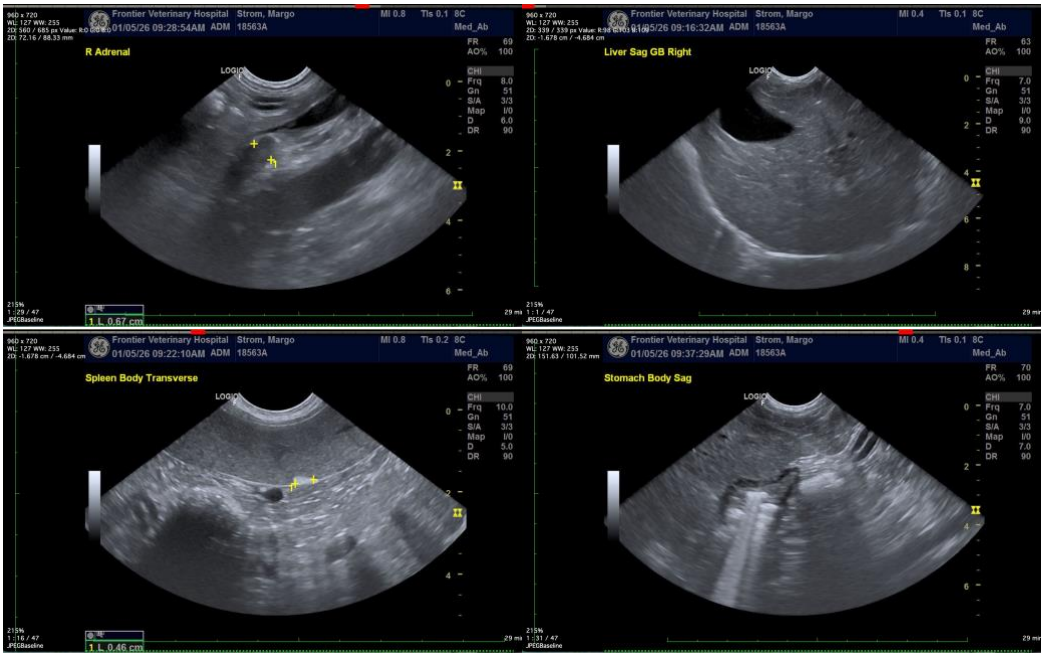

SonoPath
FOSTERING THE ART OF VETERINARY MEDICINE™

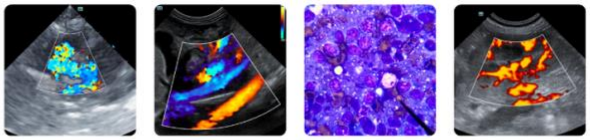

Clinical Sonography & Telecytology
Educational Teleconsultation Services™

SonoPath.com info@sonopath.com 1.800.838.4268

PATIENT

Margo Storm

SPECIES

Canine

BREED

Brittany Spaniel

SEX

Spayed Female

AGE

10 Years 4 Months

WEIGHT

42.2 Pounds

INTERPRETED BY

Beth Johnson, DVM, DACVIM (SAIM)

IMAGING PERFORMED BY

Dr. Lucas Budden

HOSPITAL NAME

Frontier VH

REFERRING VET

Dr. Lucas Budden

INVOICE

35252

DATE

1/5/26

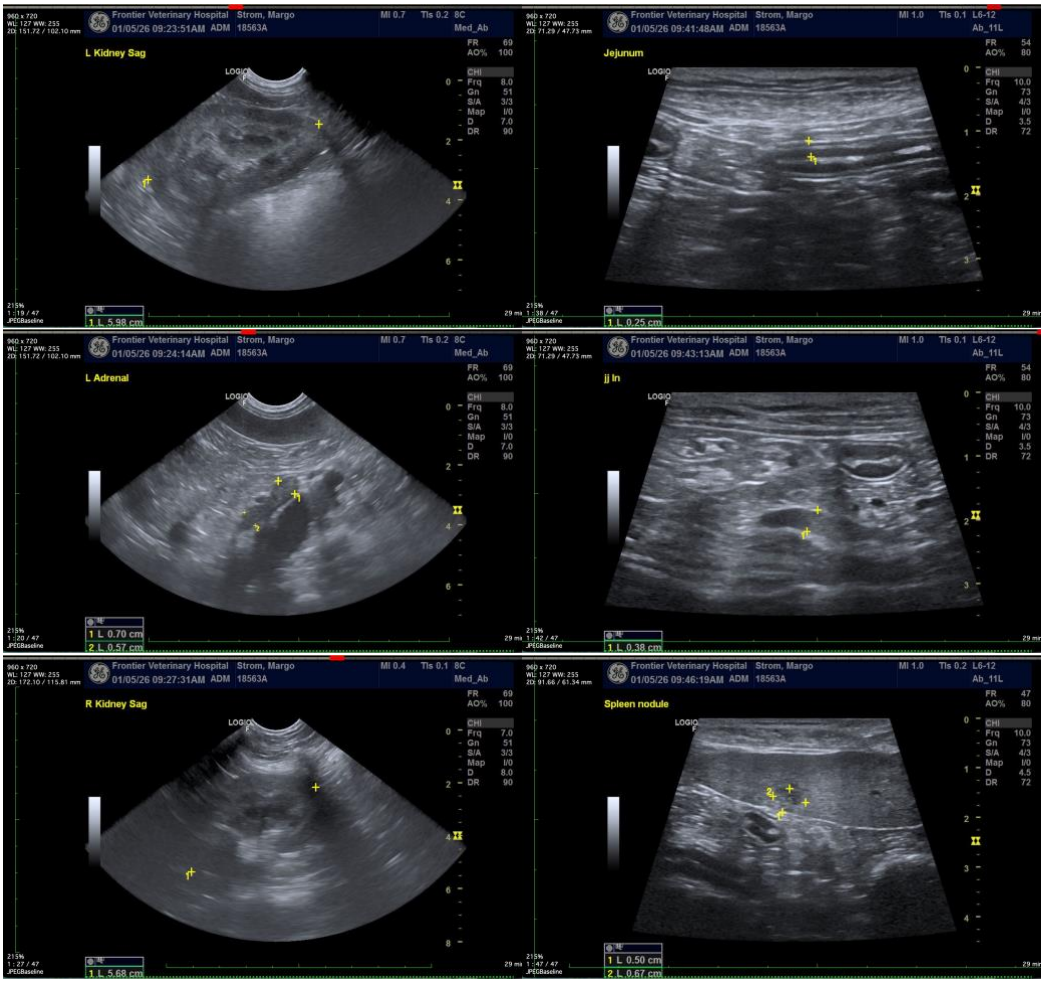

The information and recommendations provided are based on the images presented by the referring veterinarian/sonographer. No evaluation can be communicated regarding pathology that was not visible in the image/video clips provided.

Thank you for this referral. If the clinical or image interpretation does not parallel your findings or if I can be of any further assistance, please contact me.

Beth Johnson, DVM DACVIM

info@sonopath.com