

**PATIENT**

Mitzy Lafferty

SPECIES

Feline

BREED

DSH

SEX

Spayed Female

AGE

14 Years

WEIGHT

8 lb 12 oz.

INTERPRETED BYBeth Johnson, DVM
DACVIM**IMAGING PERFORMED BY**

Amy Mayhew, LVT

HOSPITAL NAME

SVS Imaging MI

REFERRING VETMilford VC –
Dr. Emery Engers**INVOICE**

43965

DATE

1/5/23

PRESENTING CLINICAL SIGNS

Weight loss patient not eating as well and crouching more
 Abnormal PE/Chem/CBC/UA Results: UA- NSF CBC + Chem 17 + TT4 - NSF

ULTRASONOGRAPHIC EXAMINATION OF THE ABDOMEN**Urinary System**

The urinary bladder is moderately distended with anechoic contents. No masses, inflammatory changes, echogenic sediment or cystoliths are observed. The urinary bladder, trigone and visible pelvic urethra are normal in thickness with a smooth mucosal surface.

Kidneys are overall normal in size and shape with smooth peripheral margination. A normal 1:3 cortex to medulla ratio is maintained. The medulla and cortices are uniform in texture with some mild increased cortical echogenicity and mild loss of corticomedullary distinction, expected in this age patient. There is no evidence of pyelectasia, mineral or infarcts observed. The right kidney measures 3.6 cm. The left kidney measures 3.83 cm.

Adrenal Glands

The right adrenal gland is normal in size (0.34 cm), shape and contour. Corticomedullary structure is unremarkable. Visible surrounding vasculature appears normal.

The left adrenal gland is normal in size (0.41 cm), shape and contour. Corticomedullary structure is unremarkable. Visible surrounding vasculature appears normal.

Spleen

The spleen is subjectively normal in size with a normal smooth capsular contour. Parenchyma is appropriately finely textured and homogenous with normal echogenicity relative to surrounding tissue (hyperechoic to liver). No focal nodules or masses are observed. Splenic vasculature appears normal.

Liver

The liver is subjectively normal in size with normal smooth curvilinear peripheral contour. Parenchyma is appropriately hypoechoic to the spleen in echogenicity and appropriately mildly coarse and homogenous in echotexture. No focal lesions are observed. Visible vasculature and biliary tree appear normal without distension or congestion.

The gallbladder is non-distended in size. The wall is smooth without visible thickening. Luminal contents are primarily anechoic. There is no evidence of cystic or common bile duct dilation.

Gastrointestinal

The stomach wall is normal in thickness (canine < 0.5 cm and feline < 0.4 cm) and layering. The lumen of the stomach is empty with no evidence of obstruction, foreign material or infiltrative disease. Pyloric outflow tract appears patent.

The visible small intestine demonstrates areas of mildly thick muscularis layer relative to mucosa (disruption of the normal 1:3 muscularis:mucosa ratio). Small intestinal submucosa is slightly irregular, thick and hyperechoic, without evident loss of layering appreciated. The lumen is empty with no evidence of obstruction or foreign material.

The visible colon is normal in wall thickness (< 0.2 cm) and layering. Contents are consistent with normal formed feces and gas.

IMAGING PERFORMED BY

SVS Mobile Imaging MI 734-637-7711
svsimagingmi@gmail.com



EDUCATIONAL TELECONSULTATION SERVICES™
1-800-838-4268 info@sonopath.com SonoPath.com

PATIENT

Mitzy Lafferty

SPECIES

Feline

BREED

DSH

SEX

Spayed Female

AGE

14 Years

WEIGHT

8 lb 12 oz.

INTERPRETED BY

Beth Johnson, DVM
DACVIM

IMAGING PERFORMED BY

Amy Mayhew, LVT

HOSPITAL NAME

SVS Imaging MI

REFERRING VET

Milford VC –
Dr. Emery Engers

INVOICE

43965

DATE

1/5/23

Pancreas

Pancreas is prominent in size with swollen irregular contour. Parenchyma is heterogenous characterized by hyperechoic tissue remodeling intermixed with ill-defined hypoechoic nodules. There is no visible pancreatic duct dilation. There is no evidence of active peripancreatic inflammation.

Free Abdomen

There is no evidence of free peritoneal effusion noted in these images.

There is no apparent lymphadenopathy noted in these images.

PRIMARY FINDINGS

- **Pancreatic nodular hyperplasia** – Infiltrative neoplasia cannot be ruled out but is considered less likely. Chronic smoldering pancreatitis cannot be definitively ruled out.
- **Inflammatory bowel disease (IBD) pattern** – Thick muscularis has been reported with infiltrative bowel disease including both benign inflammatory disease as well as infiltrative neoplasia such as lymphoma. No aggressive lymphadenopathy, loss of layering, etc. is noted to make lymphoma more probable, but lymphoma cannot be definitively ruled out without tissue sampling.

SECONDARY FINDINGS

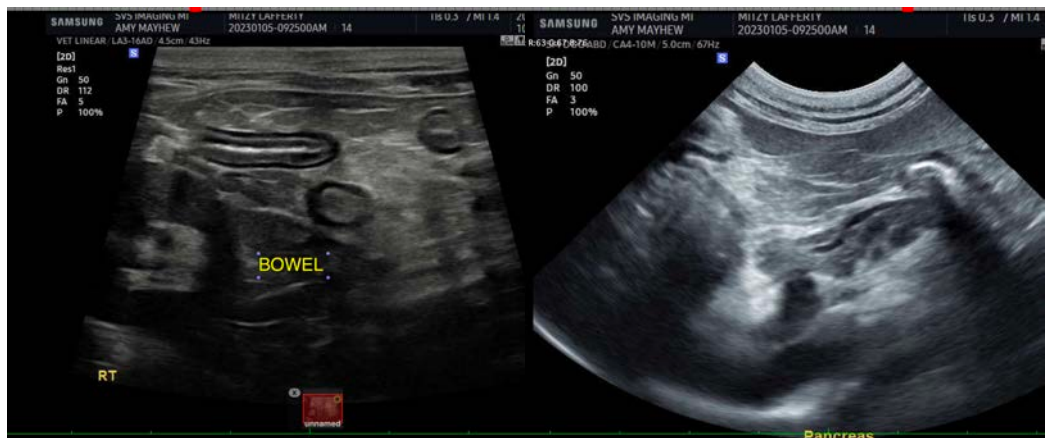- Age related kidney change

INTERPRETATION OF THE FINDINGS & FURTHER RECOMMENDATIONS

A gastrointestinal malabsorption panel (including cobalamin, folate, TLI and PLI) to Texas A&M GI Laboratory is recommended for further evaluation of GI and pancreatic function.

Ideally, biopsies of the GI tract, being sure to include ileum if possible, are recommended to definitively diagnose and therefore manage the infiltrative bowel disease.

If biopsies cannot be obtained, empirical therapies could include diet change, empirical deworming with a 5 day course of Panacur, cobalamin supplementation (unless cobalamin level is evaluated and supplementation is not warranted) and prednisolone (if not contraindicated based on patient contraindications, co-morbidities, etc.).



IMAGING PERFORMED BY

SVS Mobile Imaging MI 734 - 637 - 7711
svsimagingmi@gmail.com



PATIENT

Mitzy Lafferty

SPECIES

Feline

BREED

DSH

SEX

Spayed Female

AGE

14 Years

WEIGHT

8 lb 12 oz.

INTERPRETED BY

Beth Johnson, DVM
DACVIM

IMAGING PERFORMED BY

Amy Mayhew, LVT

HOSPITAL NAME

SVS Imaging MI

REFERRING VET

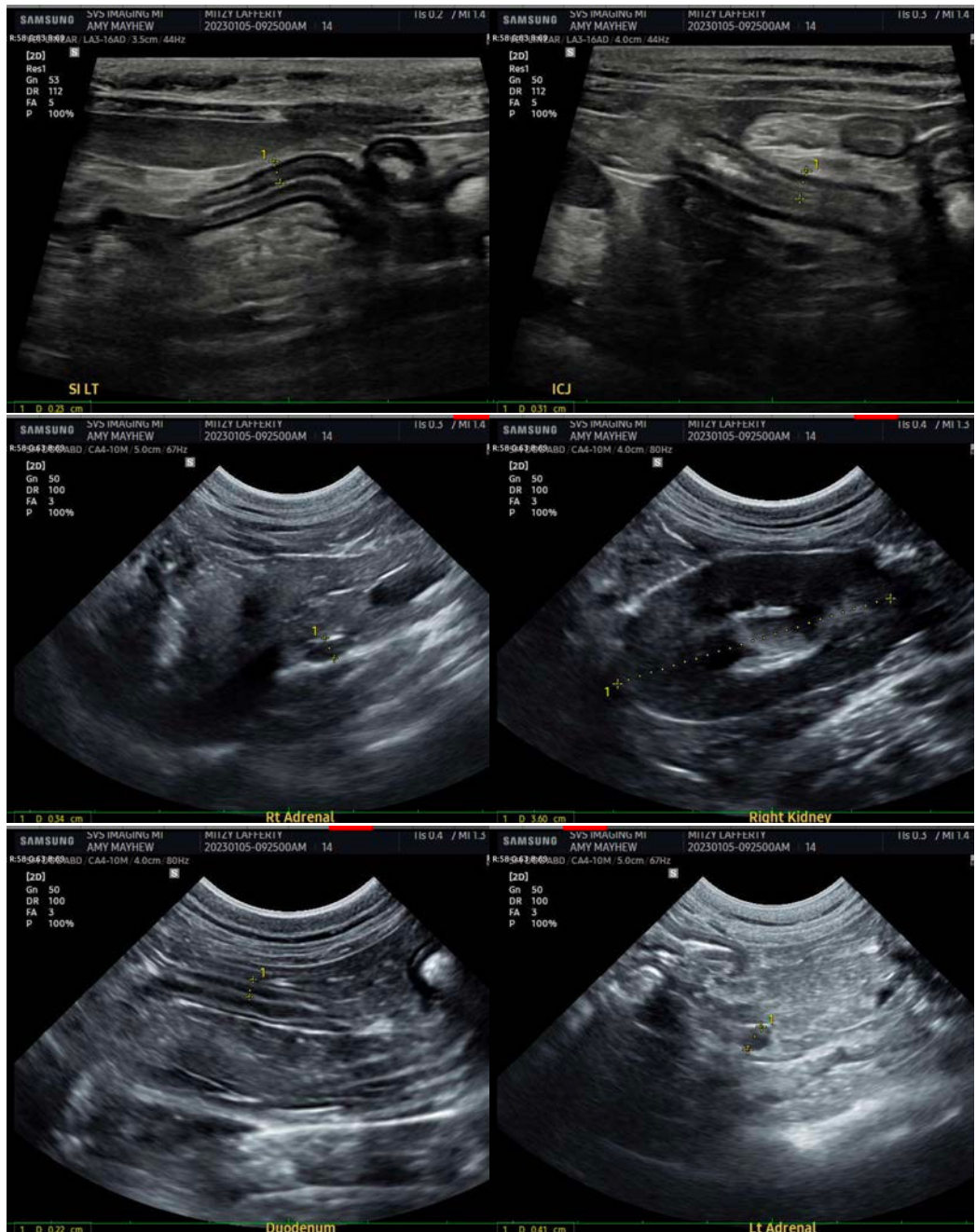
Milford VC -
Dr. Emery Engers

INVOICE

43965

DATE

1/5/23



IMAGING PERFORMED BY

SVS Mobile Imaging MI 734-637-7711
svsimagingmi@gmail.com



EDUCATIONAL TELECONSULTATION SERVICES™
1-800-838-4268 info@sonopath.com SonoPath.com

PATIENT

Mitzy Lafferty

SPECIES

Feline

BREED

DSH

SEX

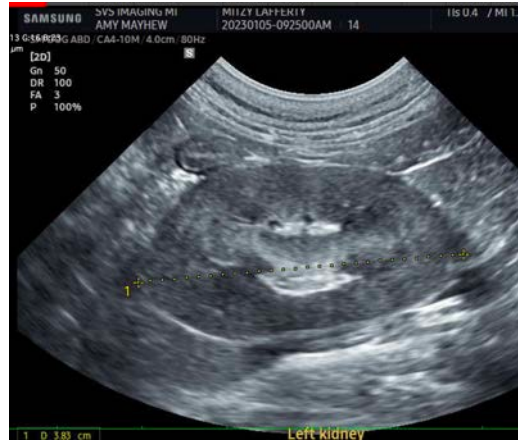Spayed Female

AGE

14 Years

WEIGHT

8 lb 12 oz.



The information and recommendations provided are based on the images presented by the referring veterinarian/sonographer. No evaluation can be communicated regarding pathology that was not visible in the image/video clips provided.

Thank you for this referral. If the clinical or image interpretation does not parallel your findings or if I can be of any further assistance please contact me.

Beth Johnson, DVM, DACVIM
Beth.Johnson@sonopath.com

INTERPRETED BY

Beth Johnson, DVM
DACVIM

IMAGING PERFORMED BY

Amy Mayhew, LVT

HOSPITAL NAME

SVS Imaging MI

REFERRING VET

Milford VC –
Dr. Emery Engers

INVOICE

43965

DATE

1/5/23