

**DATE PRESENTING CLINICAL SIGNS**

1/5/23 Not eating for multiple days at a time, will eat one meal sporadically. Owners were unsure if defecating. P also vomited undigested food when dropped off 1/3/23. Owners noted no vomiting at home.

**PATIENT**

Louie Rozanski

Current Medications: None.

Radiographs: 12/29/22 and 1/3/2023 both showed food in stomach, when compared Dr. Jones noted movement of feces.

**SPECIES**

Canine

Date of Previous IntraPet Ultrasound: No previous.

Sedation: Torbugesic IV.

Stat Report: Not requested.

Imaging Performed By: Stephanie Warga RDCS, RVT.

**BREED**

Bichon Frise

**ULTRASONOGRAPHIC EXAMINATION OF THE ABDOMEN****SEX**

Neutered Male

**Urinary System**

The urinary bladder is moderately distended with anechoic contents. No masses or inflammatory changes. A small shadowing cystolith is noted measuring 0.25 cm. The urinary bladder, trigone and visible pelvic urethra are normal in thickness with a smooth mucosal surface.

**AGE**

4/13/19

Prostate is normal in size, echotexture and echogenicity for a neutered male.

**WEIGHT**

17.8 Pounds

The right kidney is normal in size (4.48 cm), shape and echogenicity. It has smooth peripheral margination. There is a normal 1:3 cortex to medulla ratio with appropriate corticomedullary distinction. There is no evidence of pyelectasia, mineral or infarcts observed.

The left kidney is normal in size (4.47 cm), shape and echogenicity. It has smooth peripheral margination. There is a normal 1:3 cortex to medulla ratio with appropriate corticomedullary distinction. There is no evidence of pyelectasia, mineral or infarcts observed.

**INTERPRETED BY**Beth Johnson, DVM  
DACVIM**Adrenal Glands**

The right adrenal gland is normal in size (1.54 cm long x 0.45 cm at the cranial pole and 0.42 cm at the caudal pole), shape and contour. Corticomedullary structure is unremarkable. Visible surrounding vasculature appears normal.

**HOSPITAL NAME**

AH at Southgate

The left adrenal gland is normal in size (1.84 cm long x 0.32 cm at the cranial pole and 0.41 cm at the caudal pole), shape and contour. Corticomedullary structure is unremarkable. Visible surrounding vasculature appears normal.

**REFERRING VET**

Dr. Jones

**Spleen**

The spleen is subjectively normal in size with a normal smooth capsular contour. Parenchyma is appropriately finely textured and homogenous with normal echogenicity relative to surrounding tissue (hyperechoic to liver). No focal nodules or masses are observed. Splenic vasculature appears normal.

**INVOICE**

44002

**Liver**

The liver is subjectively normal in size with normal smooth curvilinear peripheral contour. Parenchyma is appropriately hypoechoic to the spleen in echogenicity and appropriately mildly coarse and homogenous in echotexture. No focal lesions are observed. Visible vasculature and biliary tree appear normal without distension or congestion.

Gallbladder is moderately distended with anechoic bile as well as very mild suspended and gravity dependent echogenic debris. The wall is smooth without visible thickening. There is no evidence of cystic or CBD dilation. There is no evidence of effusion or inflammation.

### ***Gastrointestinal***

The visible stomach wall is normal in thickness and layering. The lumen of the stomach is mildly distended with very echogenic reverberation artifact from intraluminal gas. There is no evidence of obstruction, foreign material or infiltrative disease; however, complete visualization of far wall is partially inhibited by gas. Pyloric outflow tract appears patent.

The visible small intestines are normal in wall thickness and layering (canine duodenum < 0.5 cm and feline duodenum < 0.4 cm; other < 0.3 cm). Small intestinal motility appears adequate (1-3 contractions per min). The lumen of the small intestine is empty with no evidence of obstruction, foreign material or infiltrative disease.

The visible colon is normal in wall thickness (< 0.2 cm) and layering. Contents are consistent with normal formed feces and gas.

### ***Pancreas***

The pancreatic parenchyma is appropriately isoechoic to surrounding tissue. Visible capsule is smooth and normal in contour. There is no visible pancreatic duct dilation. There is no evidence of active peripancreatic inflammation.

### ***Free Abdomen***

There is no evidence of free peritoneal effusion noted in these images.

The mesenteric lymph nodes are prominent in size with swollen capsular contour. Normal elongated shape (length to width ratio) is maintained. There is no loss of parenchymal detail.

## **ULTRASONOGRAPHIC FINDINGS**

- Small urinary bladder cystoliths
- **Very mild gallbladder debris** - Cholecystic debris is of unknown clinical significance. It can be seen with biliary stasis from fasting or illness. Cholecystic debris is not necessarily related to hepatobiliary disease. Echogenic bile is most commonly an incidental finding in dogs and should be interpreted in combination with clinical signs such as nausea, inappetence, cranial abdominal discomfort and/or laboratory changes such as increased ALP and/or increased Tbili.
- **Reactive mesenteric lymph nodes** - infiltrative neoplastic disease cannot be ruled out but is considered less likely.

## **INTERPRETATION OF THE FINDINGS & FURTHER RECOMMENDATIONS**

If not recently evaluated, a full general metabolic health screen is recommended in the form of a CBC/Chem panel, electrolytes, and urinalysis.

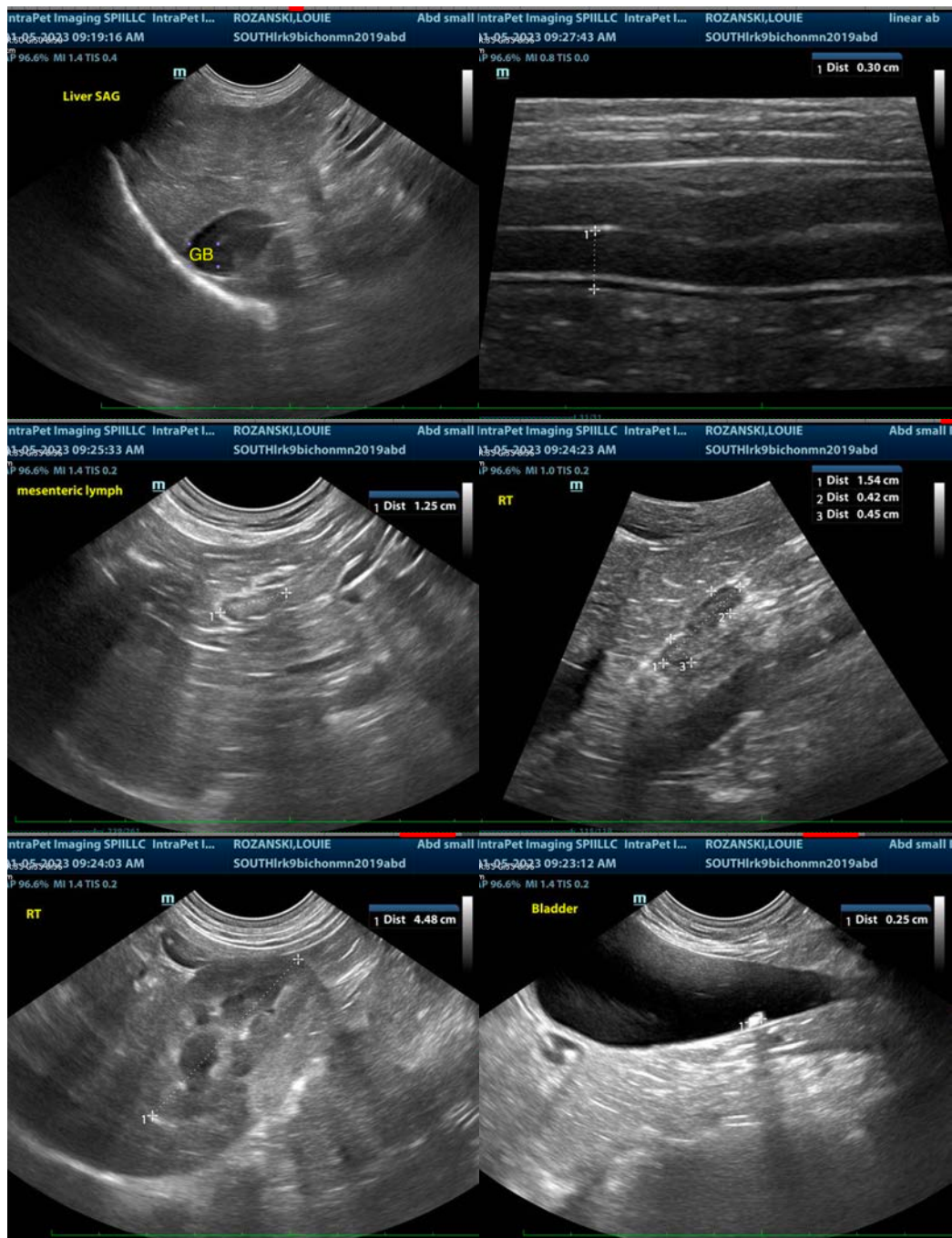
There is no visible evidence in these images of an extrahepatic portosystemic shunt. However, given patient signalment combined with the presence of a cystoliths, especially if supported by chemistry panel results, bile acids should be considered.

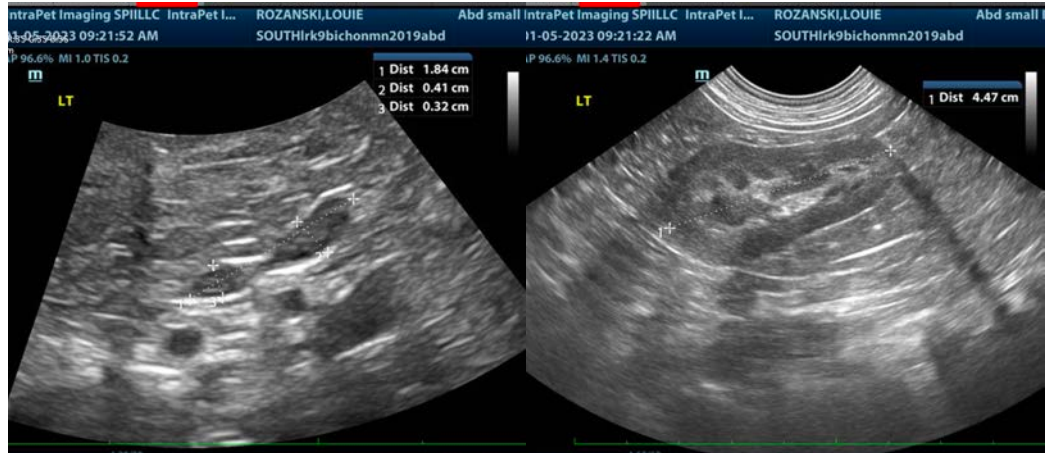A baseline cortisol is recommended. If baseline cortisol is less than 2, a full ACTH stimulation test is recommended to rule out hypoadrenocorticism.

A gastrointestinal malabsorption panel (including cobalamin, folate, TLI and PLI) to Texas A&M GI Laboratory is recommended for further evaluation of GI and pancreatic function. If this patient suffers from diarrhea,

additionally a fecal exam would be recommended, as well as a fecal enteropathogen PCR panel to Texas A&M GI Laboratory.

In the meantime, empirical deworming with a 5-day course of Panacur is recommended, as is supportive/symptomatic management in the form of antiemetics and gastroprotectants, as well as an appetite stimulant to maintain appetite until an underlying diagnosis is obtained.





The information and recommendations provided are based on the images presented by the referring veterinarian/sonographer. No evaluation can be communicated regarding pathology that was not visible in the image/video clips provided.

Thank you for this referral. If the clinical or image interpretation does not parallel your findings or if I can be of any further assistance please contact me.

**Beth Johnson, DVM, DACVIM**  
Beth.Johnson@sonopath.com