

**DATE PRESENTING CLINICAL SIGNS**

1/4/23 PU/PD/PP for the past 2 months. Recent weight loss. Grossly normal PE.

**PATIENT**

Current Medications: None.  
Lab Results: low total T4, low wbc, consistent with previous bloodwork but slightly lower on latest sample  
Date of Previous IntraPet Ultrasound: No previous.  
Sedation: Declined.

Roxy Fink

**SPECIES**

Stat Report: Not requested.  
Imaging Performed By: Rachel Brillhart, RDMS.

Canine

**ULTRASONOGRAPHIC EXAMINATION OF THE ABDOMEN****BREED**

Boxer X

**Urinary System**

The urinary bladder is moderately distended with anechoic contents. No masses, inflammatory changes, echogenic sediment or cystoliths are observed. The urinary bladder, trigone and visible pelvic urethra are normal in thickness with a smooth mucosal surface.

**SEX**

Spayed Female

The right kidney is normal in size (6.42 cm), shape and echogenicity. It has smooth peripheral margination. There is a normal 1:3 cortex to medulla ratio with appropriate corticomedullary distinction. There is no evidence of pyelectasia, mineral or infarcts observed.

**AGE**

12/6/12

The left kidney is normal in size (6.34 cm), shape and echogenicity. It has smooth peripheral margination. There is a normal 1:3 cortex to medulla ratio with appropriate corticomedullary distinction. There is no evidence of pyelectasia, mineral or infarcts observed.

**WEIGHT**

46.8 Pounds

**Adrenal Glands**

Adrenal glands are mildly plump/swollen in size. Normal shape and contour are maintained without evidence of capsular invasion. Corticomedullary structure is unremarkable. Visible surrounding vasculature appears normal. The right adrenal gland measures 3.08 cm long x 0.91 cm at the cranial pole and 0.85 cm at the caudal pole. The left adrenal gland measures 2.46 cm long x 0.79 cm at the cranial pole and 0.88 cm at the caudal pole.

**INTERPRETED BY**

Beth Johnson, DVM  
DACVIM

**HOSPITAL NAME**

Stevenson Village VH

**Spleen**

Spleen is subjectively large in size with a mildly swollen but smooth capsule. Parenchyma is normal and homogenous in echogenicity and echotexture. No focal nodules or masses are observed. Splenic vasculature appears normal.

**REFERRING VET**

Dr. Feinberg

**Liver**

The liver is subjectively normal in size with normal smooth curvilinear peripheral contour. Parenchyma is appropriately hypoechoic to the spleen in echogenicity and appropriately mildly coarse and homogenous in echotexture. No focal lesions are observed. Visible vasculature and biliary tree appear normal without distension or congestion.

**INVOICE**

43923

The gallbladder is non-distended in size. The wall is smooth without visible thickening. Luminal contents are primarily anechoic. There is no evidence of cystic or common bile duct dilation.

**Gastrointestinal**

The visible stomach wall is normal in thickness and layering. The stomach is moderately distended with echogenic non-shadowing luminal contents and gas consistent with normal ingesta. There is no evidence of obstruction, foreign material or infiltrative disease. However, given the reported history of fasting, delayed gastric emptying could be considered. Soft (cloth) fluid absorbing foreign material is considered less likely but

cannot be definitively ruled out. If clinical signs are consistent (vomiting, etc.), recommendations include supportive medical care, 24 hours fasting and re-image.

The visible small intestines are normal in wall thickness and layering (canine duodenum < 0.5 cm and feline duodenum < 0.4 cm; other < 0.3 cm). Small intestinal motility appears adequate (1-3 contractions per min). The lumen of the small intestine is empty with no evidence of obstruction, foreign material or infiltrative disease.

The visible colon is normal in wall thickness (< 0.2 cm) and layering. Contents are consistent with normal formed feces and gas.

### ***Pancreas***

The pancreatic parenchyma is appropriately isoechoic to surrounding tissue. Visible capsule is smooth and normal in contour. There is no visible pancreatic duct dilation. There is no evidence of active peripancreatic inflammation.

### ***Free Abdomen***

There is no evidence of free peritoneal effusion noted in these images.

There is no apparent lymphadenopathy noted in these images.

## **ULTRASONOGRAPHIC FINDINGS**

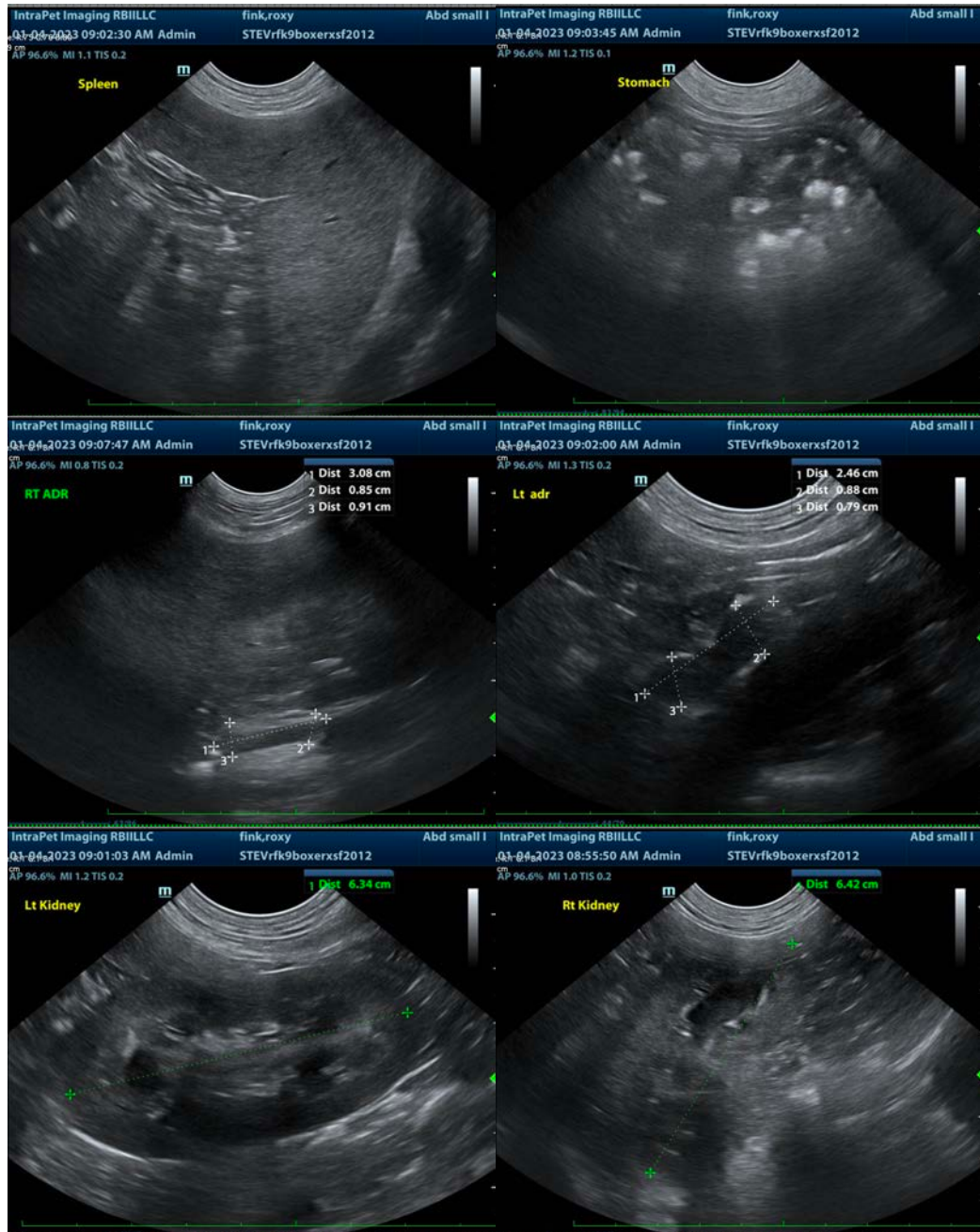
- **Mild bilateral adrenomegaly** – consistent with adrenal hyperplasia secondary to pituitary dependent hyperadrenocorticism vs stress or normal variant. Interpret in combination with clinical signs of hyperadrenocorticism.
- **Hypersplenism** – can be associated with congestion caused by sedation (if sedated) but can also be associated with diffuse infiltrative disease. Both benign conditions such as extramedullary hematopoiesis, lymphoid hyperplasia, as well as infiltrative neoplastic diseases such as round cell neoplasia should be considered.

## **INTERPRETATION OF THE FINDINGS & FURTHER RECOMMENDATIONS**

Given this patient's reported polyuria, polydipsia, polyphagia, and mild adrenomegaly, hyperadrenocorticism could be present. However, hyperadrenocorticism does not typically result in the reported weight loss and/or leukopenia. Therefore, initial recommendations included comprehensive infectious disease testing (given the leukopenia) as well as a fine needle aspirate of the spleen, if patient's coagulation status is appropriate.

A gastrointestinal malabsorption panel (including cobalamin, folate, TLI and PLI) to Texas A&M GI Laboratory is recommended for further evaluation of GI and pancreatic function.

Ultimately, in addition to looking up the weight loss, testing for hyperadrenocorticism in the form of a low-dose Dexamethasone suppression test could be considered. However, it is not recommended in the face of concurrent illness due to false positive results.



The information and recommendations provided are based on the images presented by the referring veterinarian/sonographer. No evaluation can be communicated regarding pathology that was not visible in the image/video clips provided.

Thank you for this referral. If the clinical or image interpretation does not parallel your findings or if I can be of any further assistance please contact me.

Beth Johnson, DVM, DACVIM  
Beth.Johnson@sonopath.com