

**DATE PRESENTING CLINICAL SIGNS**

1/4/23 Weight loss, poor appetite, history of chronic bronchitis being treated with inhaled steroid.

**PATIENT**

Chip Ratliff

Current Medications: Flovent BID for the past 6 months, Cerenia and Doxycycline started 12/31/22.  
Lab Results: Mild azotemia, Globulin has been elevating since beginning of the year and is now at 6.9. Low albumin 1.8, Elevated Ca, Low BG. USG 1.018, neg for proteinuria.

Date of Previous IntraPet Ultrasound: No previous.

Sedation: Declined.

**SPECIES**

Canine

Stat Report: Not requested.

Imaging Performed By: Rachel Brillhart, RDMS.

**BREED**

Shih Tzu

**ULTRASONOGRAPHIC EXAMINATION OF THE ABDOMEN****Urinary System**

Urinary bladder is adequately distended. It has a normal uniform wall thickness. Contents include primarily anechoic fluid with occasional echogenic non-shadowing debris, most consistent with exfoliated cells, mucous and/or small blood clots. Additionally, mineral/sand debris and possibly small cystoliths are noted. Both sterile inflammation as well as urinary tract infection can also present with echogenic debris. No masses are observed. The trigone and visible pelvic urethra are normal in thickness with a smooth mucosal surface.

**AGE**

7/14/07

Prostate is normal in size, echotexture and echogenicity for a neutered male.

**WEIGHT**

15.12 Pounds

Kidneys are overall normal in size and shape with smooth peripheral margination. A normal 1:3 cortex to medulla ratio is maintained. The medulla and cortices are uniform in texture with some mild increased cortical echogenicity and mild loss of corticomedullary distinction, expected in this age patient. There is no evidence of pyelectasia or infarcts observed. Non-obstructive areas of mineralization/nephroliths are noted. An approximately 1.0 cm cortical cyst is visualized in the medial aspect of the left kidney. The right kidney measures 4.43 cm. The right kidney measures 4.21 cm.

**INTERPRETED BY**Beth Johnson, DVM  
DACVIM**Adrenal Glands**

Adrenal glands are plump/swollen in size. Normal shape and contour are maintained without evidence of capsular invasion. Some parenchymal heterogeneity is present, likely a normal age variant. A hyperechoic nodule is noted in the mid left adrenal gland. Visible surrounding vasculature appears normal. The right adrenal gland measures 2.52 cm long x 1.06 cm at the cranial pole and 0.85 cm at the caudal pole. The left adrenal gland measures 2.12 cm long x 0.69 cm at the cranial pole and 0.55 cm at the caudal pole.

**HOSPITAL NAME**

Stevenson Village VH

**REFERRING VET**

Dr. Feinberg

**Spleen**

The spleen is subjectively normal in size with a normal smooth capsular contour. Parenchyma is appropriately finely textured and homogenous with normal echogenicity relative to surrounding tissue (hyperechoic to liver). No focal nodules or masses are observed. Splenic vasculature appears normal.

**INVOICE**

43924

**Liver**

Liver is subjectively enlarged with mildly irregular margins. Parenchyma is heterogenous characterized by multiple poorly defined hypoechoic nodules within otherwise hyperechoic liver parenchyma. Visible vasculature and biliary tree appear normal without distension or congestion.

The gallbladder is non-distended in size. The wall is smooth without visible thickening. Luminal contents are primarily anechoic. There is no evidence of cystic or common bile duct dilation.

### ***Gastrointestinal***

The visible stomach wall is normal in thickness and layering. The lumen of the stomach is mildly distended with echogenic non-shadowing luminal contents and gas consistent with normal ingesta. There is no evidence of obstruction, foreign material or infiltrative disease. Pyloric outflow tract appears patent.

The visible small intestines are normal in wall thickness and layering (canine duodenum < 0.5 cm and feline duodenum < 0.4 cm; other < 0.3 cm). Small intestinal motility appears adequate (1-3 contractions per min). The lumen of the small intestine is empty with no evidence of obstruction, foreign material or infiltrative disease.

The visible colon is normal in wall thickness (< 0.2 cm) and layering. Contents are consistent with normal formed feces and gas.

### ***Pancreas***

The observed pancreas is prominent (enlarged) in size, hypoechoic to surrounding tissue and irregular in shape with a swollen undulating contour. Enhanced hyperechoic ill-defined surrounding fat is noted.

### ***Free Abdomen***

There is no evidence of free peritoneal effusion noted in these images.

There is no apparent lymphadenopathy noted in these images.

## **PRIMARY FINDINGS**

- **Bilateral adrenomegaly** – consistent with adrenal hyperplasia secondary to pituitary dependent hyperadrenocorticism vs stress or normal variant. Interpret in combination with clinical signs of hyperadrenocorticism.
- **Hyperechoic adrenal nodule (left adrenal)** – Differentials include primary adrenal cortical adenoma or adenocarcinoma, pheochromocytoma, myelolipoma, adrenal hyperplasia secondary to pituitary disease or metastatic disease. Ultrasound alone cannot differentiate between functional and non-functional nodules and/or between benign and malignant disease. Small nodules without other evidence of abdominal disease (to suggest metastatic disease) and/or clinical signs (to suggest adrenal disease) are most often incidental and should be monitored.
- **Heterogenous Liver** – These changes are most consistent with benign processes such as nodular hyperplasia, steroid (vacuolar) hepatopathy, extramedullary hematopoiesis or possibly chronic inflammatory disease and less commonly infiltrative round cell or metastatic neoplasia.
- Acute pancreatitis
- Urinary bladder debris with mineral sand and possibly small cystoliths

## **SECONDARY FINDINGS**

- Age related kidney changes with mild non-obstructive nephrolithiasis bilaterally and a left cortical cyst

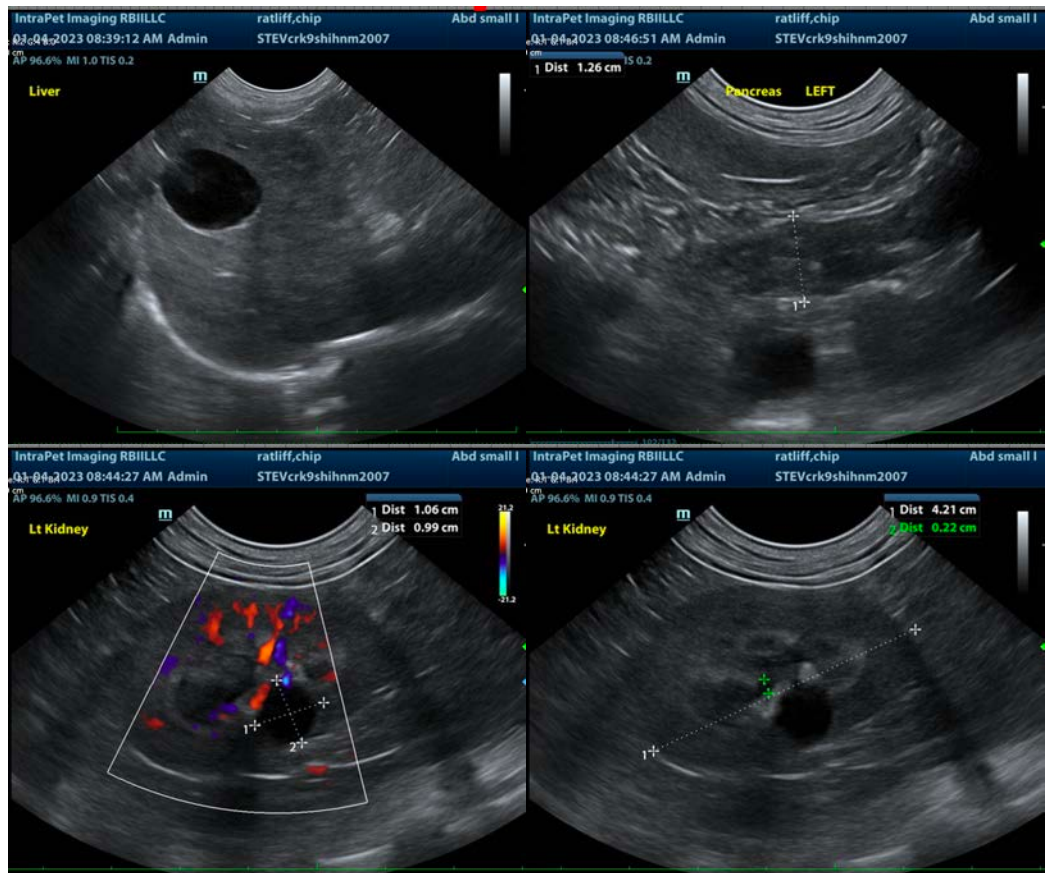
## **INTERPRETATION OF THE FINDINGS & FURTHER RECOMMENDATIONS**

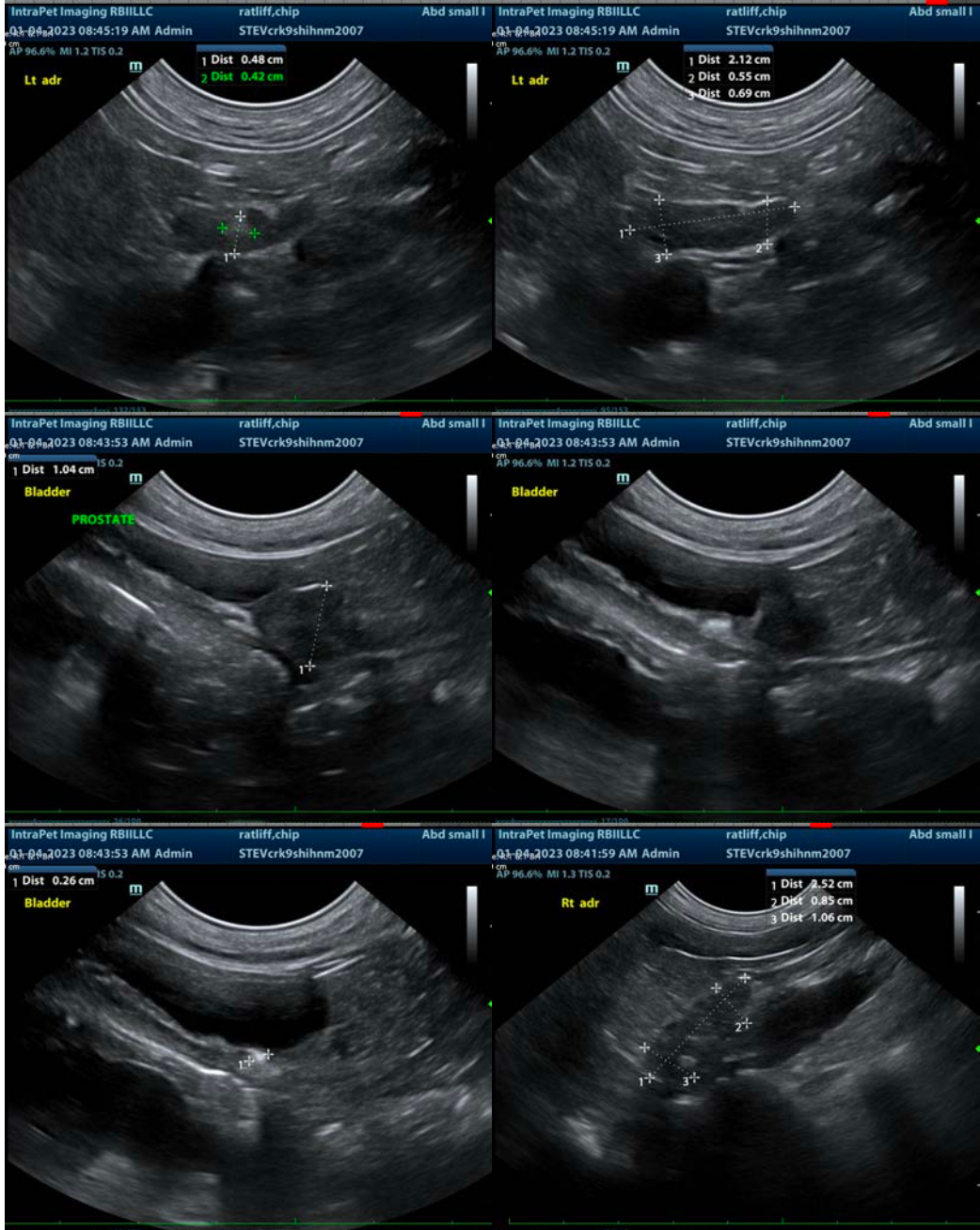
Some of this patient's clinical signs and laboratory changes could be secondary to pancreatitis. Therefore, a gastrointestinal malabsorption panel (including cobalamin, folate, TLI and PLI) to Texas A&M GI Laboratory is recommended for further evaluation of GI and pancreatic function.

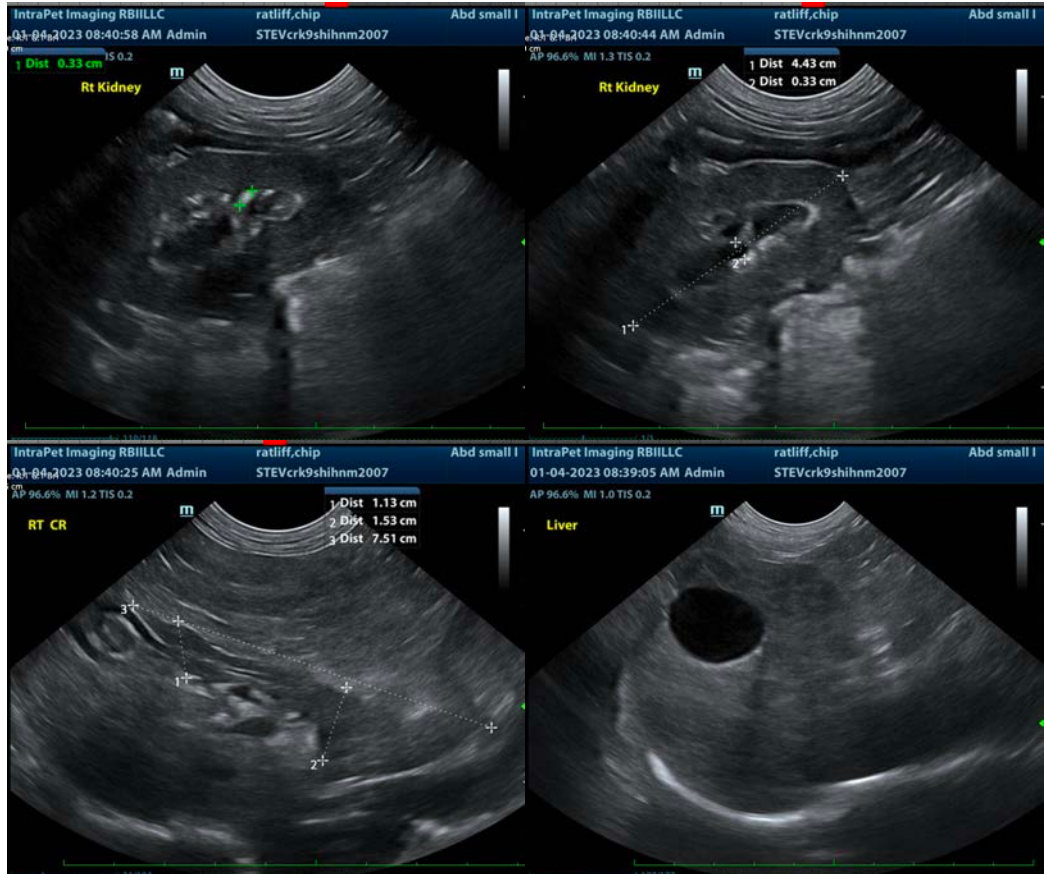
Medical management of pancreatitis with antiemetics, gastroprotectants, appetite stimulants and nutritional support as needed, pain management if indicated, broad-spectrum antibiotics, +/- fluid therapy if necessary, etc. is recommended, as is transition (if tolerated and when appetite returns to normal) to a low fat diet. However, additional diagnostic recommendations given the hypercalcemia, etc. include a malignancy panel to include PTH, PTHrP, and ionized calcium.

A baseline cortisol is recommended. If baseline cortisol is less than 2, a full ACTH stimulation test is recommended to rule out hypoadrenocorticism. Hypoadrenocorticism is unlikely, given the appearance of the adrenal glands, but testing is indicated based on clinical signs and reported laboratory results.

If another diagnosis is not obtained, and laboratory changes don't improve with management of pancreatitis, etc., due to the hypoalbuminemia, hypoglycemia, etc., bile acid testing would also be recommended if bilirubin is normal.







The information and recommendations provided are based on the images presented by the referring veterinarian/sonographer. No evaluation can be communicated regarding pathology that was not visible in the image/video clips provided.

Thank you for this referral. If the clinical or image interpretation does not parallel your findings or if I can be of any further assistance please contact me.

**Beth Johnson, DVM, DACVIM**  
Beth.Johnson@sonopath.com