SonoPath
Clinical Sonography & Telecytology

EDUCATIONAL TELECONSULTATION SERVICES™

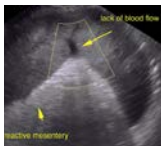
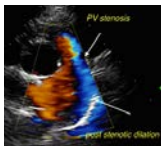
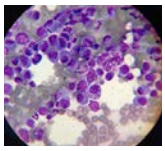
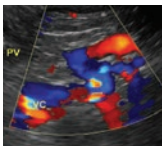

SonoPath.com
1-800-838-4268 info@sonopath.com

PATIENT

Pearl Bell

SPECIES

Feline

BREED

DSH

SEX

Spayed Female

AGE

4 Years 6 Months

WEIGHT

4.9 Pounds

INTERPRETED BY

Beth Johnson, DVM
DACVIM

HOSPITAL NAME

VCA Blairstown AH

REFERRING VET

Dr. Clegg

INVOICE NUMBER

33958

DATE

1/4/22

PRESENTING CLINICAL SIGNS

Suspected hepatic lipidosis, anorexic, weight loss. Current meds: Cerenia, Metronidazole, Cefovecin, 0.5ml sq Vit K inj. just prior to scan.
Abnormal PE/Chem/CBC/UA Results: Elevated ALP, ALT, Tbili, USG 1.056, hematuria.

ULTRASONOGRAPHIC EXAMINATION OF THE ABDOMEN

Urinary System

Urinary bladder is moderately distended with anechoic contents. No masses, inflammatory changes, echogenic sediment or cystoliths are observed. The urinary bladder, trigone and visible pelvic urethra are normal in thickness with a smooth mucosal surface.

Right kidney is normal in size (3.56 cm), shape and echogenicity. It has smooth peripheral margination. There is a normal 1:3 cortex to medulla ratio with appropriate corticomedullary distinction. There is no evidence of pyelectasia, mineral or infarcts observed.

Left kidney is normal in size (3.49 cm), shape and echogenicity. It has smooth peripheral margination. There is a normal 1:3 cortex to medulla ratio with appropriate corticomedullary distinction. There is no evidence of pyelectasia, mineral or infarcts observed.

Adrenal Glands

Right adrenal gland is normal in size (0.26 cm thick), shape and contour. Corticomedullary structure is unremarkable. Visible surrounding vasculature appears normal.

Left adrenal gland is normal in size (0.26 cm thick), shape and contour. Corticomedullary structure is unremarkable. Visible surrounding vasculature appears normal.

Spleen

Spleen is subjectively normal in size with a normal smooth capsular contour. Parenchyma is appropriately finely textured and homogenous with normal echogenicity relative to surrounding tissue (hyperechoic to liver). No focal nodules or masses are observed. Splenic vasculature appears normal.

Liver

Liver is subjectively enlarged. Margins are smooth but round. It has a normal homogenous echotexture. Parenchyma is diffusely hyperechoic characterized by less prominent than normal portal vein walls and increased echogenicity relative to the spleen. No focal lesions are observed. Visible vasculature and biliary tree appear normal without distension or congestion.

Gallbladder is non-distended in size. The wall is smooth without visible thickening. Luminal contents are primarily anechoic. The cystic duct is slightly tortuous, but measures within normal limits.

Gastrointestinal

The stomach wall is normal in thickness (canine < 0.5 cm and feline < 0.4 cm) and layering. The lumen of the stomach is empty with no evidence of obstruction, foreign material or infiltrative disease. Pyloric outflow tract appears patent.

The visible small intestines are normal in wall thickness and layering (canine duodenum < 0.5 cm and feline duodenum < 0.4 cm; other < 0.3 cm). Small intestinal motility appears adequate (1-3

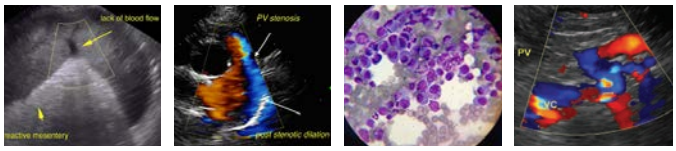

SonoPath.com
1-800-838-4268 info@sonopath.com

PATIENT
Pearl Bell

SPECIES
Feline

BREED
DSH

SEX
Spayed Female

AGE
4 Years 6 Months

WEIGHT
4.9 Pounds

INTERPRETED BY
Beth Johnson, DVM DACVIM

HOSPITAL NAME
VCA Blairstown AH

REFERRING VET
Dr. Clegg

INVOICE NUMBER
33958

DATE
1/4/22

contractions per min). The lumen of the small intestine is empty with no evidence of obstruction, foreign material or infiltrative disease.

The visible colon is normal in wall thickness (< 0.2 cm) and layering. Contents are consistent with normal formed feces and gas.

Pancreas

Pancreatic parenchyma is appropriately isoechoic to surrounding tissue. Visible capsule is smooth and normal in contour. There is no visible pancreatic duct dilation. There is no evidence of active peripancreatic inflammation.

Free Abdomen

There is no evidence of peritoneal effusion. There is no apparent lymphadenopathy.

ULTRASONOGRAPHIC FINDINGS

- Hyperechoic hepatomegaly – consistent with benign hepatic lipidosis. Infiltrative disease such as amyloidosis or neoplasia, such as mast cell tumor or less likely, lymphoma, is also possible.

INTERPRETATION OF THE FINDINGS & FURTHER RECOMMENDATIONS

Recommendations include a gastrointestinal malabsorption panel to include TLI, PLI, folate and cobalamin to further assess any underlying gastrointestinal dysfunction that may have predisposed the inappetence and consequent most likely hepatic lipidosis. Other recommendations include urinalysis (already reportedly pending), followed by a urine culture if indicated based on urinalysis results

The reportedly already pending fine needle aspirate of the liver is recommended, and pending cytology results, appetite stimulants are recommended. If they do not work to stimulant the patient's appetite, placement of a feeding tube would be recommended to begin nutritional management of likely hepatic lipidosis.

Other therapeutic recommendations besides feeding management include liver protectants such as Denamarin +/- empirical antibiotics in case of mild concurrent suppurative process such as hepatitis/cholangiohepatitis.

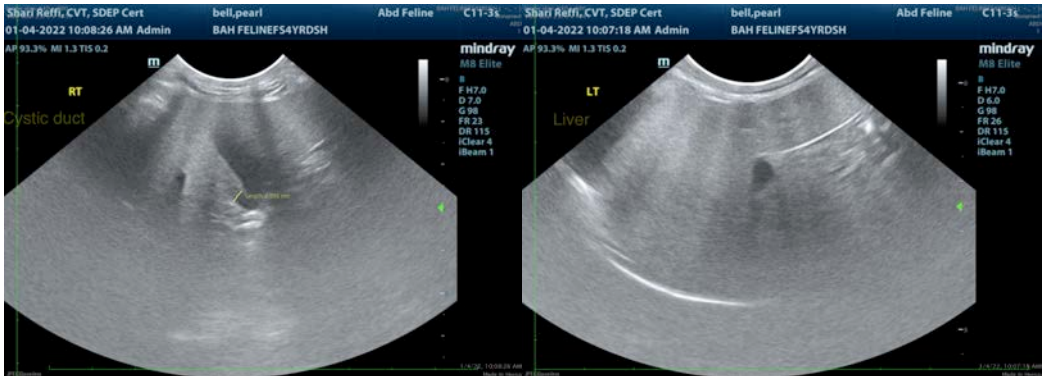

SonoPath
Clinical Sonography & Telecytology

EDUCATIONAL TELECONSULTATION SERVICES™

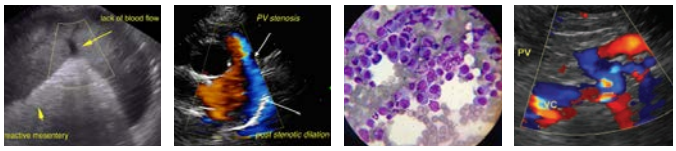

SonoPath.com
1-800-838-4268 info@sonopath.com

PATIENT

Pearl Bell

SPECIES

Feline

BREED

DSH

SEX

Spayed Female

AGE

4 Years 6 Months

WEIGHT

4.9 Pounds

INTERPRETED BY

Beth Johnson, DVM DACVIM

HOSPITAL NAME

VCA Blairstown AH

REFERRING VET

Dr. Clegg

INVOICE NUMBER

33958

DATE

1/4/22

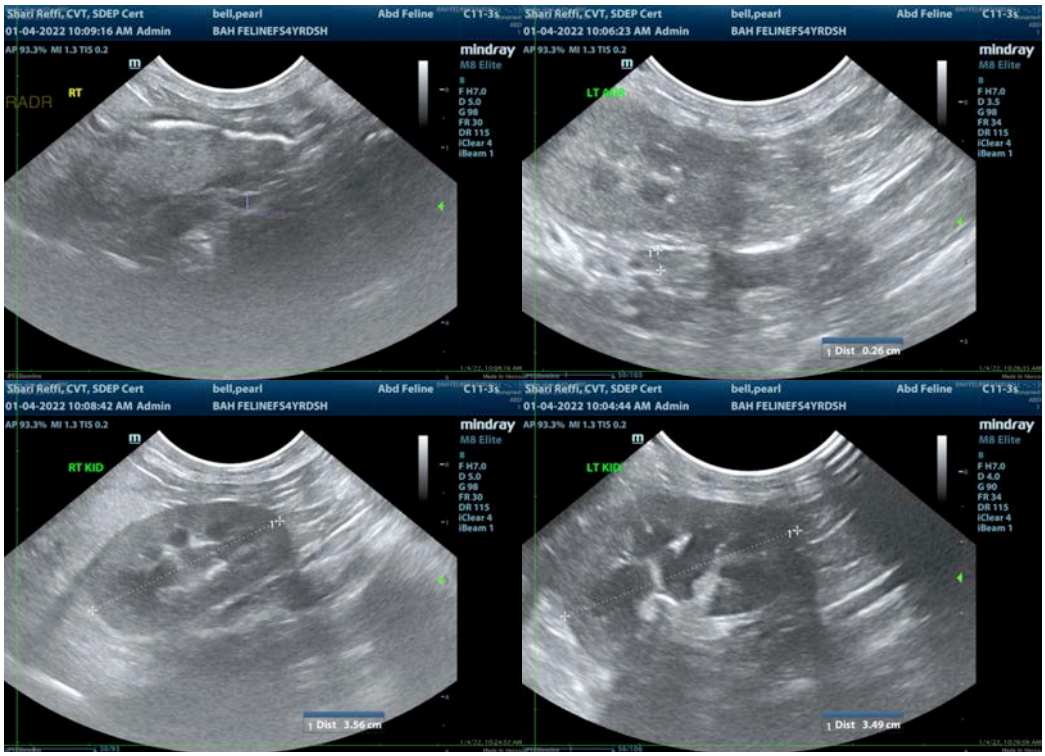

The information and recommendations provided are based on the images presented by the referring veterinarian. No evaluation can be communicated regarding pathology that was not visible in the image/video clips provided.

Thank you for this referral. If the clinical or image interpretation does not parallel your findings or if I can be of any further assistance please contact me.

Beth Johnson, DVM, DACVIM
Beth.Johnson@sonopath.com