

**DATE**

1/31/22

PRESENTING CLINICAL SIGNS

History: Not himself since bout of pancreatitis 3 months ago. Stool soft and dark with mucus. Persistently elevated CPL. Also, mild hematuria noted on free catch urine sample.

Lab Results: Spec CPL 637 (0-200), 3+ blood on UA. Attached separately.

Date of Previous IntraPet Ultrasound: No previous IntraPet scans.

Sedation: Not required to complete full diagnostic ultrasound.

Stat Report: Not requested.

Imaging Performed By: Rachel Brillhart, RDMS.

PATIENT

Griffin Foster

SPECIES

Canine

ULTRASONOGRAPHIC EXAMINATION OF THE ABDOMEN**Urinary System**

Urinary bladder is moderately distended. It has a normal uniform wall thickness (<0.2 cm). Contents include primarily anechoic fluid combined with both gravity dependent and suspended echogenic non-shadowing debris/sand/mineral within the fluid. No masses or cystoliths are observed. The trigone and visible pelvic urethra are normal in thickness with a smooth mucosal surface.

BREED

Brussels Griffon

SEX

Neutered male

The prostate is normal for a neutered dog.

AGE

6/1/12

Left kidney is normal in size (4.0 cm), shape and echogenicity. It has smooth peripheral margination and appropriate corticomedullary distinction. There is no pyelectasia noted.

Right kidney is normal in size (4.0 cm), shape and echogenicity. It has smooth peripheral margination and appropriate corticomedullary distinction. There is no pyelectasia noted. Non-obstructive areas of mineralization/nephroliths are noted, primarily in the diverticular of the kidney.

WEIGHT

12.8 lbs

Adrenal Glands

Left adrenal gland is normal in size (1.95 cm long, 0.57 cm at cranial pole and 0.71 cm at caudal pole), shape and contour. Corticomedullary structure is unremarkable.

Right adrenal gland is normal in size (1.67 cm long, 0.58 cm at cranial pole and 0.64 cm at caudal pole), shape and contour. Corticomedullary structure is unremarkable.

INTERPRETED BYBeth Johnson, DVM
DACVIM**HOSPITAL NAME**

Bay Country VH

Spleen

Spleen is subjectively normal in size with normal smooth margins. Parenchyma is normal in echogenicity and echotexture. No focal nodules or masses are observed. Splenic vasculature appears normal.

REFERRING VET

Dr. McLean

Liver

Liver is subjectively normal in size. Margins are sharp and smooth. It has normal homogenous echotexture and normal echogenicity. No focal lesions are observed. Visible vasculature appears normal. GB contains a moderate amount of non-dependent, mildly aggregated/inspissated sludge. Hypo to anechoic cystic areas are noted between the gallbladder sludge and luminal wall. The wall is otherwise smooth without visible thickening. There is no evidence of cystic or CBD dilation. There is no evidence of effusion.

INVOICE

95663

Gastrointestinal

The visible gastric wall is normal in thickness (canine < 0.5 cm and feline < 0.4 cm). The stomach is empty.

The small intestines are normal in wall thickness and layering. Small intestinal motility appears adequate (1-3 contractions per min). There are no luminal contents noted within small intestines.

Colon is normal in wall thickness (< 0.2 cm) and layering.

Pancreas

Pancreas is prominent in size and mildly irregular in shape with a diffusely coarse echotexture and heterogenous to slightly hyperechoic echogenicity.

Free Abdomen

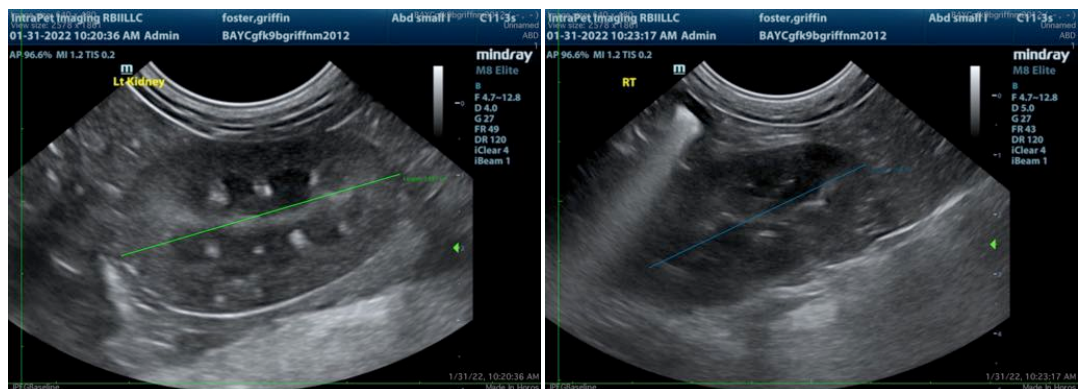
Lymph nodes are normal with no observed enlargement.

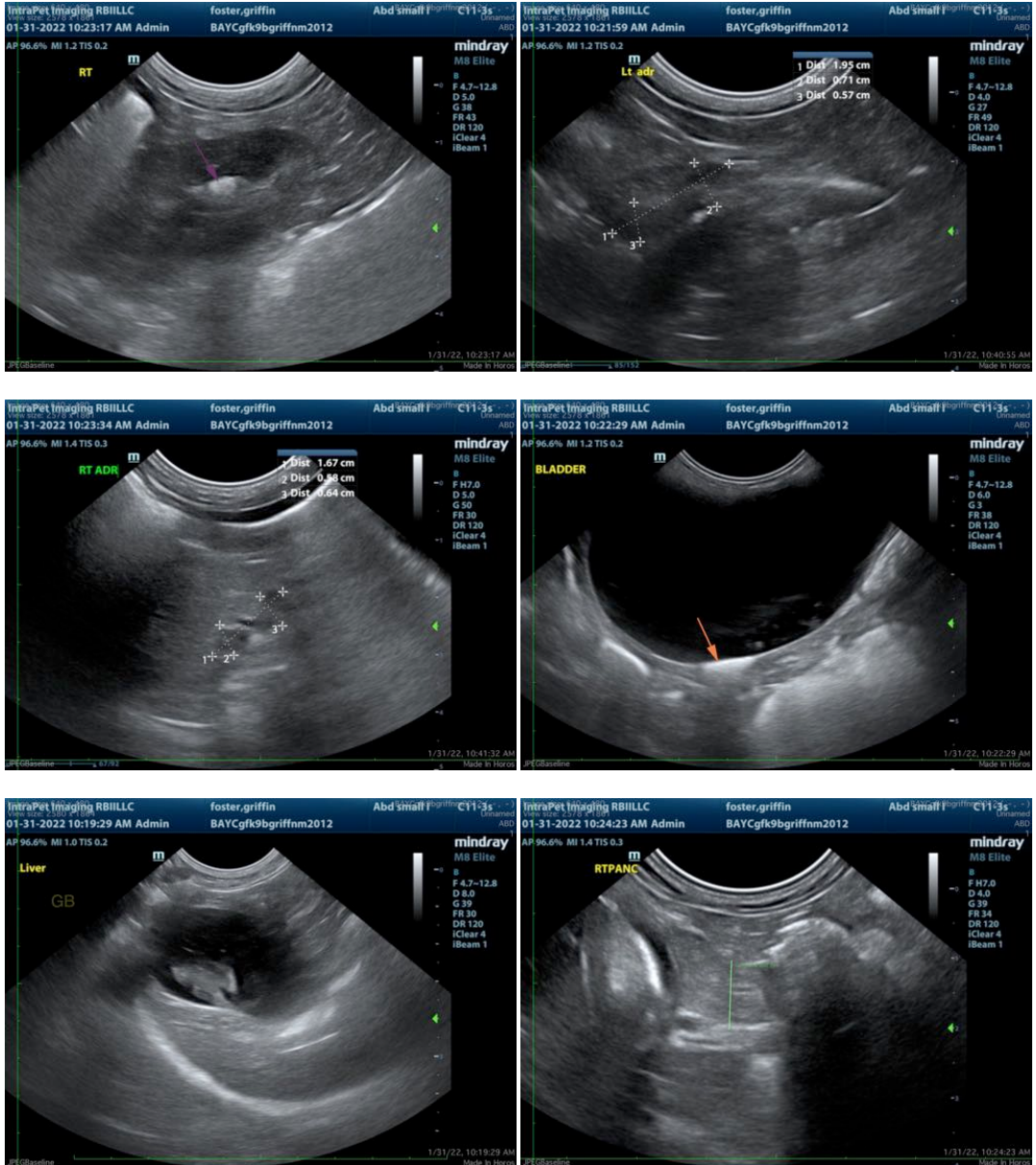
ULTRASONOGRAPHIC FINDINGS

- Urinary bladder sediment (canine) – Urine changes are most consistent with cellular debris or crystalluria.
- Canine early mucocele – Cholecystic debris is of unknown clinical significance. It can be seen with biliary stasis from fasting or illness. Cholecystic debris is not necessarily related to hepatobiliary disease. The non-dependent nature of this sludge combined with the cystic areas are suggestive, however, of possible emerging cystic mucosal hyperplasia or early gallbladder mucocele.
- Nephrolithiasis.

INTERPRETATION OF THE FINDINGS & FURTHER RECOMMENDATIONS

Recommendations for this patient given the pancreatic changes and persistent soft stool include a gastrointestinal malabsorption panel including TLI, PLI, folate and cobalamin to Texas A&M GI laboratory for further assessment of the gastrointestinal tract and pancreas. This should be followed by therapy with a low fat diet if not already in place as well as a potentially course of broad spectrum antibiotics and Ursodiol given the gallbladder changes. If clinical signs persist and/or there is development of cranial abdominal pain, nausea, changes in liver enzymes such as increased ALP or increased total bilirubin then further intervention of the gallbladder may be warranted. Recommendations would include reassessment of ultrasound followed by potential surgical cholecystectomy. Urinalysis is recommended if not already performed followed by urine culture if indicated based on urinalysis results.





The information and recommendations provided are based on the images presented by the referring veterinarian. No evaluation can be communicated regarding pathology that was not visible in the image/video clips provided.

Thank you for this referral. If the clinical or image interpretation does not parallel your findings or if I can be of any further assistance please contact me.

Beth Johnson, DVM DACVIM

Beth.Johnson@SonoPath.com