

**PATIENT**

Rusty Kostro

SPECIES

Canine

BREED

Lab

SEX

Intact Male

AGE

8 Years 10 Months

WEIGHT

83.4

INTERPRETED BYBeth Johnson, DVM
DACVIM**IMAGING
PERFORMED BY**

Dr. Scott

HOSPITAL NAMEWyckoff Veterinary
Hospital**REFERRING VET**

Dr. Scott

INVOICE

72580

DATE

1/29/26

PRESENTING CLINICAL SIGNS

Weight loss, good app, no other GI signs. Routine bw showed low albumin and triggered the work up

Abnormal PE/Chem/CBC/UA Results: PE WNL - history of some skin allergies but right now skin looks pretty good just has a minor ear infection UA clear, UPC 3.7, Alb 2.5, Glob 3.6 Blood pressure- first reading systolic 186, then 152

ULTRASONOGRAPHIC EXAMINATION OF THE ABDOMEN**Urinary System**

The urinary bladder is adequately distended with anechoic contents. No masses, inflammatory changes, echogenic sediment or cystoliths are observed. The urinary bladder, trigone and visible pelvic urethra are normal in thickness with a smooth mucosal surface.

Prostate is symmetrically enlarged (4.8 cm wide in the transverse view) with smooth margins that are well differentiated from surrounding tissue. Normal bilobed shape is maintained. Parenchyma is diffusely hyperechoic. Several small anechoic cysts are noted. No mineral is noted.

The right kidney is normal is size (7.7 cm), shape and echogenicity. It has smooth peripheral margination. There is a normal 1:3 cortex to medulla ratio with appropriate corticomedullary distinction. There is no evidence of pyelectasia, mineral or infarcts observed. A hyperechoic band parallel to the corticomedullary border is present.

The left kidney is normal is size (7.6 cm), shape and echogenicity. It has smooth peripheral margination. There is a normal 1:3 cortex to medulla ratio with appropriate corticomedullary distinction. There is no evidence of pyelectasia, mineral or infarcts observed. A hyperechoic band parallel to the corticomedullary border is present.

Adrenal Glands

The right adrenal gland is normal in size (0.87 cm at cranial pole and 0.55 cm at caudal pole), shape and overall architecture, echogenicity and echotexture. Visible surrounding vasculature appears normal.

The area of the left adrenal gland is examined without evident adrenal gland pathology but it is difficult to fully visualize/isolate for measurement.

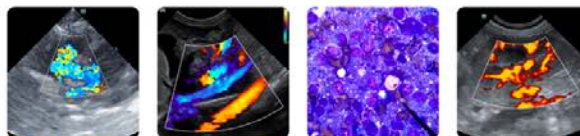
Spleen

Spleen is subjectively large in size (2.3 cm thick at the hilus) with a mildly swollen but smooth capsule. Parenchyma is normal and homogenous in echogenicity and echotexture. No focal nodules or masses are observed. Splenic vasculature appears normal.

Liver

The liver is subjectively normal in size with normal smooth curvilinear peripheral contour. Parenchyma is appropriately hypoechoic to the spleen in echogenicity and appropriately mildly coarse and homogenous in echotexture. No focal lesions are observed. Visible vasculature and biliary tree appear normal without distension or congestion.

The gallbladder is non-distended in size. The wall is smooth without visible thickening. Luminal contents are primarily anechoic. There is no evidence of cystic or common bile duct dilation.



PATIENT

Rusty Kostro

SPECIES

Canine

BREED

Lab

SEX

Intact Male

AGE

8 Years 10 Months

WEIGHT

83.4

INTERPRETED BY

Beth Johnson, DVM
DACVIM

IMAGING PERFORMED BY

Dr. Scott

HOSPITAL NAME

Wyckoff Veterinary
Hospital

REFERRING VET

Dr. Scott

INVOICE

72580

DATE

1/29/26

Gastrointestinal

The visible stomach wall is normal in thickness and layering. The stomach is moderately distended with echogenic non-shadowing luminal contents and gas consistent with normal ingesta. There is no evidence of obstruction, foreign material or infiltrative disease. If patient was appropriately fasted, delayed gastric emptying could be considered. Non-shadowing foreign material is considered less likely but cannot be definitively ruled out.

If clinical signs are consistent (vomiting, etc.), recommendations include supportive medical care, 24 hours fasting and re-image.

The visible small intestines are normal in wall thickness and layering. Small intestinal motility appears adequate (1-3 contractions per min). The lumen is mildly distended with echogenic non-shadowing luminal contents and gas consistent with normal ingesta/chyme. There is no evidence of obstruction, foreign material or infiltrative disease.

The visible colon is normal in wall thickness (< 0.2 cm) and layering. Contents are consistent with normal formed feces and gas.

Pancreas

The pancreas that is observed appears appropriately isoechoic to surrounding omental fat. Visible capsule is smooth and normal in contour. Visible pancreatic parenchyma is homogenous and unremarkable. There is no visible pancreatic duct dilation. There is no evidence of active peripancreatic inflammation.

Free Abdomen

There is no visible free peritoneal effusion noted in these images.

There is no apparent pathologic lymphadenopathy noted in these images.

ULTRASONOGRAPHIC FINDINGS

- Mild splenomegaly- can be associated with congestion caused by sedation (if sedated) but can also be associated with diffuse infiltrative disease. Both benign conditions such as extramedullary hematopoiesis, lymphoid hyperplasia, as well as infiltrative neoplastic diseases such as round cell neoplasia should be considered.
- Bilateral medullary rim sign - This finding is of unknown clinical significance and can be a normal variant, often idiopathic. Medullary rim sign can be present with renal disease including lymphoma, hypercalcemic nephropathy, Leptospirosis, tubular disease, other and should be interpreted in combination with other more specific indications of kidney disease such as isosthenuria, proteinuria, azotemia, etc. This is a common incidental finding in patients with diabetes mellitus.
- Benign Prostatic Hyperplasia with cysts - Prostatic findings are most consistent with Benign Prostatic Hyperplasia (BPH) and concurrent benign prostatic cysts. Active prostatitis cannot be ruled out. Infiltrative neoplasia cannot be ruled out but is considered less likely.



PATIENT

Rusty Kostro

SPECIES

Canine

BREED

Lab

SEX

Intact Male

AGE

8 Years 10 Months

WEIGHT

83.4

INTERPRETED BY

Beth Johnson, DVM
DACVIM

IMAGING PERFORMED BY

Dr. Scott

HOSPITAL NAME

Wyckoff Veterinary
Hospital

REFERRING VET

Dr. Scott

INVOICE

72580

DATE

1/29/26

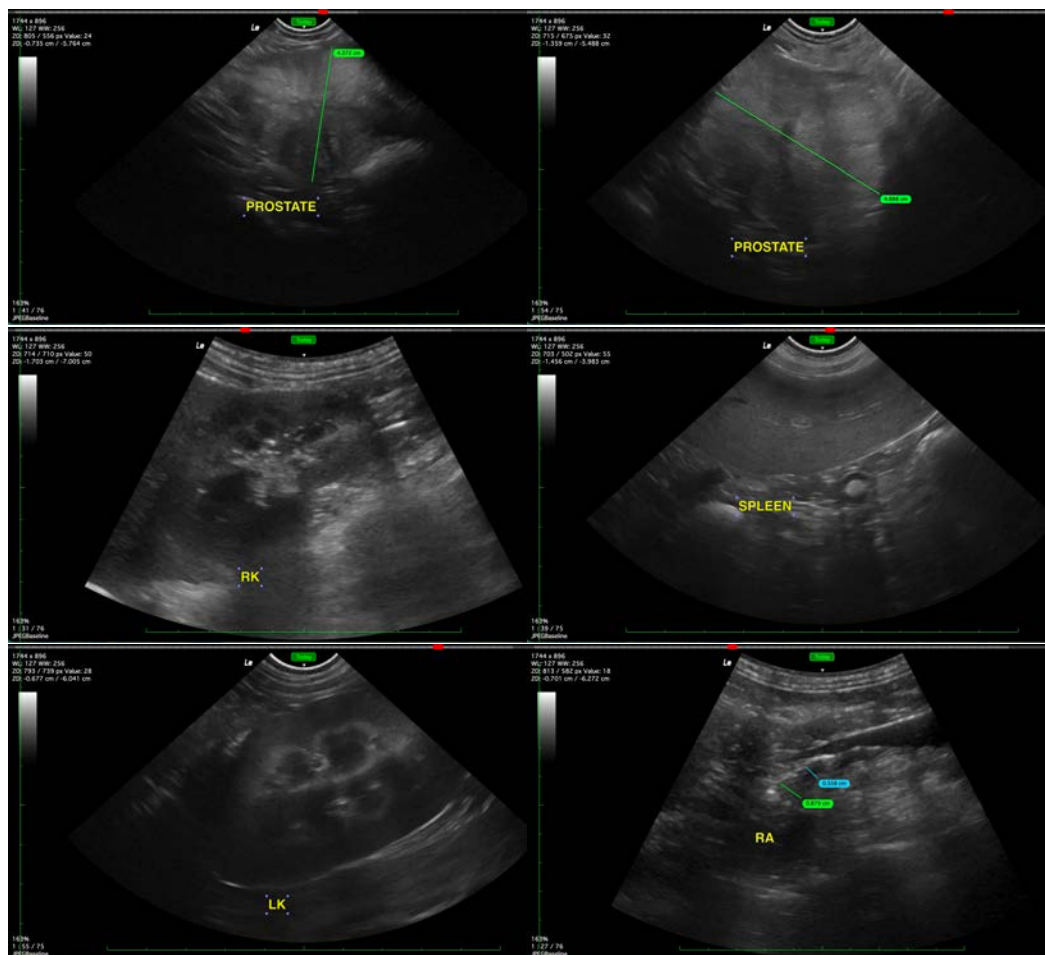
INTERPRETATION OF THE FINDINGS & FURTHER RECOMMENDATIONS

Given patient's proteinuria, a comprehensive infectious disease evaluation including ruling out a urinary tract infection/prostatitis, etc. is recommended.

Further hypoalbuminemia warrants ruling out other contributing diseases to definitively diagnosis urine loss as the cause. Therefore, a baseline cortisol is recommended. If baseline cortisol is less than 2, a full ACTH stimulation test is recommended to rule out hypoadrenocorticism.

A gastrointestinal malabsorption panel (including cobalamin, folate, TLI and PLI) to Texas A&M GI Laboratory is recommended for further evaluation of GI and pancreatic function.

In the meantime, if proteinuria is persistent with an otherwise quiet sediment, and another underlying cause or contributing factor to the hypoalbuminemia is not diagnosed, treatment recommendations include enalapril (or benazepril if azotemic) +/- ARB, anti-thrombotic (low dose aspirin or clopidogrel), a renal diet if tolerated and fatty acid supplementation. Begin FA supplementation slowly to prevent GI upset. If hypertension is present, additional therapy with amlodipine may be necessary to manage hypertension.





PATIENT

Rusty Kostro

SPECIES

Canine

BREED

Lab

SEX

Intact Male

AGE

8 Years 10 Months

WEIGHT

83.4

INTERPRETED BY

Beth Johnson, DVM
DACVIM

IMAGING PERFORMED BY

Dr. Scott

HOSPITAL NAME

Wyckoff Veterinary
Hospital

REFERRING VET

Dr. Scott

INVOICE

72580

DATE

1/29/26

The information and recommendations provided are based on the images presented by the referring veterinarian/sonographer. No evaluation can be communicated regarding pathology that was not visible in the image/video clips provided.

Thank you for this referral. If the clinical or image interpretation does not parallel your findings or if I can be of any further assistance please contact me.

Beth Johnson, DVM, DACVIM
info@sonopath.com