



DATE PRESENTING CLINICAL SIGNS

1/29/26

Patient History: Persistent regurgitation unless on omeprazole and famotidine. Regurg is usually within 2 mins of eating. previous bw unremarkable including cortisol

PATIENT

Rufus Jones

Current Medications: Omeprazole 10mg BID, zofran 8mg BID

Labwork Results: Labwork not attached.

Date of Previous IntraPet Ultrasound: No previous.

Sedation: Not required to complete full diagnostic ultrasound.

Stat Report: Not requested.

Imaging Performed by: Rachel Brillhart, RDMS.

SPECIES

Canine

BREED

Mixed

SEX

Neutered Male

AGE

7/19/24

WEIGHT

34 lbs

INTERPRETED BY

Beth Johnson, DVM
DACVIM

ULTRASONOGRAPHIC EXAMINATION OF THE ABDOMEN

Urinary System

The urinary bladder is adequately distended with anechoic contents. No masses, inflammatory changes, echogenic sediment or cystoliths are observed. The urinary bladder, trigone and visible pelvic urethra are normal in thickness with a smooth mucosal surface.

Prostate is normal in size, echotexture and echogenicity for a neutered male.

The right kidney is normal is size (5.64 cm), shape and echogenicity. It has smooth peripheral margination. There is a normal 1:3 cortex to medulla ratio with appropriate corticomedullary distinction. There is no evidence of pyelectasia, mineral or infarcts observed. A hyperechoic band parallel to the corticomedullary border is present.

The left kidney is normal is size (5.26 cm), shape and echogenicity. It has smooth peripheral margination. There is a normal 1:3 cortex to medulla ratio with appropriate corticomedullary distinction. There is no evidence of pyelectasia, mineral or infarcts observed. A hyperechoic band parallel to the corticomedullary border is present.

HOSPITAL NAME

Northwind Animal
Hospital

Adrenal Glands

The right adrenal gland is normal in size (0.56 cm at cranial pole and 0.61 cm at caudal pole), shape and overall architecture, echogenicity and echotexture. Visible surrounding vasculature appears normal.

REFERRING VET

Dr. Jones

The left adrenal gland is normal in size (0.46 cm at cranial pole and 0.50 cm at caudal pole), shape and overall architecture, echogenicity and echotexture. Visible surrounding vasculature appears normal.

Spleen

INVOICE

72607

The spleen is subjectively normal in size with a normal smooth capsular contour. Parenchyma is appropriately finely textured and homogenous with normal echogenicity relative to surrounding tissue (hyperechoic to liver). No focal nodules or masses are observed. Splenic vasculature appears normal.

Liver

The liver is subjectively normal in size with normal smooth curvilinear peripheral contour. Parenchyma is appropriately hypoechoic to the spleen in echogenicity and appropriately mildly coarse and homogenous in

echotexture. No focal lesions are observed. Visible vasculature and biliary tree appear normal without distension or congestion.

The gallbladder is non-distended in size. The wall is smooth without visible thickening. Luminal contents are primarily anechoic. There is no evidence of cystic or common bile duct dilation.

Gastrointestinal

The visible stomach wall is normal in thickness and layering. The lumen of the stomach is mildly distended with very echogenic reverberation artifact from intraluminal gas. There is no evidence of obstruction, foreign material, or infiltrative disease; however, visualization is partially inhibited by gas.

The visible small intestines are normal in wall thickness and layering. Small intestinal motility appears adequate (1-3 contractions per min). The lumen of the small intestine is empty with no evidence of obstruction, foreign material or infiltrative disease.

The visible colon is normal in wall thickness (< 0.2 cm) and layering. Contents are consistent with normal formed feces and gas.

Pancreas

Pancreas is prominent (enlarged) in size and mildly irregular in shape with a slightly undulating contour. Parenchyma is coarse in echotexture and heterogenous to hypoechoic in echogenicity. **This change is very mild/subtle.*

Free Abdomen

There is no visible free peritoneal effusion noted in these images.

Mesenteric and cranial abdominal lymph nodes are prominent in size with swollen capsular contour. Normal elongated shape (length to width ratio) is maintained. There is no loss of parenchymal detail.

ULTRASONOGRAPHIC FINDINGS

- The changes described above are very mild/subtle and largely non-specific, but the mesenteric and cranial abdominal lymph nodes are reactive – This finding may be in part normal patient variant/juvenile lymphadenopathy. Infiltrative neoplastic disease cannot be ruled out but is considered less likely.
- A mildly prominent pancreas could indicate chronic low-grade smoldering pancreatitis versus normal patient variant.
- Subtle bilateral medullary rim sign - This finding is of unknown clinical significance and can be a normal variant, often idiopathic. Medullary rim sign can be present with renal disease including lymphoma, hypercalcemic nephropathy, Leptospirosis, tubular disease, other and should be interpreted in combination with other more specific indications of kidney disease such as isosthenuria, proteinuria, azotemia, etc. This is a common incidental finding in patients with diabetes mellitus.

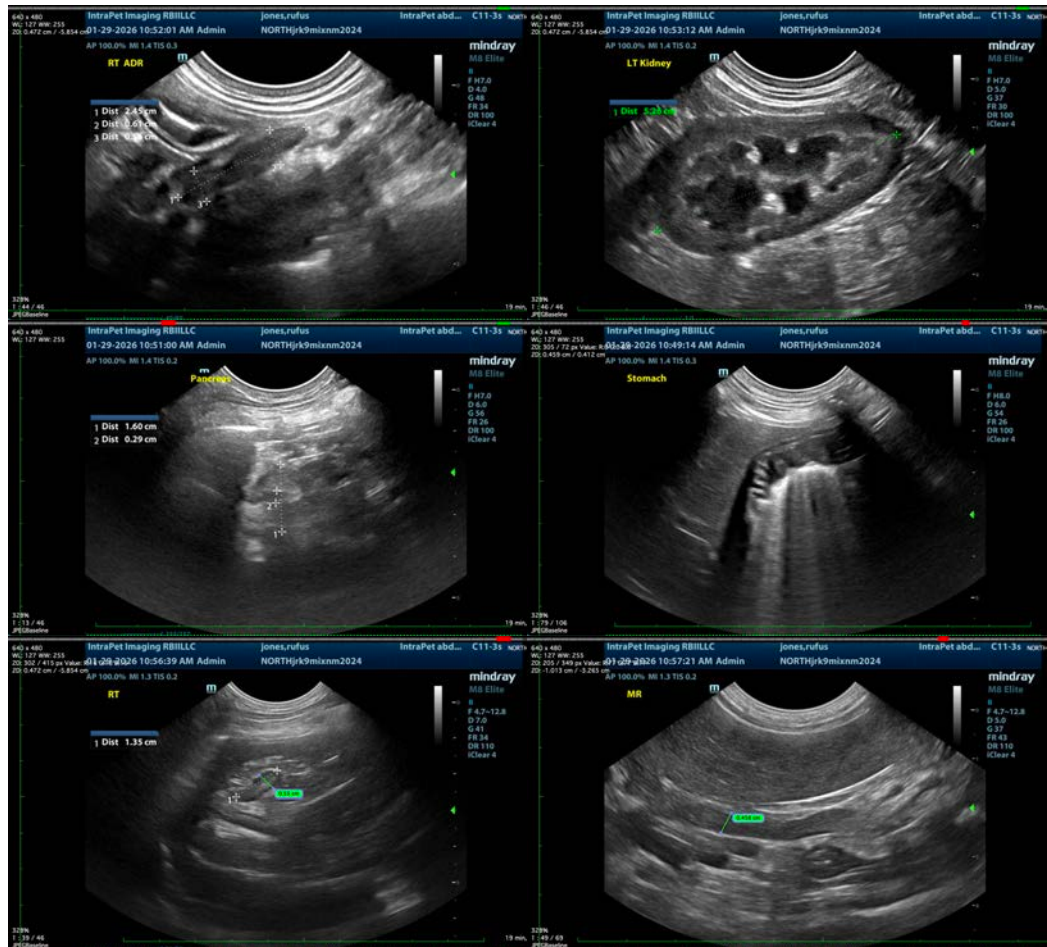
INTERPRETATION OF THE FINDINGS & FURTHER RECOMMENDATIONS

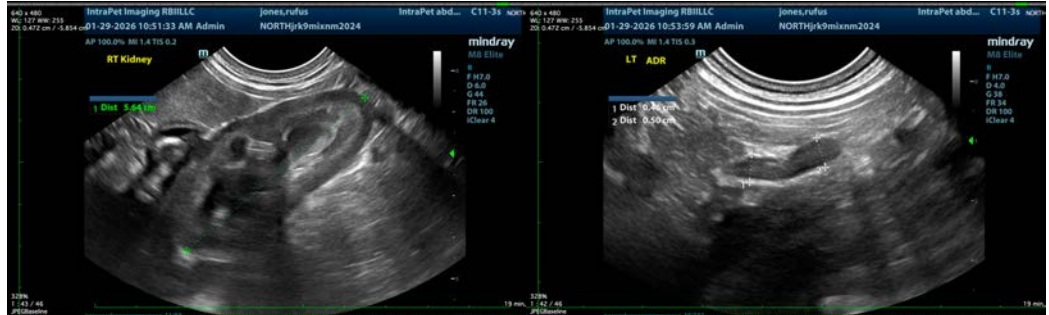
Given patient's reported history, if thoracic radiographs have not been evaluated, 3-view thoracic radiographs are recommended to further evaluate the esophagus. Pending results of that evaluation, other imaging including a swallow study could be considered. Additionally, testing or evaluation of focal myasthenia gravis could be considered.

In the meantime, supportive/symptomatic medical management of clinical signs is recommended, including anti-emetics, gastroprotectants (+/- sucralfate, especially with any history of hematemesis), an appetite stimulant and fluid therapy if indicated, etc.

Additionally, empirical deworming with a 5-day course of Panacur is recommended as is a full course of empirical Helicobacter triple therapy.

Finally, if tolerated, a transition in diet could be considered, based on trial-and-error response with some options to consider including a gastrointestinal biome diet vs a hydrolyzed protein diet (sometimes several trials with different brands are necessary) vs an easy to digest, bland or low-fat diet vs other.





The information and recommendations provided are based on the images presented by the referring veterinarian/sonographer. No evaluation can be communicated regarding pathology that was not visible in the image/video clips provided.

Thank you for this referral. If the clinical or image interpretation does not parallel your findings or if I can be of any further assistance please contact me.

Beth Johnson, DVM, DACVIM
info@sonopath.com