



## PATIENT

Mr. Beasley Smith

## SPECIES

Feline

## BREED

DSH

## SEX

Neutered Male

## AGE

15 Years 6 Months

## WEIGHT

5.9 kg

## INTERPRETED BY

Beth Johnson, DVM  
DACVIM

## IMAGING PERFORMED BY

Renee Trionfetti, VMD

## HOSPITAL NAME

Blue Pearl Wyomissing

## REFERRING VET

Blue Pearl Wyomissing

## INVOICE

72567

## DATE

1/29/26

## PRESENTING CLINICAL SIGNS

AUS to further evaluate difficult to control DM, hypoglycemia intermittently. UA suspected UTI. Currently hospitalized in the ER. PMH: DM x 3 years, recently difficult to control

Meds: Insulin, Lantus, Unasyn 30.5mg/kg

Abnormal PE/Chem/CBC/UA Results: 12/5/2025 rDVM: CBC: HCT 27, Neuts 14k, PLT 514k UA: 1.020, pto 1+, gluc 3+, ket neg, WBC 21-50/hpf, RBC 4-10/hpf, bacteria cocci <10 UPC: 1.5 Chem WNLs other than hyperglycemia 1/29: ER EPOC: Glu 524, K 4.3, Na 141, Lac 2.69 Chem: Glob 5.3, BUN 38.3, Creat 1.4 PCV/TS: 28/9.2 CBC: HCT 29.9, Neuts 8.75k, PLT 394k UA: 1.018, WBC 3+, chain cocci 2+, rods occ

## ULTRASONOGRAPHIC EXAMINATION OF THE ABDOMEN

### Urinary System

Urinary bladder is adequately distended. It has a normal uniform wall thickness. Contents include primarily anechoic fluid with occasional echogenic non-shadowing debris, most consistent with incidental suspended lipid in a cat, possibly combined with exfoliated cells, mucous and/or small blood clots. Both sterile inflammation as well as urinary tract infection can also present with echogenic debris. No masses or definitive cystoliths are observed. The trigone and visible pelvic urethra are normal in thickness with a smooth mucosal surface.

The right kidney is normal is size (3.8 cm), shape and echogenicity. It has smooth peripheral margination. There is a normal 1:3 cortex to medulla ratio with appropriate corticomedullary distinction. There is no evidence of pyelectasia, mineral or infarcts observed.

The left kidney is normal is size (4.3 cm), shape and echogenicity. It has smooth peripheral margination. There is a normal 1:3 cortex to medulla ratio with appropriate corticomedullary distinction. There is no evidence of pyelectasia, mineral or infarcts observed.

### Adrenal Glands

The right adrenal gland is normal in size (0.41 cm at cranial pole and 0.37 cm at caudal pole), shape and overall architecture, echogenicity and echotexture. Visible surrounding vasculature appears normal.

The left adrenal gland is normal in size (0.39 cm at cranial pole and X0.39 cm at caudal pole), shape and overall architecture, echogenicity and echotexture. Visible surrounding vasculature appears normal.

### Spleen

The spleen is subjectively normal in size with a normal smooth capsular contour. Parenchyma is appropriately finely textured and homogenous with normal echogenicity relative to surrounding tissue (hyperechoic to liver). No focal nodules or masses are observed. Splenic vasculature appears normal.

### Liver

Liver is subjectively enlarged (swollen contour) without disruption of architecture. It has a normal homogenous echotexture. Parenchyma is diffusely hyperechoic characterized by less prominent than normal portal vein walls and increased echogenicity relative to the spleen and falciform fat. No focal lesions are observed. Visible vasculature and biliary tree appear normal without distension or congestion.



## PATIENT

Mr. Beasley Smith

## SPECIES

Feline

## BREED

DSH

## SEX

Neutered Male

## AGE

15 Years 6 Months

## WEIGHT

5.9 kg

## INTERPRETED BY

Beth Johnson, DVM  
DACVIM

## IMAGING PERFORMED BY

Renee Trionfetti, VMD

## HOSPITAL NAME

Blue Pearl Wyomissing

## REFERRING VET

Blue Pearl Wyomissing

## INVOICE

72567

## DATE

1/29/26

The gallbladder is non-distended in size. The wall is smooth without visible thickening. Luminal contents are primarily anechoic. There is no evidence of cystic or common bile duct dilation.

### **Gastrointestinal**

The visible stomach wall is normal in thickness and layering. The lumen of the stomach is mildly distended with a small to moderate amount of echogenic non-shadowing luminal contents and gas consistent with normal ingesta. There is no evidence of obstruction, foreign material or infiltrative disease. Pyloric outflow tract appears patent.

The visible small intestine demonstrates areas of moderately thick muscularis layer relative to mucosa (disruption of the normal 1:3 muscularis:mucosa ratio). Small intestinal submucosa is slightly irregular, thick and hyperechoic, without evident loss of layering appreciated. The lumen is mildly distended with echogenic non-shadowing luminal contents and gas consistent with normal ingesta/chyme. There is no evidence of obstruction, foreign material or infiltrative disease.

The visible colon is normal in wall thickness (< 0.2 cm) and layering. Contents are consistent with normal formed feces and gas.

### **Pancreas**

The observed pancreas is prominent (enlarged) in size, hypoechoic to surrounding tissue and irregular in shape with a swollen undulating contour. Pancreatic duct dilation is noted. Enhanced hyperechoic ill-defined surrounding fat is noted, primarily in the right cranial abdomen.

### **Free Abdomen**

There is no visible free peritoneal effusion noted in these images.

There is no apparent pathologic lymphadenopathy noted in these images.

The enhanced tissue adjacent to the pancreas is primarily in the right cranial abdomen and could in part be secondary to inflammation associated with the right kidney, such as seen with pyelonephritis versus other.

### **ULTRASONOGRAPHIC FINDINGS**

- Suspect acute pancreatitis, likely an acute on chronic low-grade smoldering flare up.
- Concurrent pyelonephritis involving primarily the right kidney can't be ruled out.
- Moderate inflammatory bowel disease (IBD) pattern – Thick muscularis has been reported with infiltrative bowel disease including both benign inflammatory disease as well as infiltrative neoplasia such as lymphoma. No loss of layering or distinct characteristics of malignancy are present. Therefore, differentials cannot be further ranked without tissue sampling. *\*This finding could be in part normal patient variant in a senior cat and should be interpreted in combination with any clinical history of gastrointestinal disease.*
- Hyperechoic hepatomegaly – This appearance is most consistent with benign hepatic lipidosis or endocrine/DM hepatopathy. Infiltrative disease such as amyloidosis or round cell neoplasia, such as mast cell tumor or less likely, lymphoma, is also possible.



## PATIENT

Mr. Beasley Smith

## SPECIES

Feline

## BREED

DSH

## SEX

Neutered Male

## AGE

15 Years 6 Months

## WEIGHT

5.9 kg

## INTERPRETED BY

Beth Johnson, DVM  
DACVIM

## IMAGING PERFORMED BY

Renee Trionfetti, VMD

## HOSPITAL NAME

Blue Pearl Wyomissing

## REFERRING VET

Blue Pearl Wyomissing

## INVOICE

72567

## DATE

1/29/26

- Mild to moderate amount of echogenic urinary bladder debris.

## INTERPRETATION OF THE FINDINGS & FURTHER RECOMMENDATIONS

A urine culture is recommended if not recently evaluated.

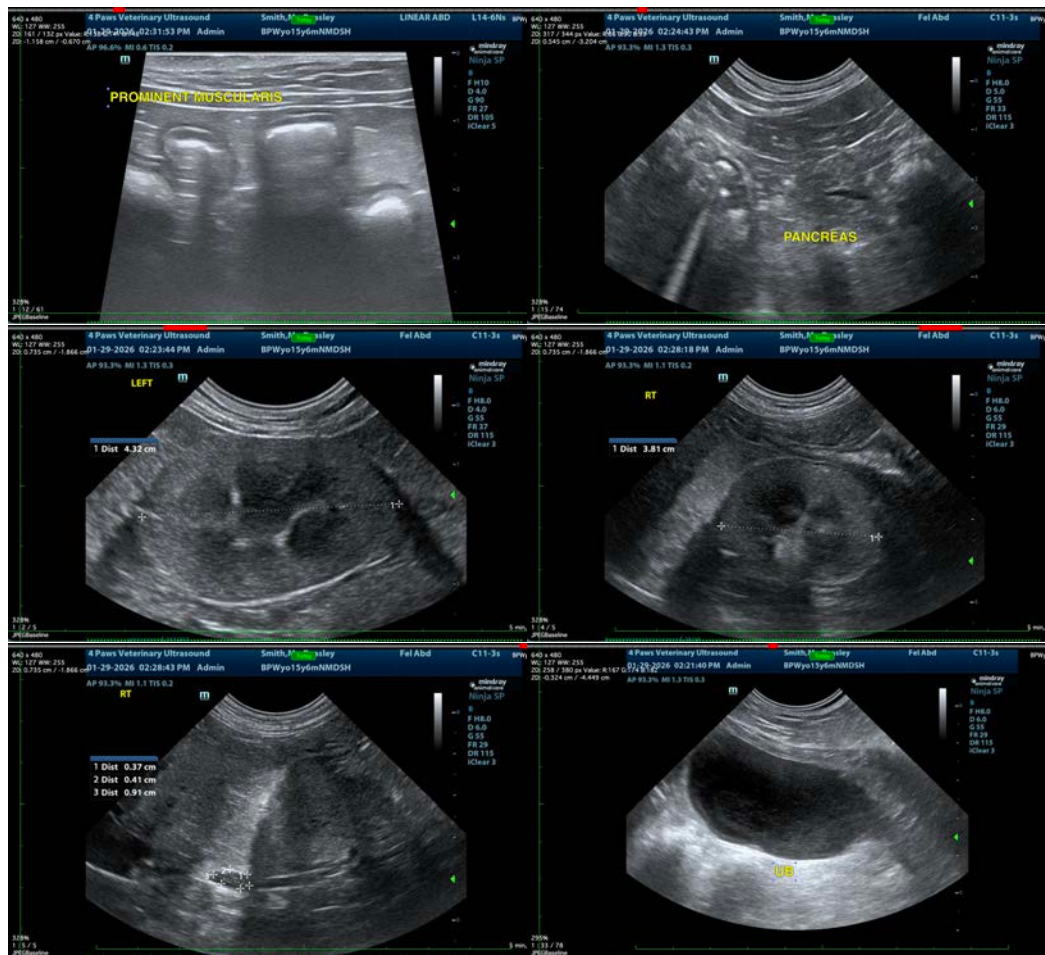
A gastrointestinal malabsorption panel (including cobalamin, folate, TLI and PLI) to Texas A&M GI Laboratory is recommended for further evaluation of GI and pancreatic function.

In the meantime, placement of a freestyle libre sensor could assist in tighter regulation of the diabetes mellitus.

Given the subtle pancreas and bowel changes, other considerations could include:

If tolerated, a transition in diet is recommended, based on trial-and-error response.

Some options to consider include a gastrointestinal biome diet vs a hydrolyzed protein diet (sometimes several trials with different brands are necessary) vs a fiber response/colitis diet vs a bland, easy to digest or low-fat diet vs other.





## PATIENT

Mr. Beasley Smith

## SPECIES

Feline

## BREED

DSH

## SEX

Neutered Male

## AGE

15 Years 6 Months

## WEIGHT

5.9 kg

## INTERPRETED BY

Beth Johnson, DVM  
DACVIM

## IMAGING PERFORMED BY

Renee Trionfetti, VMD

## HOSPITAL NAME

Blue Pearl Wyomissing

## REFERRING VET

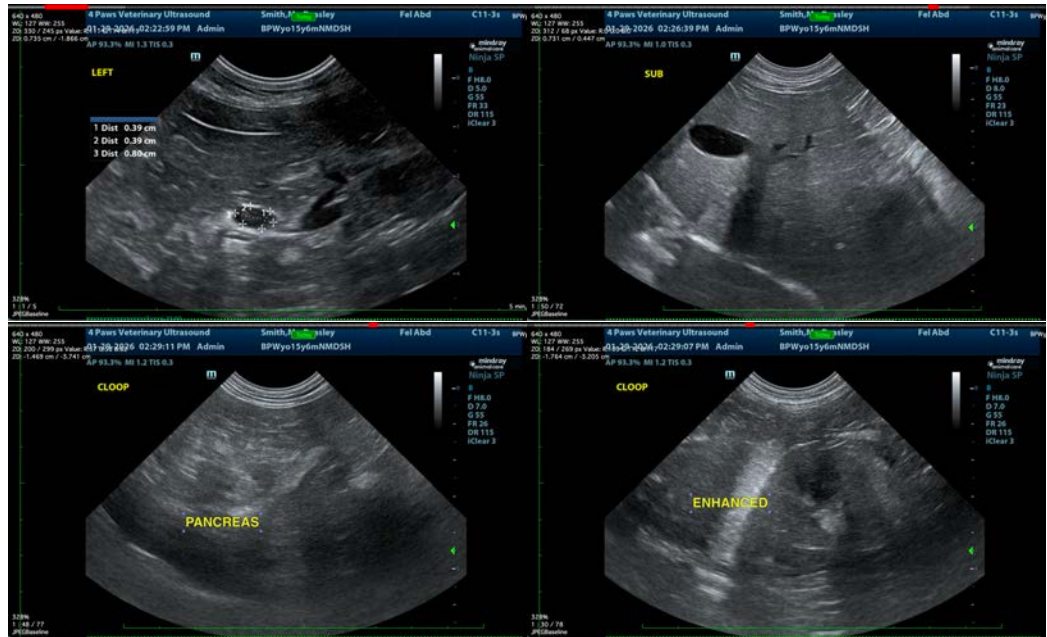
Blue Pearl Wyomissing

## INVOICE

72567

## DATE

1/29/26



The information and recommendations provided are based on the images presented by the referring veterinarian/sonographer. No evaluation can be communicated regarding pathology that was not visible in the image/video clips provided.

Thank you for this referral. If the clinical or image interpretation does not parallel your findings or if I can be of any further assistance please contact me.

Beth Johnson, DVM, DACVIM  
info@sonopath.com