



<b>PATIENT</b>	<b>PRESENTING CLINICAL SIGNS</b>
Mason Mcallister	Mason has been presented with complaint of weight loss, reduced appetite. Tense abdomen cranially on palpation. Suspect pancreatitis
<b>SPECIES</b>	Current Medications: Gabapentin.
Canine	Abnormal PE/Chem/CBC/UA Results: Values JI: 01-22-26 at 12:24p: Dec HCT and Hg due to decreased appetite SDMA 17 (0-14) ALT 525 (18-121) AST 123 (16-55) ALP 2581 (5-160) Chol 12 (3.4-8.9)
<b>BREED</b>	Increased amylase and Lipase CK 490 (10-200) Waiting on CPLi and fecal Appears to be pancreatitis with liver involvement - an abdominal U/S is recommended JI: 01-23-26 at 10:26a: Spec CPLi 271 (0-200) - elevated Primary Question to Be Answered in This Exam Confirm diagnosis
Chihuahua x	
<b>SEX</b>	<b>ULTRASONOGRAPHIC EXAMINATION OF THE ABDOMEN</b>
Neutered Male	<b>Urinary System</b>
<b>AGE</b>	Urinary bladder is only mildly distended. Visible contents are anechoic. Urinary bladder wall is unable to be fully assessed for pathology without further distension. No visible masses or definitive cystoliths are observed. The trigone and visible pelvic urethra are normal thickness with a smooth mucosal surface. In the face of urinary signs and/or suspected urinary bladder pathology, reassessment after complete filling is recommended.
12 Years	
<b>WEIGHT</b>	The area of the prostate is examined without evident prostatic pathology.
5 kg	
<b>INTERPRETED BY</b>	The right kidney is normal is size (4.49 cm), shape and echogenicity. It has smooth peripheral margination. There is a normal 1:3 cortex to medulla ratio with appropriate corticomedullary distinction. There is no evidence of pyelectasia, mineral or infarcts observed.
Beth Johnson, DVM DACVIM	
<b>IMAGING PERFORMED BY</b>	The left kidney is normal is size (3.97 cm), shape and echogenicity. It has smooth peripheral margination. There is a normal 1:3 cortex to medulla ratio with appropriate corticomedullary distinction. There is no evidence of pyelectasia, mineral or infarcts observed.
Amanda Stewart	
<b>HOSPITAL NAME</b>	<b>Adrenal Glands</b>
Snelgrove Veterinary Services	The area of the right adrenal gland is examined without evident adrenal gland pathology, but it is difficult to fully visualize/isolate for measurement owing to pathology in the area and reported discomfort during the scan.
<b>REFERRING VET</b>	The left adrenal gland is normal in size (0.51 cm at cranial pole and 0.63 cm at caudal pole), shape and overall architecture, echogenicity and echotexture. Visible surrounding vasculature appears normal.
Dr. Ioannou	
<b>INVOICE</b>	<b>Spleen</b>
72544	The spleen is subjectively normal in size with a normal smooth capsular contour. Parenchyma is appropriately finely textured and homogenous with normal echogenicity relative to surrounding tissue (hyperechoic to liver). No focal nodules or masses are observed. Splenic vasculature appears normal.
<b>DATE</b>	<b>Liver</b>
1/28/26	Liver is subjectively enlarged with mildly irregular margins. Parenchyma is moderately heterogenous characterized by multiple poorly defined hypoechoic nodules within otherwise hyperechoic liver parenchyma. Focally, in the mid to right caudal liver is a more focally defined, round, homogeneous, hypoechoic mass lesion measuring 7.3 cm x 5.8 cm in size. Free fluid and enhanced tissue are noted



**PATIENT**

Mason Mcallister

**SPECIES**

Canine

**BREED**

Chihuahua x

**SEX**

Neutered Male

**AGE**

12 Years

**WEIGHT**

5 kg

**INTERPRETED BY**

Beth Johnson, DVM  
 DACVIM

**IMAGING PERFORMED BY**

Amanda Stewart

**HOSPITAL NAME**

Snelgrove Veterinary  
 Services

**REFERRING VET**

Dr. Ioannou

**INVOICE**

72544

**DATE**

1/28/26

adjacent to the mass. Visible vasculature and biliary tree appear normal without distension or congestion.

Gallbladder is moderately distended with anechoic bile as well as suspended and gravity dependent echogenic debris. The wall is smooth without visible thickening. There is no evidence of cystic or CBD dilation. There is no evidence of effusion or inflammation.

**Gastrointestinal**

The visible stomach wall is normal in thickness and layering. The lumen of the stomach is empty with no evidence of obstruction, foreign material or infiltrative disease. Pyloric outflow tract appears patent.

The visible small intestines are normal in wall thickness and layering. Small intestinal motility appears adequate (1-3 contractions per min). The lumen of the small intestine is empty with no evidence of obstruction, foreign material or infiltrative disease.

The visible colon is normal in wall thickness (< 0.2 cm) and layering. Contents are consistent with normal formed feces and gas.

**Pancreas**

The pancreas that is observed appears appropriately isoechoic to surrounding omental fat. Visible capsule is smooth and normal in contour. Visible pancreatic parenchyma is homogenous and unremarkable. There is no visible pancreatic duct dilation. There is no evidence of active peripancreatic inflammation.

**Free Abdomen**

There is a moderate amount of free fluid noted in these images.

There is no apparent pathologic lymphadenopathy noted in these images.

**ULTRASONOGRAPHIC FINDINGS**

- Diffusely moderately heterogenous liver – These changes are most consistent with benign processes such as nodular hyperplasia, steroid (vacuolar) hepatopathy, extramedullary hematopoiesis or possibly chronic inflammatory disease and less commonly infiltrative round cell or metastatic neoplasia. Focally, the mass lesion could represent the same differentials as listed above, although a more focal process such as a hepatoma/adenoma or even infiltrative neoplasia such as hepatocellular carcinoma, sarcoma, round cell neoplasia, other can't be ruled out without tissue sampling.
- Moderate gallbladder debris - Cholecystic debris is of unknown clinical significance. It can be seen with biliary stasis from fasting or illness. Cholecystic debris is not necessarily related to hepatobiliary disease. Echogenic bile is most commonly an incidental finding in dogs and should be interpreted in combination with clinical signs such as nausea, inappetence, cranial abdominal discomfort and/or laboratory changes such as increased ALP and/or increased Tbili.
- The moderate amount of free fluid is of unknown origin. Differentials (unless already ruled out) could include increased hydrostatic pressure (cardiac disease and/or vascular or lymph blockage), decreased oncotic pressure (low albumin), vasculitis, paraneoplastic fluid, rupture/leakage of/from an organ (GI, GB, UB, other), blood (hemoabdomen), other.



**PATIENT**

Mason Mcallister

**SPECIES**

Canine

**BREED**

Chihuahua x

**SEX**

Neutered Male

**AGE**

12 Years

**WEIGHT**

5 kg

**INTERPRETED BY**

Beth Johnson, DVM  
 DACVIM

**IMAGING PERFORMED BY**

Amanda Stewart

**HOSPITAL NAME**

Snelgrove Veterinary  
 Services

**REFERRING VET**

Dr. Ioannou

**INVOICE**

72544

**DATE**

1/28/26

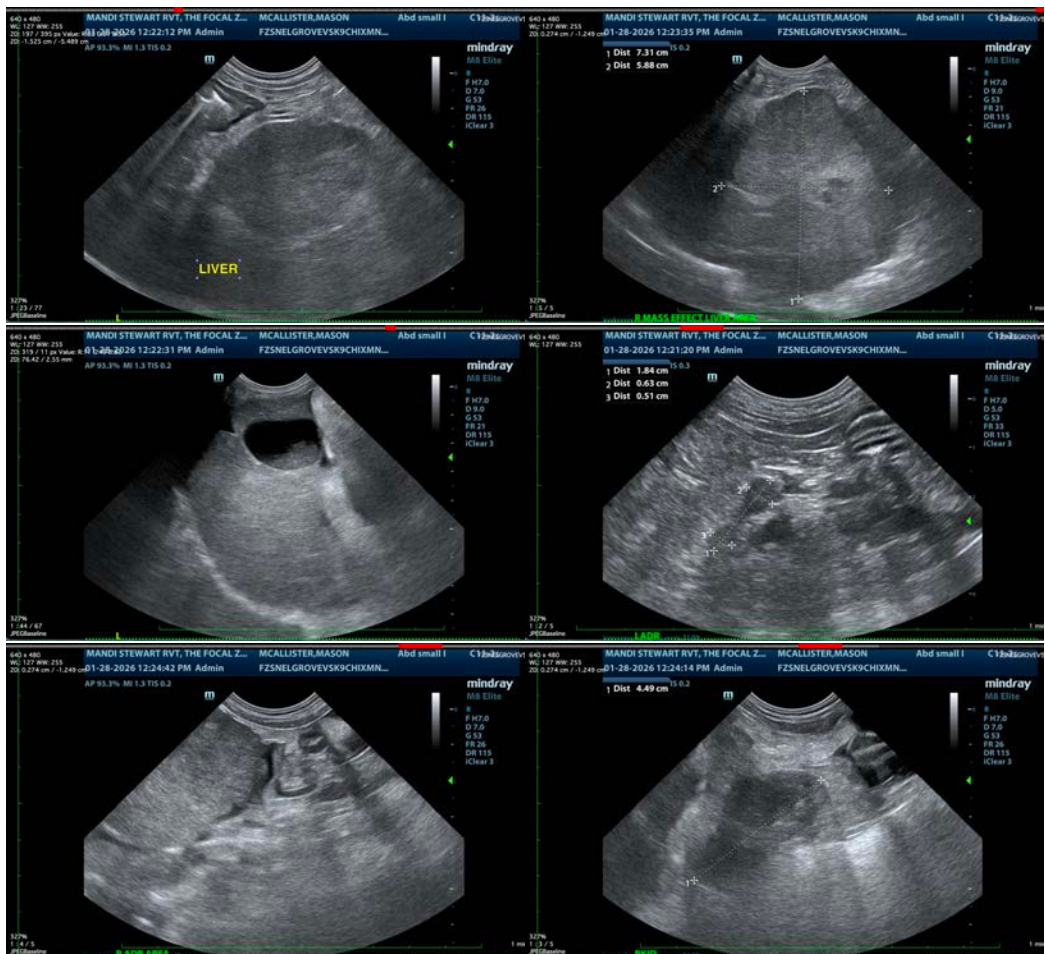
**INTERPRETATION OF THE FINDINGS & FURTHER RECOMMENDATIONS**

Three view thoracic radiographs are recommended for further assessment of cardio-pulmonary status as well as to further evaluate for any evidence of metastatic disease, if not recently evaluated.

Fine needle aspirates of the liver, including both the diffuse changes as well as the focal mass are recommended if patient's coagulation status is appropriate.

Additionally, sampling of the free abdominal fluid could be considered.

Other than supportive/symptomatic medical management of clinical signs, further treatment recommendations are largely dependent on results of the above.





**PATIENT**

Mason Mcallister

**SPECIES**

Canine

**BREED**

Chihuahua x

**SEX**

Neutered Male

**AGE**

12 Years

**WEIGHT**

5 kg

**INTERPRETED BY**

Beth Johnson, DVM  
DACVIM

**IMAGING PERFORMED BY**

Amanda Stewart

**HOSPITAL NAME**

Snelgrove Veterinary  
Services

**REFERRING VET**

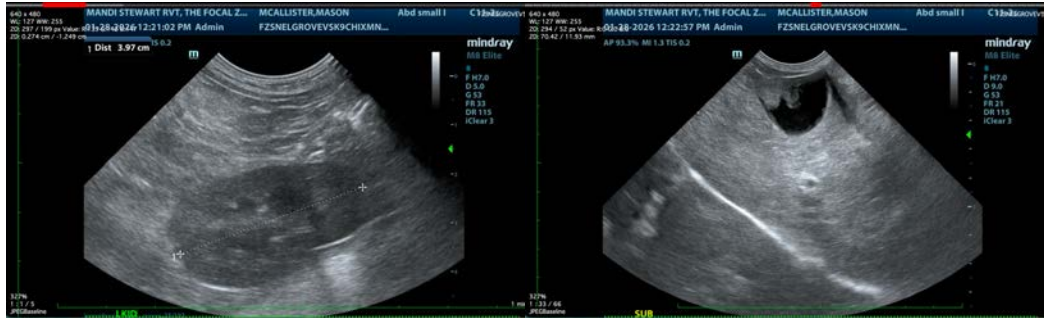Dr. Ioannou

**INVOICE**

72544

**DATE**

1/28/26



The information and recommendations provided are based on the images presented by the referring veterinarian/sonographer. No evaluation can be communicated regarding pathology that was not visible in the image/video clips provided.

Thank you for this referral. If the clinical or image interpretation does not parallel your findings or if I can be of any further assistance please contact me.

**Beth Johnson, DVM, DACVIM**  
info@sonopath.com