



## PATIENT

Gabby Stairs

## SPECIES

Canine

## BREED

Havanese

## SEX

Spayed Female

## AGE

8 Years

## WEIGHT

16 lbs

## INTERPRETED BY

Beth Johnson, DVM  
DACVIM

## IMAGING PERFORMED BY

Julia Bakker, DVM

## HOSPITAL NAME

Orange Blossom  
Veterinary Imaging

## REFERRING VET

Richard Hall, DVM

## INVOICE

72562

## DATE

1/28/26

## PRESENTING CLINICAL SIGNS

LIVER ELEVATIONS, RADIOGRAPHS SHOW ENLARGED LIVER ROUND BOARDERS.

Abnormal PE/Chem/CBC/UA Results: ALP 918 GGT 23 Chol 349

## ULTRASONOGRAPHIC EXAMINATION OF THE ABDOMEN

### *Urinary System*

The urinary bladder is adequately distended with anechoic contents. No masses, inflammatory changes, echogenic sediment or cystoliths are observed. The urinary bladder, trigone and visible pelvic urethra are normal in thickness with a smooth mucosal surface.

The right kidney is normal is size (4.89 cm), shape and echogenicity. It has smooth peripheral margination. There is a normal 1:3 cortex to medulla ratio with appropriate corticomedullary distinction. There is no evidence of pyelectasia or infarcts observed. Punctate non-obstructive nephroliths are noted.

The left kidney is normal is size (4.55 cm), shape and echogenicity. It has smooth peripheral margination. There is a normal 1:3 cortex to medulla ratio with appropriate corticomedullary distinction. There is no evidence of pyelectasia or infarcts observed. Punctate non-obstructive nephroliths are noted.

### *Adrenal Glands*

Adrenal glands are plump/swollen in size. Normal shape and contour are maintained without evidence of capsular invasion. Corticomedullary structure is unremarkable. Visible surrounding vasculature appears normal. Left measures 0.66 cm at the cranial pole and 0.84 cm at the caudal pole. Right measures 1.1 cm at the cranial pole and 0.83 cm at the caudal pole.

### *Spleen*

Spleen is subjectively normal in size with a normal smooth capsular contour. Parenchyma is appropriately finely textured and homogenous with normal echogenicity relative to surrounding tissue (hyperechoic to liver). Multifocal well-demarcated hyperechoic homogenous nodules are noted. Splenic vasculature appears normal.

### *Liver*

Liver is subjectively enlarged with mildly irregular margins. Parenchyma is moderately heterogenous characterized by multiple poorly defined hypoechoic nodules within otherwise hyperechoic liver parenchyma. Visible vasculature and biliary tree appear normal without distension or congestion

Gallbladder is moderately distended with anechoic bile as well as suspended and gravity dependent echogenic debris. The wall is smooth without visible thickening. There is no evidence of cystic or CBD dilation. There is no evidence of effusion or inflammation.

### *Gastrointestinal*

The visible stomach wall is normal in thickness and layering. The lumen of the stomach is empty with no evidence of obstruction, foreign material or infiltrative disease. Pyloric outflow tract appears patent.



## PATIENT

Gabby Stairs

## SPECIES

Canine

## BREED

Havanese

## SEX

Spayed Female

## AGE

8 Years

## WEIGHT

16 lbs

## INTERPRETED BY

Beth Johnson, DVM  
DACVIM

## IMAGING PERFORMED BY

Julia Bakker, DVM

## HOSPITAL NAME

Orange Blossom  
Veterinary Imaging

## REFERRING VET

Richard Hall, DVM

## INVOICE

72562

## DATE

1/28/26

The visible small intestines are normal in wall thickness and layering. Hyperechoic mucosal fogging or speckling is noted. Small intestinal motility appears adequate (1-3 contractions per min). The lumen of the small intestine is empty with no evidence of obstruction or foreign material.

The visible colon is normal in wall thickness (< 0.2 cm) and layering. Contents are consistent with normal formed feces and gas.

### **Pancreas**

The pancreas that is observed appears appropriately isoechoic to surrounding omental fat. Visible capsule is smooth and normal in contour. Visible pancreatic parenchyma is homogenous and unremarkable. There is no visible pancreatic duct dilation. There is no evidence of active peripancreatic inflammation.

### **Free Abdomen**

There is no visible free peritoneal effusion noted in these images.

There is no apparent pathologic lymphadenopathy noted in these images.

## PRIMARY FINDINGS

- Bilateral adrenomegaly – In a patient diagnosed with hyperadrenocorticism, this finding is most consistent with adrenal hyperplasia secondary to pituitary dependent hyperadrenocorticism. This finding can also be seen with stress and/or normal patient variant. Interpret in combination with clinical signs of hyperadrenocorticism and/or other adrenal disease.
- Moderately heterogenous liver – These changes are most consistent with benign processes such as nodular hyperplasia, steroid (vacuolar) hepatopathy, extramedullary hematopoiesis or possibly chronic inflammatory disease and less commonly infiltrative round cell or metastatic neoplasia.
- Moderate gallbladder debris - Cholecystic debris is of unknown clinical significance. It can be seen with biliary stasis from fasting or illness. Cholecystic debris is not necessarily related to hepatobiliary disease. Echogenic bile is most commonly an incidental finding in dogs and should be interpreted in combination with clinical signs such as nausea, inappetence, cranial abdominal discomfort and/or laboratory changes such as increased ALP and/or increased Tbili.
- Subtle/mild mucosal speckling – Mucosal speckling is often present with inflammatory bowel disease (IBD). It is not specific for type or severity of disease. Mild speckling change can occur as a normal patient variant in the post-prandial state.

## SECONDARY FINDINGS

- Punctate non-obstructive nephroliths bilaterally.
- Hyperechoic splenic nodules – most consistent with benign myelolipomas. Other differentials such as fibrosis or calcification caused by old hematomas or infarcts, chronic inflammation, granulomatous disease or metastatic disease cannot be ruled out, but are considered less likely.



**PATIENT**

Gabby Stairs

**SPECIES**

Canine

**BREED**

Havanese

**SEX**

Spayed Female

**AGE**

8 Years

**WEIGHT**

16 lbs

**INTERPRETED BY**

Beth Johnson, DVM  
DACVIM

**IMAGING PERFORMED BY**

Julia Bakker, DVM

**HOSPITAL NAME**

Orange Blossom  
Veterinary Imaging

**REFERRING VET**

Richard Hall, DVM

**INVOICE**

72562

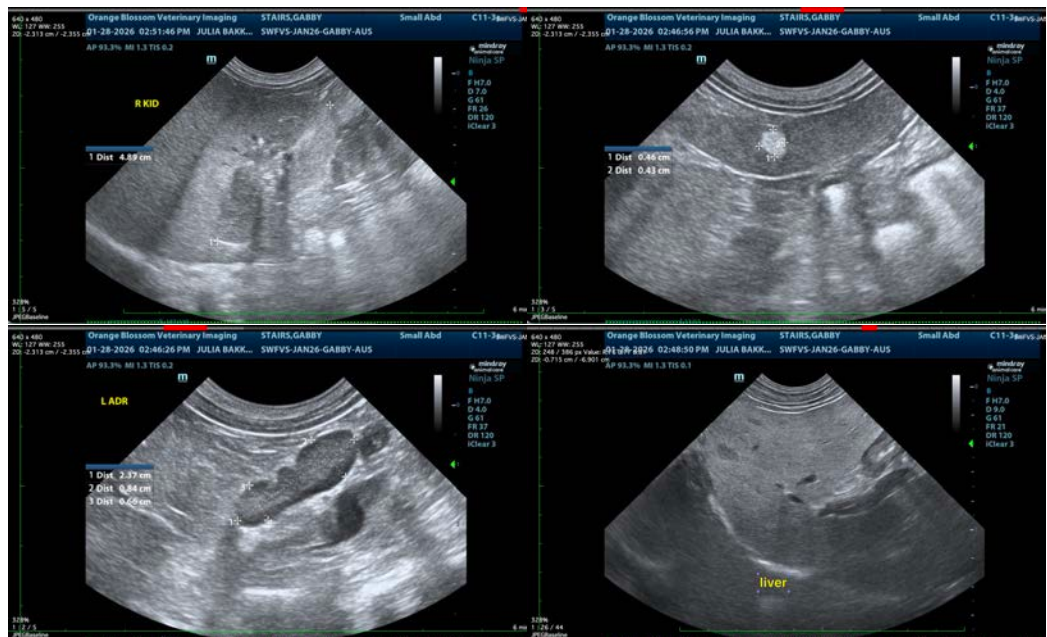**DATE**

1/28/26

**INTERPRETATION OF THE FINDINGS & FURTHER RECOMMENDATIONS**

Differentials for a primary cholestatic liver enzyme pattern (increased ALP) are vast and non-specific. Differentials include, but are not limited to, benign nodular hyperplasia which occurs in 70% of older dogs and often does not result in an abnormal ultrasound, reactive or idiopathic/vacuolar hepatopathy, cholestasis and/or hyperadrenocorticism as well as many chronic non-hepatobiliary diseases such as chronic infections/inflammation from dental disease, IBD, neoplasia, hyperlipidemia, hypothyroidism, chronic pancreatitis, chronic stress, etc.

- Especially given the mild bilateral adrenomegaly, adrenocortical testing such as a low dose dexamethasone suppression test could be considered if clinical signs of hyperadrenocorticism are present.
- Additionally, given patient's gallbladder debris, empirical hepatic nutraceuticals including Ursodiol could be considered while monitoring for improvement.
- A fine needle aspirate of the liver could be considered if patient's coagulation status is appropriate.
- Otherwise, recommendations include addressing any other concurrent disease and monitoring. If values are progressive, recheck imaging is recommended.





## PATIENT

Gabby Stairs

## SPECIES

Canine

## BREED

Havanese

## SEX

Spayed Female

## AGE

8 Years

## WEIGHT

16 lbs

## INTERPRETED BY

Beth Johnson, DVM  
DACVIM

## IMAGING PERFORMED BY

Julia Bakker, DVM

## HOSPITAL NAME

Orange Blossom  
Veterinary Imaging

## REFERRING VET

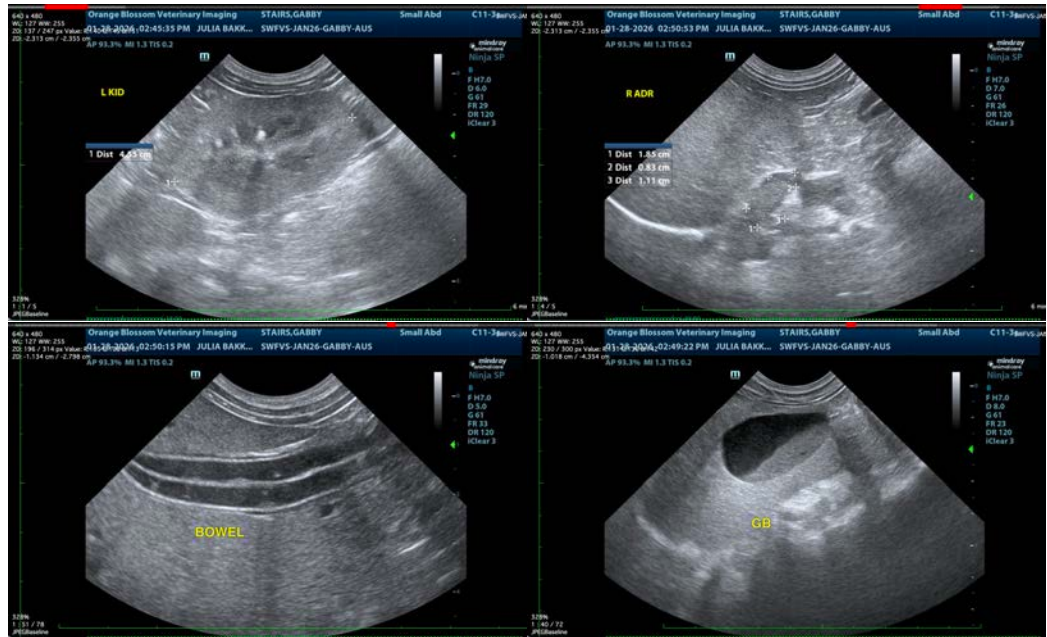
Richard Hall, DVM

## INVOICE

72562

## DATE

1/28/26



The information and recommendations provided are based on the images presented by the referring veterinarian/sonographer. No evaluation can be communicated regarding pathology that was not visible in the image/video clips provided.

Thank you for this referral. If the clinical or image interpretation does not parallel your findings or if I can be of any further assistance please contact me.

Beth Johnson, DVM, DACVIM  
info@sonopath.com