



**DATE PRESENTING CLINICAL SIGNS**

01/27/26 Patient History: Presents for potential FB.  
Current Medications: None listed.  
**PATIENT** Labwork Results: Labwork attached.  
Tank Selby Date of Previous IntraPet Ultrasound: No previous.  
Sedation: Not required to complete full diagnostic ultrasound.  
Stat Report: STAT requested.  
**SPECIES** Imaging Performed by: Rachel Brillhart, RDMS.

**Feline ULTRASONOGRAPHIC EXAMINATION OF THE ABDOMEN**

**BREED** *Urinary System*

DSH Urinary bladder is adequately distended with anechoic contents. No masses, inflammatory changes, echogenic sediment or cystoliths are observed. The urinary bladder, trigone and visible pelvic urethra are normal in thickness with a smooth mucosal surface.

**SEX**

Neutered Male Left kidney is small, normal and diffusely echogenic with decreased corticomedullary distinction and poor visualization of internal architecture. There is no pyelectasia noted and no mineral is observed. The left kidney measured 3.64 cm in length. A chronic infarct was noted at the cranial pole.

**AGE**

01/01/16 Right kidney is normal in size and shape with smooth peripheral margination. A normal 1:3 cortex to medulla ratio is maintained. The medulla and cortices are uniform in texture with some mild increased cortical echogenicity and mild loss of corticomedullary distinction, expected in this age patient. There is no evidence of pyelectasia, mineral or infarcts observed. The right kidney measures 4.29 cm.

**WEIGHT**

9.3 pounds

**Adrenal Glands**

**INTERPRETED BY** Left adrenal gland is normal in size (0.53 cm), shape and overall architecture, echogenicity and echotexture. Visible surrounding vasculature appears normal.  
Beth Johnson, DVM  
DACVIM Right adrenal gland is normal in size (0.56 cm), shape and overall architecture, echogenicity and echotexture. Visible surrounding vasculature appears normal.

**HOSPITAL NAME**

Homeward Bound  
Veterinary

**Spleen**

Spleen is subjectively normal in size with a normal smooth capsular contour. Parenchyma is appropriately finely textured and homogenous with normal echogenicity relative to surrounding tissue (hyperechoic to liver). No focal nodules or masses are observed. Splenic vasculature appears normal.

**REFERRING VET**

Dr. Vance

**Liver**

Liver is subjectively normal in size with normal smooth curvilinear peripheral contour. Parenchyma is appropriately hypoechoic to the spleen in echogenicity and appropriately mildly coarse and homogenous in echotexture. No focal lesions are observed. Visible vasculature and biliary tree appear normal without distension or congestion.

**INVOICE**

13413

Gallbladder is moderately distended with anechoic bile as well as suspended and gravity dependent echogenic debris. The wall is smooth without visible thickening. There is no evidence of cystic or CBD dilation. There is no evidence of effusion or inflammation.

### ***Gastrointestinal***

The visible stomach wall is normal in thickness and layering. The lumen of the stomach is mildly distended with primarily fluid as well as some echogenic non-shadowing luminal contents and gas consistent with normal chyme. There is no evidence of obstruction, foreign material, or infiltrative disease. Pyloric outflow tract appears patent.

The visible small intestines are normal in wall thickness and layering. Small intestinal motility appears adequate (1-3 contractions per min). The lumen of the small intestine is mildly distended with primarily fluid as well as some echogenic non-shadowing luminal contents and gas consistent with normal chyme. There is no evidence of obstruction, foreign material, or infiltrative disease.

The descending colon, cranial to the urinary bladder, has an approximately 2.5 cm long mass characterized by a coarse heterogeneous hypoechoic thick wall measuring approximately 0.8 cm thick with loss of layering. Cranial to the mass and caudal to the mass, the colon wall is normal in layering and thickness. The lumen of the colon is over distended with fluid and feces to the area of the thick mass beyond which is empty.

### ***Pancreas***

Pancreas is prominent (enlarged) in size, hypoechoic to surrounding tissue and has a mildly irregular undulating contour. Parenchyma is coarse with mixed echogenic remodeling noted. No pancreatic duct dilation is noted.

### ***Free Abdomen***

There is no visible free peritoneal effusion noted in these images.

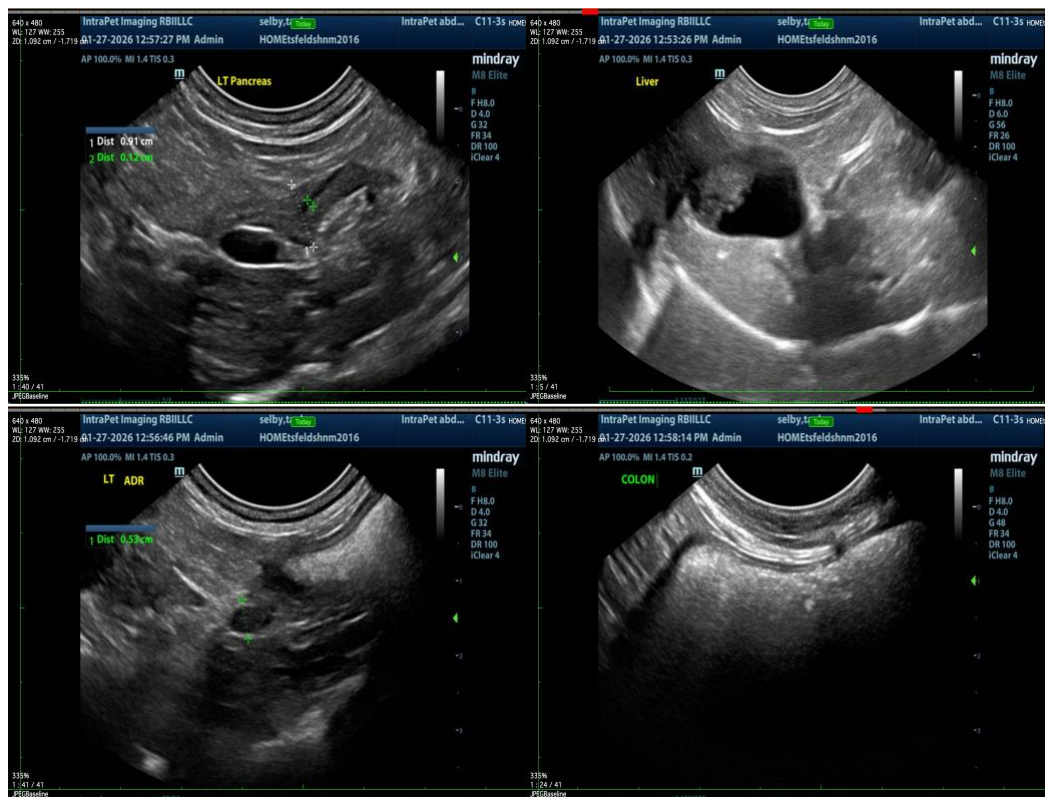
Adjacent to the colonic mass, reactive lymph nodes are prominent in size with swollen capsular contour. Normal elongated shape (length to width ratio) is maintained. There is no loss of parenchymal detail.

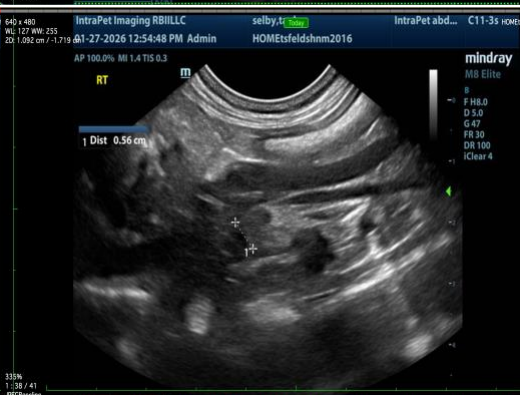
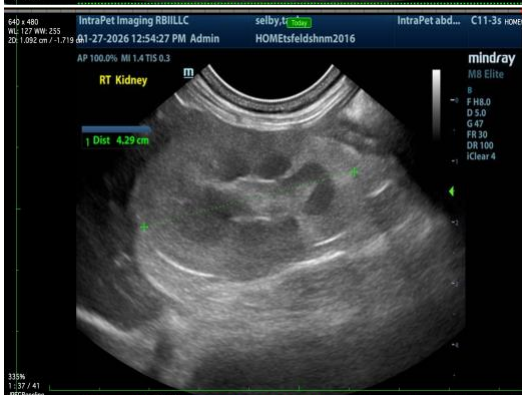
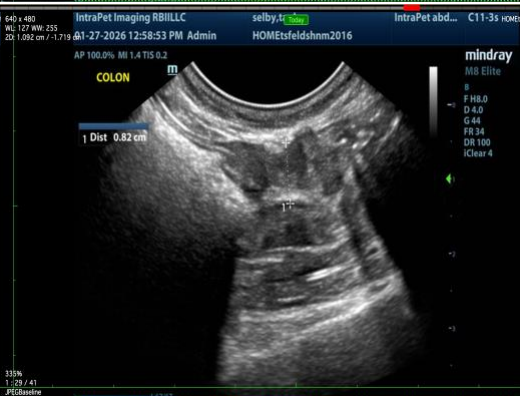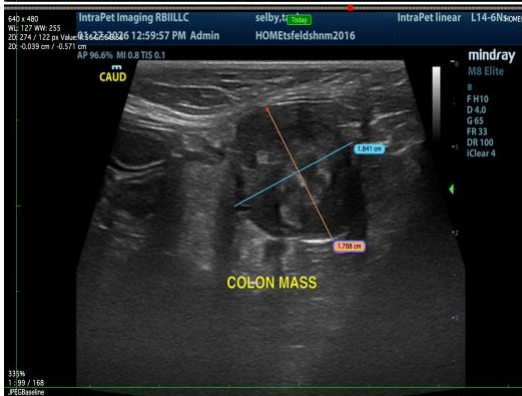
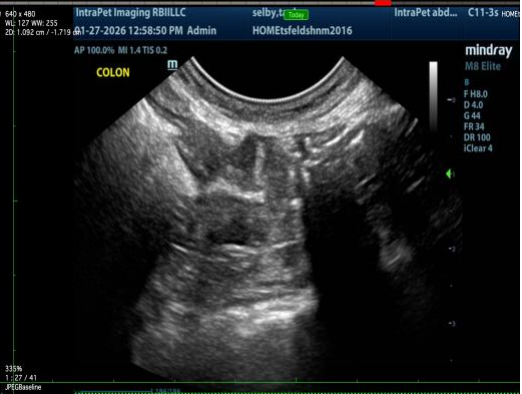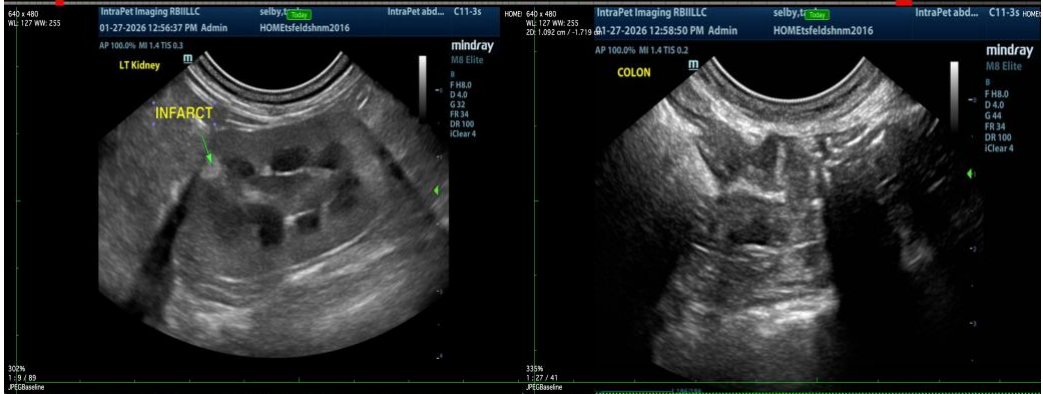### **ULTRASONOGRAPHIC FINDINGS**

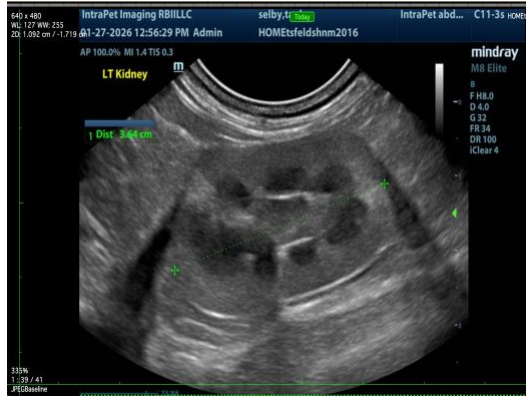- The mass within the mid-descending colon is concerning for infiltrative neoplasia such as carcinoma versus round cell neoplasia i.e. lymphoma versus other. Having said that, a benign inflammatory process cannot be ruled out without tissue sampling.
- Adjacent to the mass, reactive lymph nodes – infiltrative neoplastic disease cannot be ruled out but is considered less likely.
- Mild gallbladder debris- Cholecystic debris is of unknown clinical significance. It can be seen with biliary stasis from fasting or illness, however, it can also be associated with hepatobiliary disease in cats and should be interpreted in combination with clinical signs such as nausea, inappetence, cranial abdominal discomfort and/or laboratory changes such as increased ALP and/or increased Tbili.
- Mild chronic kidney disease changes including chronic infarct primarily in the left kidney.
- Chronic low-grade smoldering pancreatitis cannot be ruled out and should be suspected in the face of appropriate clinical signs.

### **INTERPRETATION OF THE FINDINGS & FURTHER RECOMMENDATIONS**

- There's no visible evidence of foreign material noted in these images at this time, however, the colonic mass appears at least partially obstructive based on dilated bowel proximal to the mass versus empty bowel distal to it. Recommendations include sampling of the mass. Fine needle aspirates can be considered if patient's coagulation status is appropriate or if a cytologic diagnosis is unable to be obtained, colonoscopy could be considered for further visual evaluation and biopsies.
- In the meantime, three view thoracic radiographs are recommended for further assessment of cardio-pulmonary status as well as to further evaluate for any evidence of metastatic disease, if not recently evaluated.
- Other than supportive/symptomatic medical management of clinical signs, further treatment recommendations are largely dependent on results of the above.







The information and recommendations provided are based on the images presented by the referring veterinarian/sonographer. No evaluation can be communicated regarding pathology that was not visible in the image/video clips provided.

Thank you for this referral. If the clinical or image interpretation does not parallel your findings or if I can be of any further assistance, please contact me.

**Beth Johnson, DVM DACVIM**

info@sonopath.com