



PATIENT

Sniper Jones

SPECIES

Canine

BREED

Lab x Beagle

SEX

Neutered Male

AGE

15 Years

WEIGHT

27.35 kg

INTERPRETED BY

Beth Johnson, DVM
DACVIM

IMAGING PERFORMED BY

Loetitia Saint-Jacques,
LVT

HOSPITAL NAME

Roundhill Animal
Hospital

REFERRING VET

Dr. Carl Kelly

INVOICE

72487

DATE

1/27/26

PRESENTING CLINICAL SIGNS

Has been on liver support medications since 2022. Was presented last week for front leg lameness, upon examination noticed the abdomen looks very large and difficult to palpate.

Last Bile Acids Liver panel test was done in May of 2025. ALP (994) ALT (217)

All other values including bile acids within normal range.

Current medications: -Librela 15mg on 1-13-26, -Ursodiol 250mg 1 tab sid, -L-Thyroxine 0.7mg 1 bid, -Zenrelia 22.5mg sid, -Ursodiol 250 mg sid

ULTRASONOGRAPHIC EXAMINATION OF THE ABDOMEN

Urinary System

Urinary bladder is adequately distended with primarily anechoic contents and occasional echogenic non-shadowing debris. Apical urinary bladder wall is diffusely thick (0.34 cm). Mucosa is hyperechoic and irregular. Closer to the trigone is an approximately 0.35 cm in diameter echogenic density protruding from the wall, possibly representing polyp/polypoid cystitis versus other. The trigone and visible pelvic urethra are normal thickness with a smooth mucosal surface.

Prostate is normal in size, echotexture and echogenicity for a neutered male.

Kidneys are overall normal in size and shape with smooth peripheral margination. A normal 1:3 cortex to medulla ratio is maintained. The medulla and cortices are uniform in texture with some mild increased cortical echogenicity and mild loss of corticomedullary distinction, expected in this age patient. There is no evidence of pyelectasia, mineral or infarcts observed. Left kidney measures 5.5 cm. Right kidney measures 6.3 cm. Cortical cysts are present bilaterally.

Adrenal Glands

Adrenal glands are plump/swollen in size. Normal shape and contour are maintained without evidence of capsular invasion. Corticomedullary structure is unremarkable. Visible surrounding vasculature appears normal. Left measures 1.1 cm at the cranial pole and 0.94 cm at the caudal pole. Right measures 1.0 cm at the cranial pole and 0.90 cm at the caudal pole. In the caudal pole of the right adrenal there is an approximately 0.60 cm in diameter hypo- to anechoic density.

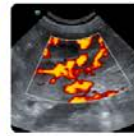
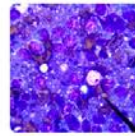
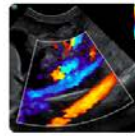
Spleen

The spleen is subjectively normal in size with a normal smooth capsular contour. Parenchyma is appropriately finely textured and homogenous with normal echogenicity relative to surrounding tissue (hyperechoic to liver), except for a non-capsule disrupting hypo- to anechoic density measuring 1.3 cm x 2.2 cm in size in the mid spleen, as well as a 2nd 2.2 cm x 3.2 cm more solid, iso- to hypoechoic mass resulting in a bulge off the medial aspect of the spleen. Splenic vasculature appears normal.

Liver

Liver is subjectively enlarged (swollen contour) with a diffusely mildly coarse architecture and subtly increased portal markings. Mildly mixed echogenic changes are noted diffusely. No focal lesions are observed. Visible vasculature and biliary tree appear normal without distension or congestion.

The gallbladder is non-distended in size. The wall is smooth without visible thickening. Luminal contents are primarily anechoic. There is no evidence of cystic or common bile duct dilation.



PATIENT

Sniper Jones

SPECIES

Canine

BREED

Lab x Beagle

SEX

Neutered Male

AGE

15 Years

WEIGHT

27.35 kg

INTERPRETED BY

Beth Johnson, DVM
DACVIM

IMAGING PERFORMED BY

Loetitia Saint-Jacques,
LVT

HOSPITAL NAME

Roundhill Animal
Hospital

REFERRING VET

Dr. Carl Kelly

INVOICE

72487

DATE

1/27/26

Gastrointestinal

The visible stomach wall is normal in thickness and layering. The lumen of the stomach is empty with no evidence of obstruction, foreign material or infiltrative disease. Pyloric outflow tract appears patent.

The visible small intestines are normal in wall thickness and layering. Small intestinal motility appears adequate (1-3 contractions per min). The lumen of the small intestine is empty with no evidence of obstruction, foreign material or infiltrative disease.

The visible colon is normal in wall thickness (< 0.2 cm) and layering except for in the mid descending colon where there is an approximately 0.80 cm mx 0.90 cm hypoechoic density protruding into the lumen. Contents are consistent with normal formed feces and gas.

Pancreas

The pancreas that is observed appears appropriately isoechoic to surrounding omental fat. Visible capsule is smooth and normal in contour. Visible pancreatic parenchyma is homogenous and unremarkable. There is no visible pancreatic duct dilation. There is no evidence of active peripancreatic inflammation.

Free Abdomen

There is no visible free peritoneal effusion noted in these images.

Mesenteric lymph nodes are prominent in size with swollen capsular contour. Normal elongated shape (length to width ratio) is maintained. There is no loss of parenchymal detail.

The visible heart base (RA) and pericardium are unremarkable without obvious pathology noted in these images at this time. If cardiac function evaluation is desired, a full echocardiogram is recommended.

PRIMARY FINDINGS

- An obvious cause for the mild to moderate liver changes is not identified in these images. Microscopic disease such as Leptospirosis, bacterial cholangiohepatitis, chronic active hepatitis, copper-associated hepatotoxicity, other hepatotoxicity, other reactive hepatopathy, infiltrative neoplasia, etc. cannot be definitively ruled out.
- Hypo to anechoic splenic nodules – could represent benign lesions such as cysts, hematomas, nodular hyperplasia, extramedullary hematopoiesis, etc., however, infiltrative neoplasia can mimic benign lesions and cannot be ruled out without tissue sampling.
- Bilateral adrenomegaly – In a patient diagnosed with hyperadrenocorticism, this finding is most consistent with adrenal hyperplasia secondary to pituitary dependent hyperadrenocorticism. This finding can also be seen with stress and/or normal patient variant. Interpret in combination with clinical signs of hyperadrenocorticism and/or other adrenal disease.
- The discrete hypoechoic nodule in the right adrenal gland could represent a benign or malignant process.
- Similarly, the density within the colon could represent a benign polyp or other benign inflammatory change, although an infiltrative neoplastic nodule/mass can't be ruled out without tissue sampling.



PATIENT

Sniper Jones

SPECIES

Canine

BREED

Lab x Beagle

SEX

Neutered Male

AGE

15 Years

WEIGHT

27.35 kg

INTERPRETED BY

Beth Johnson, DVM
DACVIM

IMAGING PERFORMED BY

Loetitia Saint-Jacques,
LVT

HOSPITAL NAME

Roundhill Animal
Hospital

REFERRING VET

Dr. Carl Kelly

INVOICE

72487

DATE

1/27/26

- Chronic Cystitis - Urinary bladder wall changes are most consistent with chronic cystitis. Infiltrative neoplasia cannot be ruled out but is considered less likely give the location and diffuse nature of the changes. Given the discrete echogenic density away from the apical thickness, infiltrative neoplasia can't be ruled out without additional information.

SECONDARY FINDINGS

- Age related kidney changes.
- Mild reactive mesenteric lymph nodes - infiltrative neoplastic disease cannot be ruled out but is considered less likely.

INTERPRETATION OF THE FINDINGS & FURTHER RECOMMENDATIONS

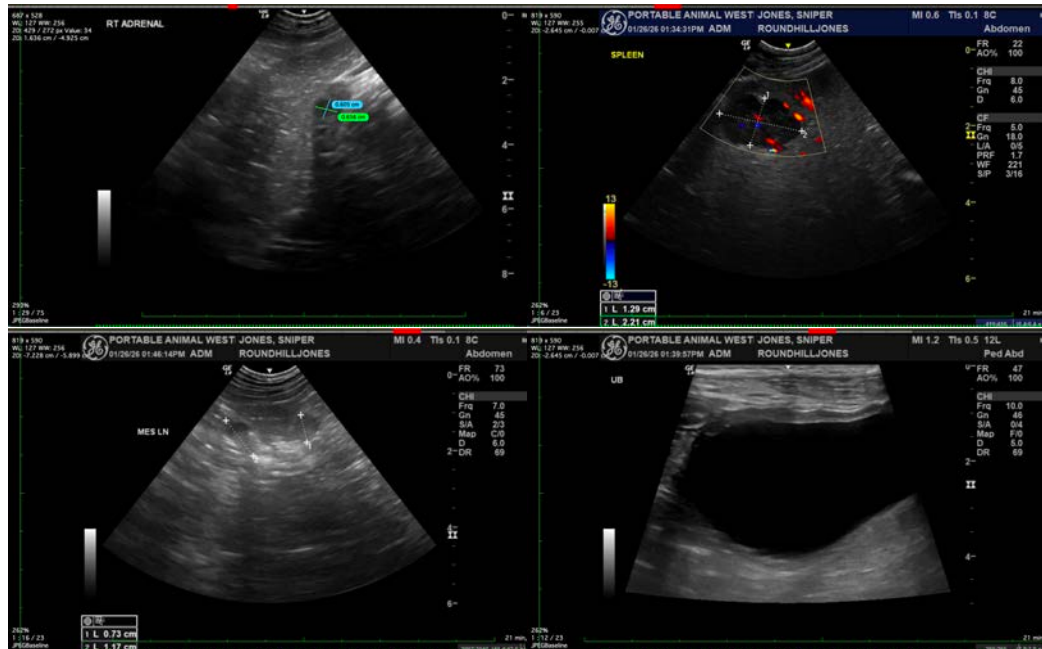
There are numerous subtle non-specific changes described above, any of which could be infiltrative neoplastic versus a combination of incidental age related changes. Therefore, further workup recommendations include:

Three view thoracic radiographs are recommended for further assessment of cardio-pulmonary status as well as to further evaluate for any evidence of metastatic disease, if not recently evaluated.

Tissue sampling could be considered, beginning with fine needle aspirates of the liver and spleen +/- the colon if patient's coagulation status is appropriate.

Submission of urine to look for BRAF gene mutation could be considered.

Having said that, likely none of the changes noted in this study today are related to patient's presenting complaint of front leg lameness. Therefore, further workup, intervention, etc. may in part be dictated by patient's overall clinical health.



Imaging performed by



pawsonography@gmail.com
530-786-8340



Clinical Sonography & Telectology
Educational Teleconsultation Services™

SonoPath

FOSTERING THE ART OF VETERINARY MEDICINE™

SonoPath.com info@sonopath.com 1.800.838.4268

PATIENT

Sniper Jones

SPECIES

Canine

BREED

Lab x Beagle

SEX

Neutered Male

AGE

15 Years

WEIGHT

27.35 kg

INTERPRETED BY

Beth Johnson, DVM
DACVIM

IMAGING PERFORMED BY

Loetitia Saint-Jacques,
LVT

HOSPITAL NAME

Roundhill Animal
Hospital

REFERRING VET

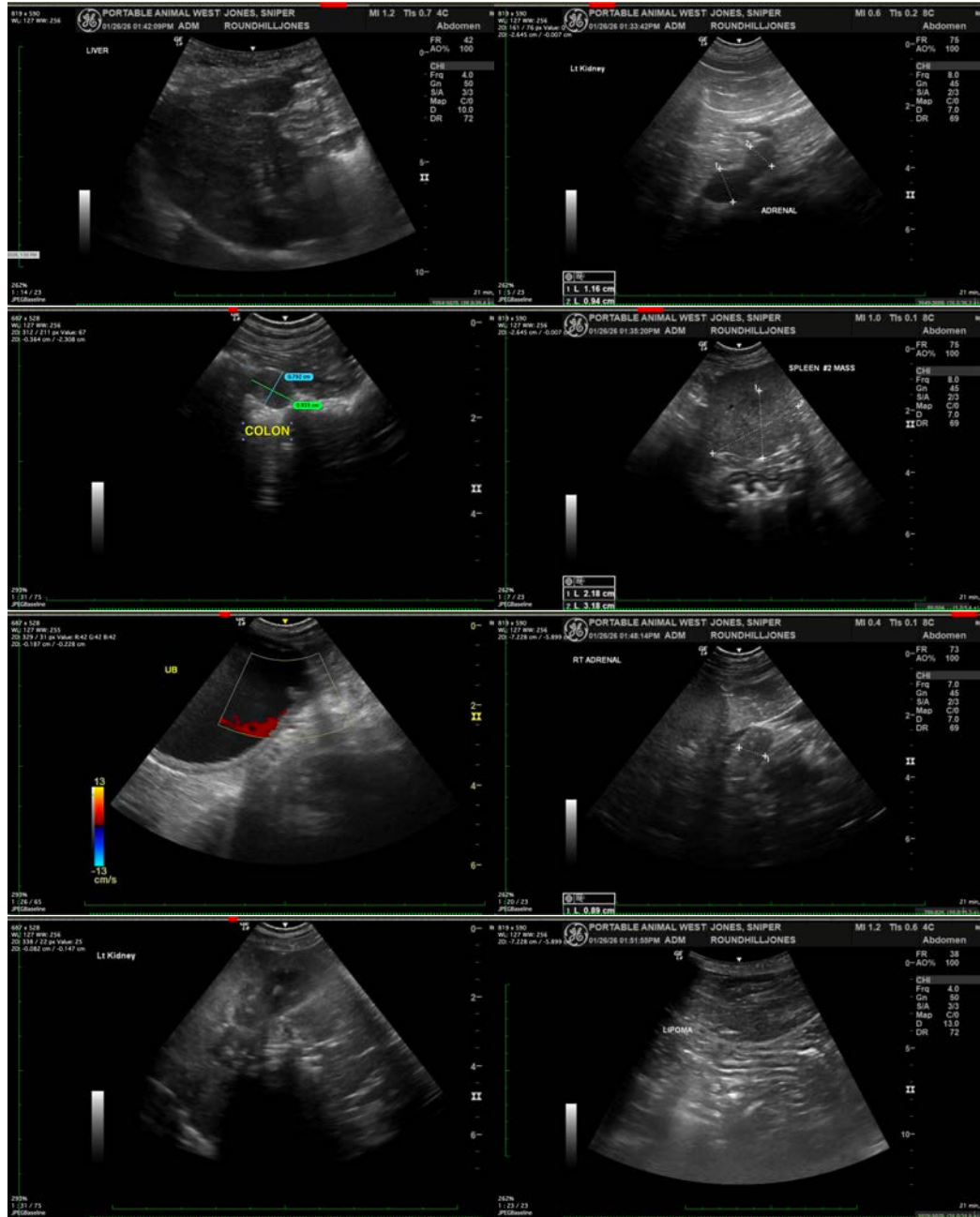
Dr. Carl Kelly

INVOICE

72487

DATE

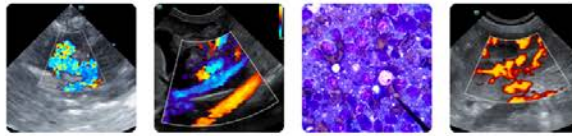
1/27/26



Imaging performed by



Roundhill Veterinary Sonography, Inc.
pawsonography@gmail.com
530-786-8340



Clinical Sonography & Telectology
Educational Teleconsultation Services™

SonoPath

FOSTERING THE ART OF VETERINARY MEDICINE™

SonoPath.com info@sonopath.com 1.800.838.4268

PATIENT

Sniper Jones

SPECIES

Canine

BREED

Lab x Beagle

SEX

Neutered Male

AGE

15 Years

WEIGHT

27.35 kg

INTERPRETED BY

Beth Johnson, DVM
DACVIM

IMAGING PERFORMED BY

Loetitia Saint-Jacques,
LVT

HOSPITAL NAME

Roundhill Animal
Hospital

REFERRING VET

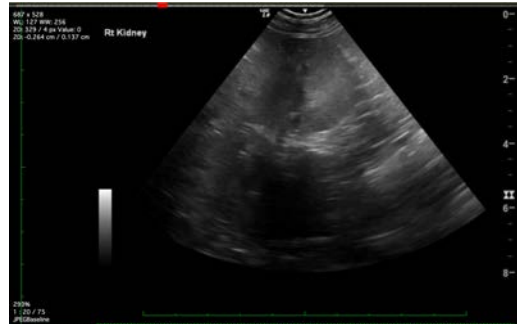Dr. Carl Kelly

INVOICE

72487

DATE

1/27/26



The information and recommendations provided are based on the images presented by the referring veterinarian/sonographer. No evaluation can be communicated regarding pathology that was not visible in the image/video clips provided.

Thank you for this referral. If the clinical or image interpretation does not parallel your findings or if I can be of any further assistance please contact me.

Beth Johnson, DVM, DACVIM
info@sonopath.com