

PATIENT PRESENTING CLINICAL SIGNS

Riggs Arnott

SPECIES

Canine

BREED

Husky X

SEX

Neutered Male

AGE

12 Years

WEIGHT

33.6 kg

INTERPRETED BY

Beth Johnson, DVM,
 DACVIM (SAIM)

IMAGING PERFORMED BY

Amanda Stewart

HOSPITAL NAME

Yates VH

REFERRING VET

Dr. Merkel

INVOICE

35599

DATE

1/27/26

- Noted at Annual PE Nov 10 that pet would experience occasional borborygmus and soft stools. At this time noted approx 1/month and not bothering pet. PE was unremarkable beyond a gingival mass.
- Dec 23 client reports persistent watery stools for several days. Started on a 10 day course of Fortiflora and RC Gastro. No improvement noted
- BW performed Jan 6 shows mild eosinophilia and lipase. Gingival mass removed (no histo). Was comfortable with abd palp. Discharged with metronidazole and I/d Low fat. No improvement
- Fecal w giardia negative Jan 14
- Tried to transition to EN Jan 21st - pet refuses to eat, but now wont eat any kibble/canned food. Still hungry and will eat cooked meat, some rice/sweet potato
- PE Jan 23 unremarkable, has lost 5kg since Nov
- Started on TMS and 5 days Panacur
- Current Medications: Trimethoprim 80mg & 400mg BID Sulfamethoxazole, Panacur 50mg/kg SID Q5 days.
- New meds today: 22mg/kg Ampicillin IV BID, 800mg SAME and Cerenia

ULTRASONOGRAPHIC EXAMINATION OF THE ABDOMEN

Urinary System

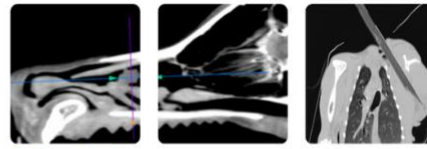
Urinary bladder is adequately distended. It has a normal uniform wall thickness. Contents include primarily anechoic fluid with a moderate amount of echogenic non-shadowing debris, most consistent with exfoliated cells, mucous and/or small blood clots. Both sterile inflammation as well as urinary tract infection can present with echogenic debris. No masses or cystoliths are observed. The trigone and visible pelvic urethra are normal in thickness with a smooth mucosal surface.

Prostate is normal in size, echotexture and echogenicity for a neutered male.

Left kidney is normal in size (7.01 cm), shape and echogenicity. It has smooth peripheral margination. There is a normal 1:3 cortex to medulla ratio with appropriate corticomedullary distinction. There is no evidence of pyelectasia, mineral or infarcts observed.

Right kidney is normal in size (6.96 cm), shape and echogenicity. It has smooth peripheral margination. There is a normal 1:3 cortex to medulla ratio with appropriate corticomedullary distinction. There is no evidence of pyelectasia, mineral or infarcts observed.

Adrenal Glands



PATIENT

Riggs Arnott

Left adrenal gland is normal in size (0.59 cm at cranial pole and 0.68 cm at caudal pole), shape and overall architecture, echogenicity and echotexture. Visible surrounding vasculature appears normal.

SPECIES

Canine

Right adrenal gland is normal in size (0.8 cm at cranial pole and 0.61 cm at caudal pole), shape and overall architecture, echogenicity and echotexture. Visible surrounding vasculature appears normal.

BREED

Husky X

Spleen

Spleen is subjectively normal in size with a normal smooth capsular contour. Parenchyma is appropriately finely textured and homogenous with normal echogenicity relative to surrounding tissue (hyperechoic to liver). No focal nodules or masses are observed. Splenic vasculature appears normal.

SEX

Neutered Male

Liver

Liver is subjectively enlarged (swollen contour) with a diffusely mildly coarse architecture and subtly increased portal markings. Mildly mixed echogenic changes are noted diffusely. No focal lesions are observed. Visible vasculature and biliary tree appear normal without distension or congestion.

AGE

12 Years

Gallbladder is non-distended in size. The wall is smooth without visible thickening. Luminal contents are primarily anechoic. There is no evidence of cystic or common bile duct dilation.

WEIGHT

33.6 kg

Gastrointestinal

The visible stomach wall is normal in thickness and layering. The lumen of the stomach is empty with no evidence of obstruction, foreign material or infiltrative disease. Pyloric outflow tract appears patent.

INTERPRETED BY

Beth Johnson, DVM,
 DACVIM (SAIM)

The visible small intestine demonstrates areas of moderate to severely thick muscularis layer relative to mucosa (disruption of the normal 1:3 muscularis:mucosa ratio). Small intestinal submucosa is slightly irregular, thick and hyperechoic, without evident loss of layering appreciated. The lumen of the small intestine is mildly distended with primarily fluid as well as some echogenic non-shadowing luminal contents and gas consistent with normal chyme. There is no evidence of obstruction, foreign material, or infiltrative disease.

IMAGING PERFORMED BY

Amanda Stewart

The visible colon is normal in wall thickness (< 0.2 cm) and layering. Contents are consistent with normal formed feces and gas.

HOSPITAL NAME

Yates VH

Pancreas

The pancreas that is observed appears appropriately isoechoic to surrounding omental fat. Visible capsule is smooth and normal in contour. Visible pancreatic parenchyma is homogenous and unremarkable. There is no visible pancreatic duct dilation. There is no evidence of active peripancreatic inflammation.

REFERRING VET

Dr. Merkel

INVOICE

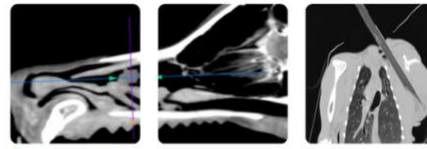
35599

Free Abdomen

There is a trace amount of anechoic free fluid, primarily in the cranial abdomen between the liver lobes. Additionally, diffusely, largely throughout the cranial and mid abdomen, is enhanced hyperechoic mesenteric fat and omentum. Additionally, multifocally throughout the abdomen, there are enlarged round hypo- to almost anechoic (in some locations) appearing structures that I believe are lymph nodes, but fluid filled cystic structures can't be ruled out. One representative density in the caudal abdomen measures 2.7 cm x 2.8 cm in size. Other measurements are provided in the images.

DATE

1/27/26



PATIENT ULTRASONOGRAPHIC FINDINGS

Riggs Arnott

Primary Findings

SPECIES

Canine

BREED

Husky X

SEX

Neutered Male

AGE

12 Years

WEIGHT

33.6 kg

INTERPRETED BY

Beth Johnson, DVM,
 DACVIM (SAIM)

IMAGING PERFORMED BY

Amanda Stewart

HOSPITAL NAME

Yates VH

REFERRING VET

Dr. Merkel

INVOICE

35599

DATE

1/27/26

- Suspect diffuse aggressive lymphadenopathy– concerning for infiltrative round cell or metastatic neoplasia. A benign aggressive inflammatory response cannot be ruled out without tissue sampling +/- culture. Having said this, however, as described above, fluid filled cystic structures versus lymph nodes can't be definitively ruled out, with both benign and malignant differentials for fluid filled densities as well as if they're solid.
- Moderate inflammatory bowel disease pattern- Thick muscularis has been reported with infiltrative bowel disease including both benign inflammatory disease as well as infiltrative neoplasia such as lymphoma. No loss of layering or distinct characteristics of malignancy are present. Therefore, differentials cannot be further ranked without tissue sampling.
- An obvious cause for the moderate liver changes is not identified in these images. Microscopic disease such as Leptospirosis, bacterial cholangiohepatitis, chronic active hepatitis, copper-associated hepatotoxicity, other hepatotoxicity, other reactive hepatopathy, infiltrative neoplasia, etc. cannot be definitively ruled out.
- Mild free fluid is of unknown origin. Differentials (unless already ruled out) could include increased hydrostatic pressure (cardiac disease and/or vascular or lymph blockage), decreased oncotic pressure (low albumin), vasculitis, paraneoplastic fluid, rupture/leakage of/from an organ (GI, GB, UB, other), blood (hemoabdomen), other.
- The diffuse, primarily cranial abdominal enhanced hyperechoic fat is a nonspecific finding, but suggestive of focal peritonitis, potentially secondary to infiltrative bowel disease versus chronic low grade smoldering pancreatitis, hepatic disease, the lymphadenopathy, versus other.

Secondary Findings

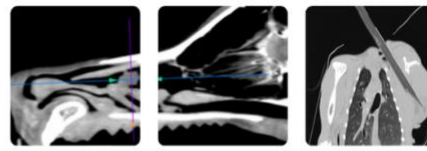
- A moderate amount of echogenic urinary bladder debris.

INTERPRETATION OF THE FINDINGS & FURTHER RECOMMENDATIONS

- Three view thoracic radiographs are recommended for further assessment of cardio-pulmonary status as well as to further evaluate for any evidence of metastatic disease, if not recently evaluated.
- Tissue sampling is recommended. Fine needle aspirates of the liver, as well as the multifocal enlarged hypo- to anechoic structures/suspect lymph nodes, are recommended if patient's coagulation status is appropriate.

In the meantime, given the patient's history and eosinophilia, etc., additionally, if a cytologic diagnosis is not obtained:

- A baseline cortisol is recommended. If baseline cortisol is less than 2, a full ACTH stimulation test is recommended to rule out hypoadrenocorticism.
- A gastrointestinal malabsorption panel (including cobalamin, folate, TLI and PLI) to Texas A&M GI Laboratory is recommended for further evaluation of GI and pancreatic function.



PATIENT

Riggs Arnott

- A fecal enteropathogen PCR panel to Texas A&M GI Laboratory could be considered for further evaluation of possible infectious disease. Contact lab for recommendations on how long to discontinue antibiotics (if indicated) prior to obtaining a stool sample for submission.

SPECIES

Canine

In the meantime, supportive/symptomatic medical management of clinical signs is recommended, including a probiotic (such as visbiome or proviable), empirical deworming with a 5-day course of Panacur and, if tolerated, a transition in diet, based on trial-and-error response, beginning possibly with a gastrointestinal biome diet vs a hydrolyzed protein diet vs other. Some patients respond to one brand/version of a hydrolyzed protein diet better than another brand, so several brand attempts may be required.

BREED

Husky X

SEX

Neutered Male

AGE

12 Years

WEIGHT

33.6 kg

INTERPRETED BY

Beth Johnson, DVM,
 DACVIM (SAIM)

IMAGING PERFORMED BY

Amanda Stewart

HOSPITAL NAME

Yates VH

REFERRING VET

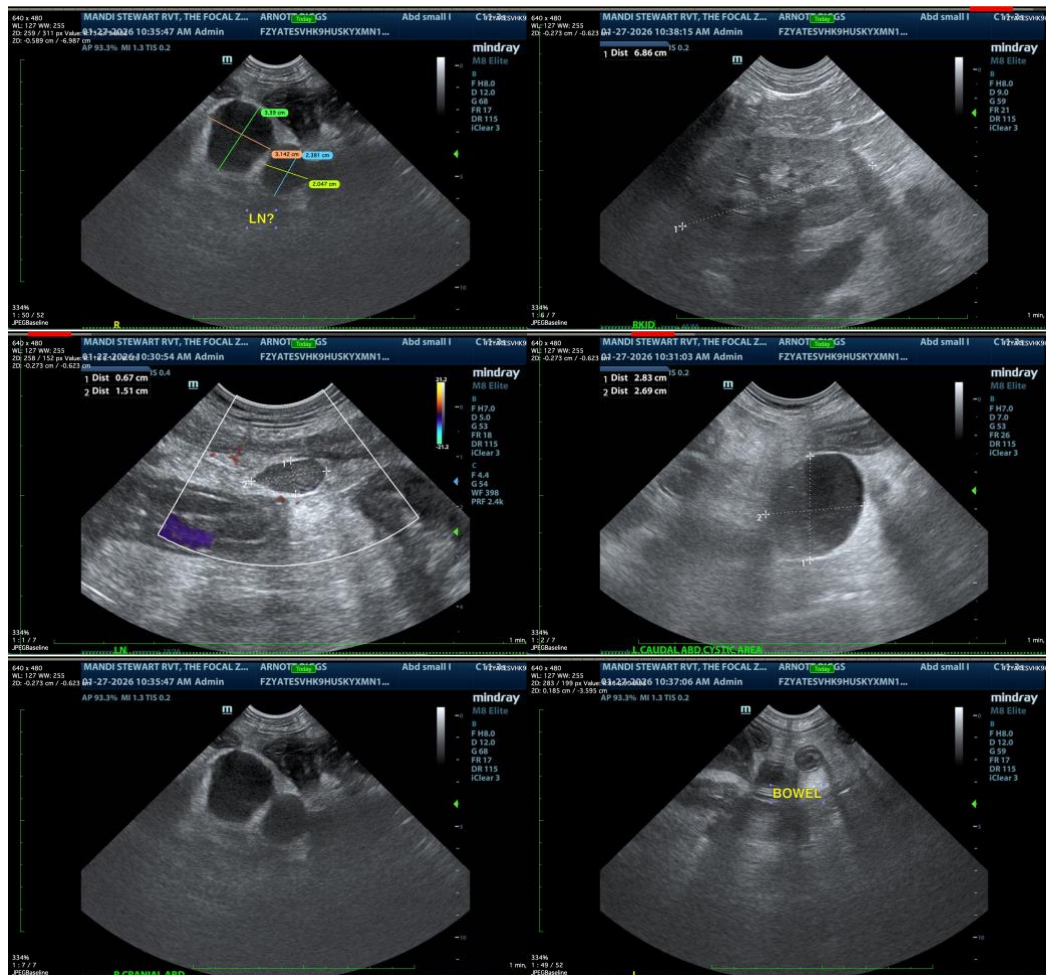
Dr. Merkel

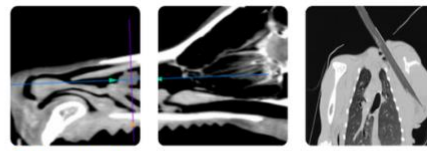
INVOICE

35599

DATE

1/27/26





PATIENT

Riggs Arnott

SPECIES

Canine

BREED

Husky X

SEX

Neutered Male

AGE

12 Years

WEIGHT

33.6 kg

INTERPRETED BY

Beth Johnson, DVM,
 DACVIM (SAIM)

IMAGING PERFORMED BY

Amanda Stewart

HOSPITAL NAME

Yates VH

REFERRING VET

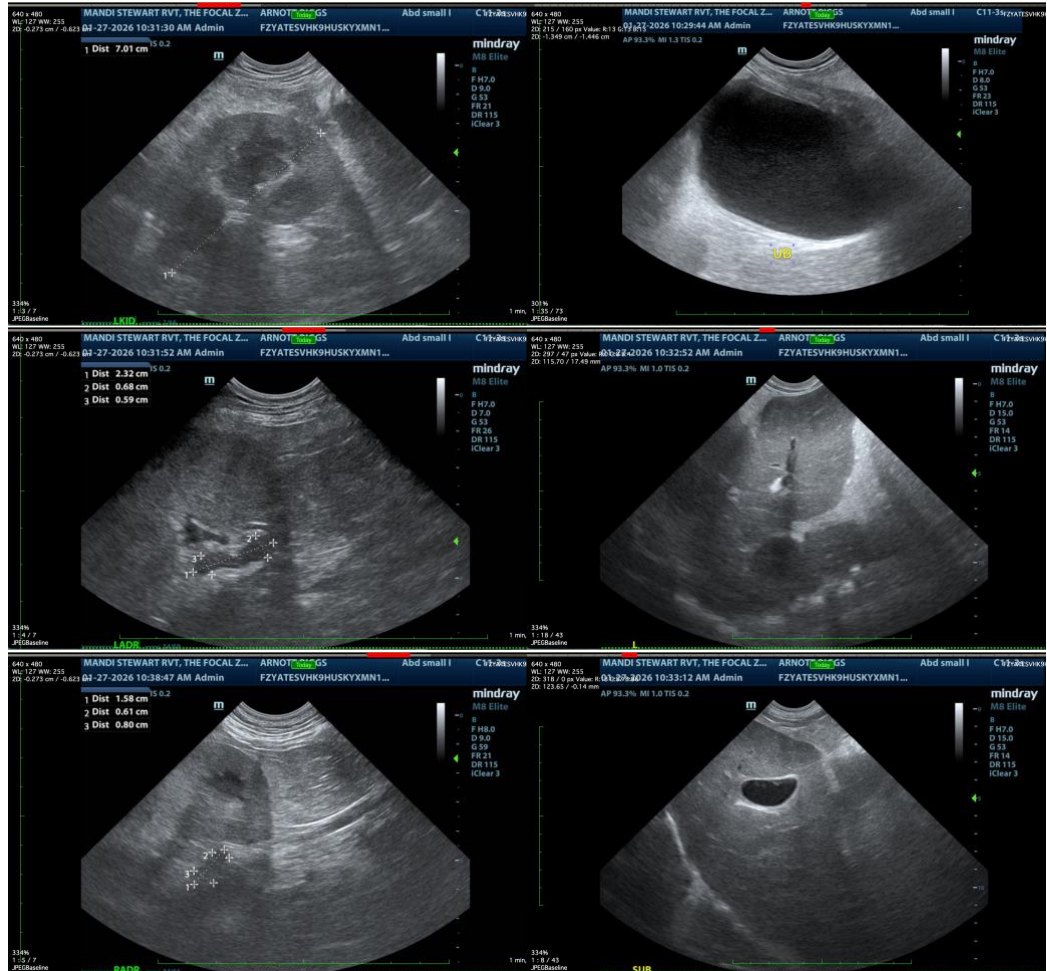
Dr. Merkel

INVOICE

35599

DATE

1/27/26



The information and recommendations provided are based on the images presented by the referring veterinarian/sonographer. No evaluation can be communicated regarding pathology that was not visible in the image/video clips provided.

Thank you for this referral. If the clinical or image interpretation does not parallel your findings or if I can be of any further assistance please contact me.

Beth Johnson, DVM DACVIM

info@sonopath.com