

**DATE PRESENTING CLINICAL SIGNS**

1/27/2026

**Patient History:** Last ate Sunday evening; anorexic for approximately 36 hours - Muscle spasms/tremors noted this morning - Painful on palpation and movement with vocalization - Polydipsia - History of anal gland abscess rupture several months ago(resolved) - History of anxiety -being monitor for potential kidney disease - Indoor only - No coughing, sneezing, vomiting, or diarrhea - No known toxin exposure - Lives with another cat and a dog. PE- Depressed/crying T- 95.0; HR- 120; painful abdomen. AFAST- small pockets of FF; concern for soft tissue/cavitated lesion noted on AFAST. TFAST- possible trace pleural effusion

**PATIENT**

Merlin Cannon

**SPECIES**

Feline

**Current Medications:** Buprenorphine.

**BREED**

DSH

**Labwork Results:** Labwork attached, reported as: PCV- 19/6.3, BG- 115- full labwork is attached; xrays attached.

**SEX**

Neutered Male

**Date of Previous IntraPet Ultrasound:** No previous.

**Sedation:** Not required to complete full diagnostic ultrasound.

**Stat Report:** STAT requested.

**AGE**

11 years

**Imaging Performed by:** Rachel Brillhart, RDMS.

**ULTRASONOGRAPHIC EXAMINATION OF THE ABDOMEN**

**WEIGHT**

12 lbs

**Urinary System**

Urinary bladder is adequately distended. It has a normal uniform wall thickness. Contents include primarily anechoic fluid with occasional echogenic non-shadowing debris, most consistent with incidental suspended lipid in a cat, possibly combined with exfoliated cells, mucous and/or small blood clots. Both sterile inflammation as well as urinary tract infection can also present with echogenic debris. No masses or definitive cystoliths are observed. The trigone and visible pelvic urethra are normal in thickness with a smooth mucosal surface.

**INTERPRETED BY**

Beth Johnson, DVM  
DACVIM

The right kidney is normal is size (4.29 cm), shape and echogenicity. It has smooth peripheral margination. There is a normal 1:3 cortex to medulla ratio with appropriate corticomedullary distinction. There is no evidence of pyelectasia, mineral or infarcts observed.

**HOSPITAL NAME**

Animal Emergency  
Hospital

**REFERRING VET**

Dr. Willer

The left kidney is normal is size (4.21 cm), shape and echogenicity. It has smooth peripheral margination. There is a normal 1:3 cortex to medulla ratio with appropriate corticomedullary distinction. There is no evidence of pyelectasia, mineral or infarcts observed.

**Adrenal Glands**

**INVOICE**

11182

The right adrenal gland is normal in size (0.6 cm), shape and overall architecture, echogenicity and echotexture. Visible surrounding vasculature appears normal.

The left adrenal gland is normal in size (0.4 cm), shape and overall architecture, echogenicity and echotexture. Visible surrounding vasculature appears normal.

**Spleen**

The spleen is an expansive mixed partially cystic/anechoic, irregularly shaped mass measuring approximately 8.0 cm long x 3.5 cm thick.

### ***Liver***

The liver is subjectively normal in size with normal smooth curvilinear peripheral contour. Parenchyma is appropriately hypoechoic to the spleen in echogenicity and appropriately mildly coarse and homogenous in echotexture. No focal lesions are observed. Visible vasculature and biliary tree appear normal without distension or congestion.

The gallbladder is non-distended in size. The wall is smooth without visible thickening. Luminal contents are primarily anechoic. There is no evidence of cystic or common bile duct dilation.

### ***Gastrointestinal***

The visible stomach wall is normal in thickness and layering. The lumen of the stomach is empty with no evidence of obstruction, foreign material or infiltrative disease. Pyloric outflow tract appears patent.

The visible small intestines are normal in wall thickness and layering. Small intestinal motility appears adequate (1-3 contractions per min). The lumen of the small intestine is empty with no evidence of obstruction, foreign material or infiltrative disease.

The visible colon is normal in wall thickness (< 0.2 cm) and layering. Contents are consistent with normal formed feces and gas.

### ***Pancreas***

Pancreas is prominent (enlarged) in size, hypoechoic to surrounding tissue and has a mildly irregular undulating contour. Parenchyma is coarse with mixed echogenic remodeling noted. No pancreatic duct dilation is noted.

### ***Free Abdomen***

There is a moderate amount of free fluid noted in these images.

There is no apparent pathologic lymphadenopathy noted in these images.

In the mid cranial abdomen, there's approximately a 2.1 cm x 2.2 cm largely anechoic to almost hypoechoic appearing round density that's difficult to associate with any particular organ.

### **PRIMARY FINDINGS**

- The mixed, partially cavitated splenic mass is concerning for infiltrative neoplasia such as round cell neoplasia versus sarcoma versus other. Especially given the concurrent free fluid. A benign lesion such as hematomas, extramedullary hematopoiesis, even amyloidosis versus other, can't be ruled out however, without tissue sampling.

- The difficult to vocalize/identify cranial abdominal density/nodule/mass could represent the same etiology, potentially metastatic lesion, although other, again benign, cysts, hematoma, even abscess, etc. can't be ruled out without tissue sampling.

## SECONDARY FINDINGS

- Chronic low grade smoldering pancreatitis can't be ruled out and should be suspected in the face of appropriate clinical signs.
- A mild amount of echogenic urinary bladder debris.

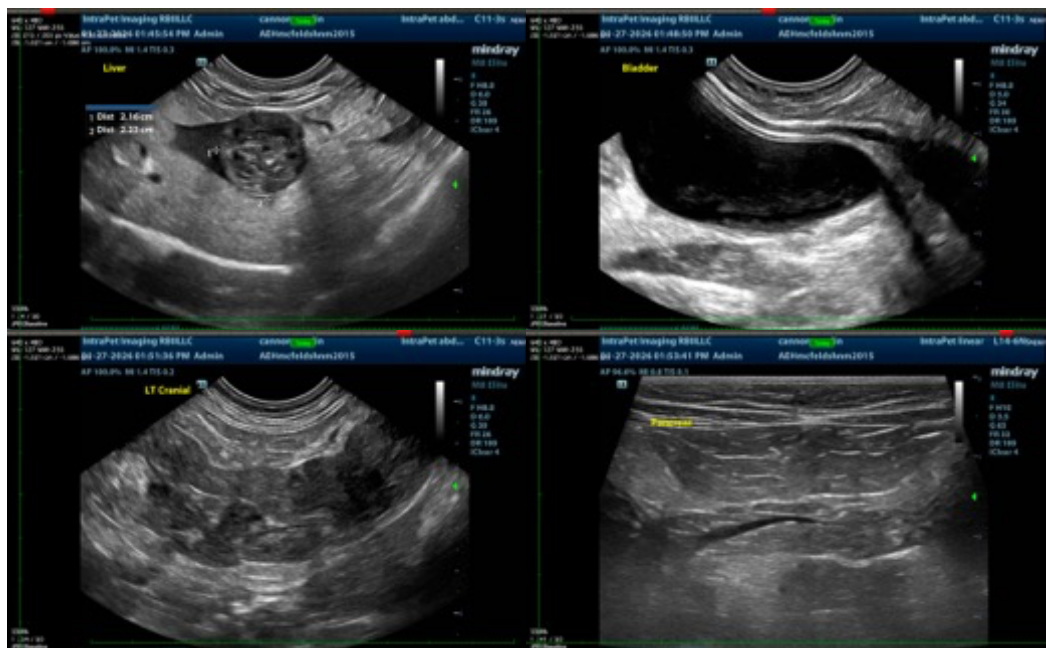
## INTERPRETATION OF THE FINDINGS & FURTHER RECOMMENDATIONS

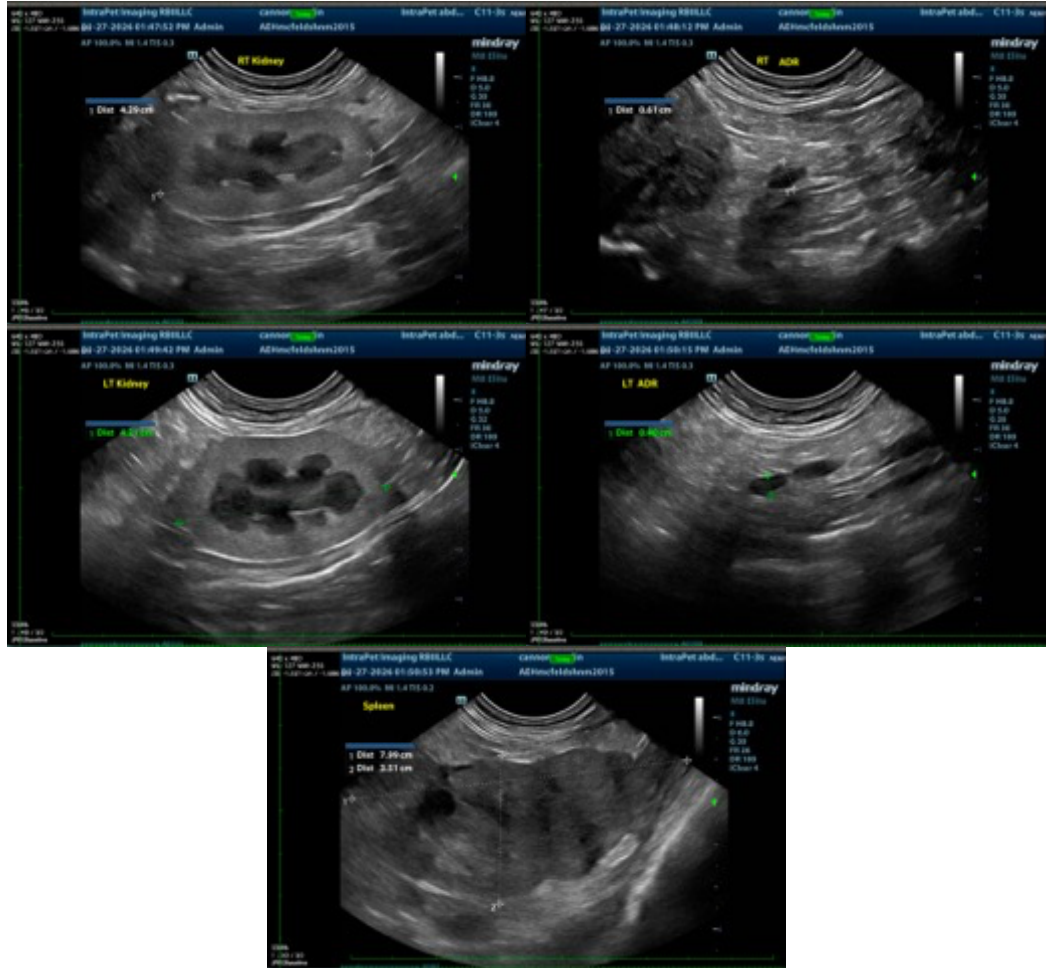
Three view thoracic radiographs are recommended for further assessment of cardio-pulmonary status as well as to further evaluate for any evidence of metastatic disease, if not recently evaluated.

Fine needle aspirates of the cranial abdominal mass, the spleen, as well as sampling of the free abdominal fluid, are recommended if patient's coagulation status is appropriate.

Additionally, and/or potentially, alternatively, advanced imaging of both the thorax and abdomen such as contrast CT scans, could be considered for further staging and identification especially of the mid to left cranial density.

Other than supportive/symptomatic medical management of clinical signs, further treatment recommendations are largely dependent on results of the above.





The information and recommendations provided are based on the images presented by the referring veterinarian/sonographer. No evaluation can be communicated regarding pathology that was not visible in the image/video clips provided.

Thank you for this referral. If the clinical or image interpretation does not parallel your findings or if I can be of any further assistance please contact me.

**Beth Johnson, DVM, DACVIM**  
info@sonopath.com