



DATE PRESENTING CLINICAL SIGNS

1-27-26 Weight loss, possible decreased appetite, suspected vomiting, electrolyte abnormalities. Known to eat hair.

PATIENT Labwork not submitted. Reported as Cr 2.3, BUN 65, Na 143, K 2.8, Cl 100, TP 9.6, globs 6.

Max Haynes

ULTRASONOGRAPHIC EXAMINATION OF THE ABDOMEN

SPECIES *Urinary System*

Feline Urinary bladder is adequately distended with anechoic contents. No masses, inflammatory changes, echogenic sediment or cystoliths are observed. The urinary bladder, trigone and visible pelvic urethra are normal in thickness with a smooth mucosal surface.

BREED

DSH Left kidney is normal in size (4.13 cm), shape and echogenicity. It has smooth peripheral margination. There is a normal 1:3 cortex to medulla ratio with appropriate corticomedullary distinction. There is no evidence of pyelectasia, mineral or infarcts observed.

SEX

MN Right kidney is normal in size (4.19 cm), shape and echogenicity. It has smooth peripheral margination. There is a normal 1:3 cortex to medulla ratio with appropriate corticomedullary distinction. There is no evidence of pyelectasia or infarcts observed. Pinpoint nonobstructive mineral densities are noted in the right kidney.

AGE

1-27-2017 *Adrenal Glands*

WEIGHT Left adrenal gland is normal in size (0.49 cm), shape and overall architecture, echogenicity and echotexture. Visible surrounding vasculature appears normal.

10.3lbs

Right adrenal gland is normal in size (0.56), shape and overall architecture, echogenicity and echotexture. Visible surrounding vasculature appears normal.

INTERPRETED BY

Beth Johnson, DVM,
DACVIM (SAIM)

Spleen

Spleen is subjectively normal in size with a normal smooth capsular contour. Parenchyma is appropriately finely textured and homogenous with normal echogenicity relative to surrounding tissue (hyperechoic to liver). No focal nodules or masses are observed. Splenic vasculature appears normal.

HOSPITAL NAME

Eastern Animal
Hospital

Liver

Liver is subjectively normal in size with normal smooth curvilinear peripheral contour. Parenchyma is appropriately hypoechoic to the spleen in echogenicity and appropriately mildly coarse and homogenous in echotexture. No focal lesions are observed. Visible vasculature and biliary tree appear normal without distension or congestion.

REFERRING VET

Dr. Wensil-Strow

INVOICE

73471

Gallbladder is moderately distended with anechoic bile as well as suspended and gravity dependent echogenic debris. The wall is smooth without visible thickening. There is no evidence of cystic or CBD dilation. There is no evidence of effusion or inflammation.

Gastrointestinal

The visible stomach wall is normal in thickness and layering. The lumen of the stomach is empty with no evidence of obstruction, foreign material or infiltrative disease. Pyloric outflow tract appears patent.

The visible small intestine demonstrates areas of moderate to severely thick muscularis layer relative to mucosa (disruption of the normal 1:3 muscularis:mucosa ratio). Small intestinal submucosa is slightly irregular, thick and hyperechoic, without evident loss of layering appreciated. The lumen of the small intestine is empty with no evidence of obstruction or foreign material.

The visible colon is normal in wall thickness (< 0.2 cm) and layering. Contents are consistent with normal formed feces and gas.

Pancreas

The observed pancreas is prominent (enlarged) in size, hypoechoic to surrounding tissue and irregular in shape with a swollen undulating contour. Pancreatic duct dilation is noted. Enhanced hyperechoic ill-defined surrounding fat is noted.

Free Abdomen

There is no visible free peritoneal effusion noted in these images.

There is no apparent pathologic lymphadenopathy noted in these images.

ULTRASONOGRAPHIC FINDINGS

- Moderate inflammatory bowel disease (IBD) pattern – Thick muscularis has been reported with infiltrative bowel disease including both benign inflammatory disease as well as infiltrative neoplasia such as lymphoma. No loss of layering or distinct characteristics of malignancy are present. Therefore, differentials cannot be further ranked without tissue sampling.
- Concurrent chronic low grade smoldering pancreatitis is suspected with a mild or emerging acute on chronic flare up possible given the subtly enhanced hyperechoic tissue adjacent to the pancreas.
- Moderate gallbladder debris: Cholecystic debris is of unknown clinical significance. It can be seen with biliary stasis from fasting or illness, however, it can also be associated with hepatobiliary disease in cats and should be interpreted in combination with clinical signs such as nausea, inappetence, cranial abdominal discomfort and/or laboratory changes such as increased ALP and/or increased Tbili.

Secondary

- Pinpoint nonobstructive mineral densities/nephroliths in the right kidney.

INTERPRETATION OF THE FINDINGS & FURTHER RECOMMENDATIONS

Urinalysis and, if indicated based on urinalysis results, urine culture is recommended. If protein is present in an otherwise quiet sediment, protein quantification with a urine protein to creatinine ration is recommended.

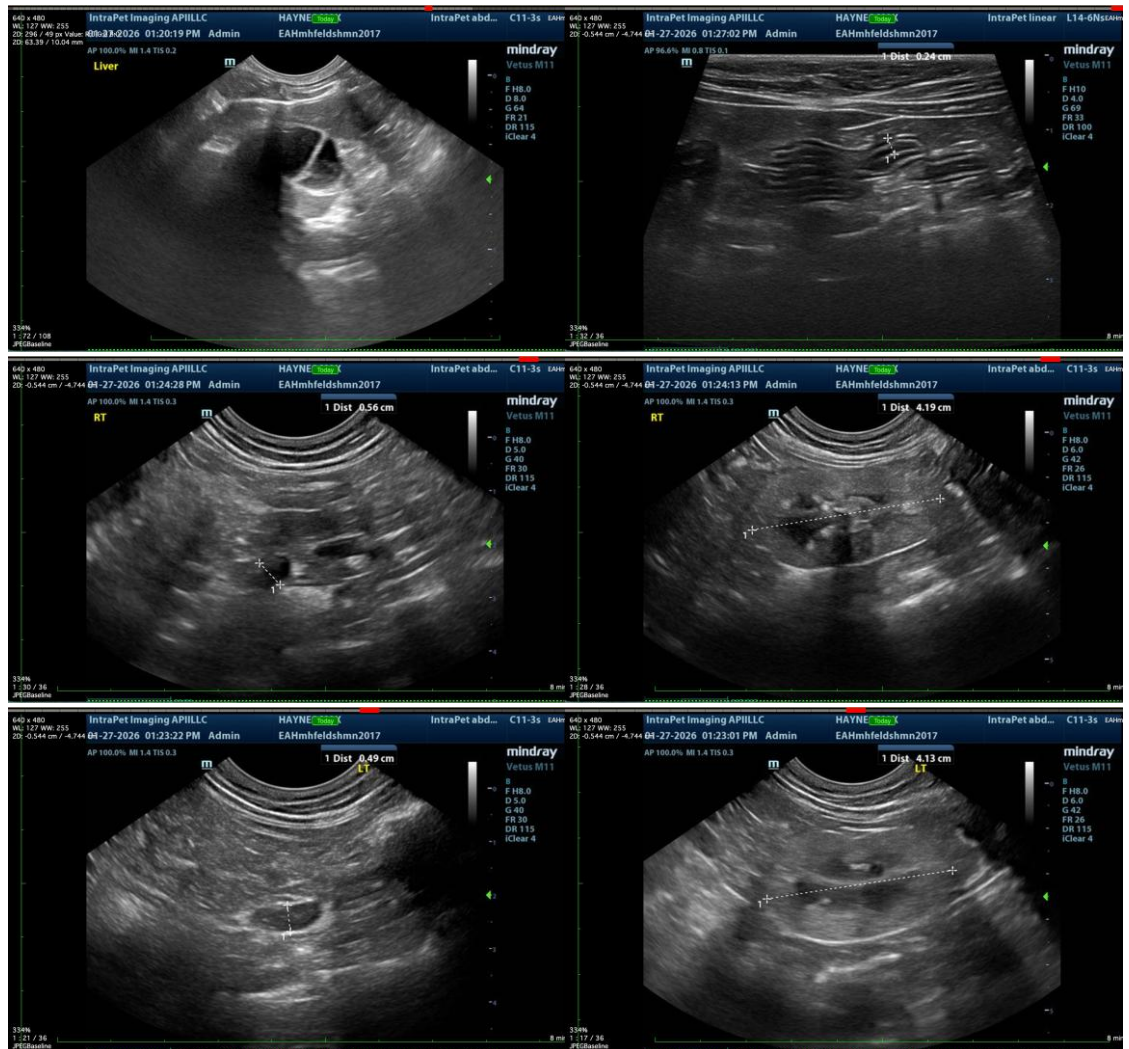
If not already evaluated, a T4 +/- free T4 is recommended.

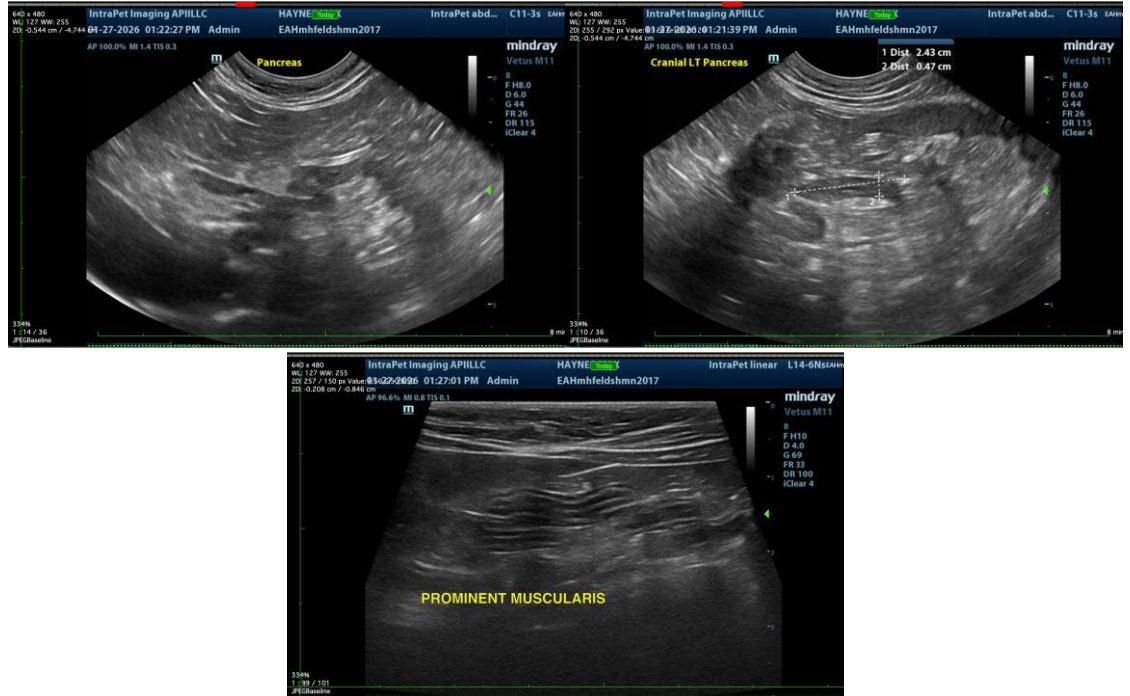
A gastrointestinal malabsorption panel (including cobalamin, folate, TLI and PLI) to Texas A&M GI Laboratory is recommended for further evaluation of GI and pancreatic function.

Ultimately, tissue sampling is recommended. FNA of the pancreas could be considered if patient's coagulation status is appropriate. Biopsies of the GI tract, being sure to include ileum, if possible, may

eventually be necessary for definitive diagnosis and therefore to further guide medical management.

In the meantime, medical management of pancreatitis with anti-emetics, gastroprotectants, appetite stimulants or nutritional support (including a feeding tube) as needed, pain management, broad spectrum antibiotics, and fluid therapy is recommended. Monitoring of the pancreas with power doppler is recommended to identify possible necrosis as well as other potential sequelae such as abscesses, etc.





The information and recommendations provided are based on the images presented by the referring veterinarian/sonographer. No evaluation can be communicated regarding pathology that was not visible in the image/video clips provided.

Thank you for this referral. If the clinical or image interpretation does not parallel your findings or if I can be of any further assistance please contact me.

Beth Johnson, DVM DACVIM

info@sonopath.com