



PATIENT

Cash Deveau

SPECIES

Canine

BREED

Lab

SEX

Neutered Male

AGE

10 years

WEIGHT

35.5 kg

INTERPRETED BY

Beth Johnson, DVM
DACVIM

IMAGING PERFORMED BY

Dr. Gira

HOSPITAL NAME

McKnight VH

REFERRING VET

Dr. Vanessa Gruffydd

INVOICE

11184

DATE

1/27/2026

PRESENTING CLINICAL SIGNS

- Weight loss, significant inappetence without vomiting or diarrhea.

Abnormal PE/Chem/CBC/UA Results: NSF.

ULTRASONOGRAPHIC EXAMINATION OF THE ABDOMEN

Urinary System

The urinary bladder is adequately distended with anechoic contents. No masses, inflammatory changes, echogenic sediment or cystoliths are observed. The urinary bladder, trigone and visible pelvic urethra are normal in thickness with a smooth mucosal surface.

Prostate is normal in size, echotexture, and echogenicity for a neutered male.

The right kidney is normal is size (7.03 cm), shape and echogenicity. It has smooth peripheral margination. There is a normal 1:3 cortex to medulla ratio with appropriate corticomedullary distinction. There is no evidence of pyelectasia, mineral or infarcts observed.

The left kidney is normal is size (6.88 cm), shape and echogenicity. It has smooth peripheral margination. There is a normal 1:3 cortex to medulla ratio with appropriate corticomedullary distinction. There is no evidence of pyelectasia, mineral or infarcts observed.

Adrenal Glands

The right adrenal gland is normal in size (0.94 cm at cranial pole and 0.84 cm at caudal pole), shape and overall architecture, echogenicity and echotexture. Visible surrounding vasculature appears normal.

The left adrenal gland is normal in size (0.68 cm at cranial pole and 0.75 cm at caudal pole), shape and overall architecture, echogenicity and echotexture. Visible surrounding vasculature appears normal.

Spleen

Spleen is subjectively large in size with a normal smooth capsular contour. Parenchyma is appropriately finely textured and homogenous with normal echogenicity relative to surrounding tissue (hyperechoic to liver). No focal nodules or masses are observed. Splenic vasculature appears normal. The spleen is folded upon itself, which is a positional non-pathologic variant.

Liver

The liver is subjectively decreased in size with normal smooth curvilinear peripheral contour. Parenchyma is appropriately hypoechoic to the spleen in echogenicity and appropriately mildly coarse and homogenous in echotexture. No focal lesions are observed. Visible vasculature and biliary tree appear normal without distension or congestion.

Gallbladder is moderately distended with anechoic bile as well as suspended and gravity dependent echogenic debris. The wall is smooth without visible thickening. There is no evidence of cystic or CBD dilation. There is no evidence of effusion or inflammation.

Gastrointestinal



PATIENT

Cash Deveau

The visible stomach wall is normal in thickness and layering. The lumen of the stomach is empty with no evidence of obstruction, foreign material or infiltrative disease. Pyloric outflow tract appears patent.

SPECIES

Canine

The visible small intestines are normal in wall thickness and layering. Small intestinal motility appears adequate (1-3 contractions per min). The lumen of the small intestine is empty with no evidence of obstruction, foreign material or infiltrative disease.

BREED

Lab

The very proximal colon is mildly thick measuring 0.3 cm thick with normal intact layering. It returns to normal thickness in the descending colon and the lumen is empty.

Pancreas

SEX

Neutered Male

The area of the pancreas contains irregular hyperechoic pancreatic remodeling.

Free Abdomen

AGE

10 years

There is no visible free peritoneal effusion noted in these images.

Mesenteric lymph nodes are prominent in size with swollen capsular contour. Normal elongated shape (length to width ratio) is maintained. There is no loss of parenchymal detail.

WEIGHT

35.5 kg

ULTRASONOGRAPHIC FINDINGS

INTERPRETED BY

Beth Johnson, DVM
DACVIM

- Very mildly thick proximal colon could be in part normal patient variant although parasitic, infectious, other benign inflammatory colitis can't be ruled out with infiltrative neoplasia being possible but considered much less likely.

- Hyperechoic pancreas – This finding is suggestive of pancreatic fibrosis, possibly secondary to chronic pancreatitis. A TLI is recommended to rule out exocrine pancreatic insufficiency (EPI), especially if clinical signs (weight loss, diarrhea, etc.) are present.

IMAGING PERFORMED BY

Dr. Gira

- Splenomegaly– can be associated with congestion caused by sedation (if sedated) but can also be associated with diffuse infiltrative disease. Both benign conditions such as extramedullary hematopoiesis, lymphoid hyperplasia as well as infiltrative neoplastic diseases such as round cell neoplasia should be considered.

HOSPITAL NAME

McKnight VH

- Subjectively possible mild microhepatica could be normal patient variant and should be confirmed radiographically if possible as ultrasound is not the most specific diagnostic to assess liver size.

REFERRING VET

Dr. Vanessa Gruffydd

- Moderate gallbladder debris - Cholecystic debris is of unknown clinical significance. It can be seen with biliary stasis from fasting or illness. Cholecystic debris is not necessarily related to hepatobiliary disease. Echogenic bile is most commonly an incidental finding in dogs and should be interpreted in combination with clinical signs such as nausea, inappetence, cranial abdominal discomfort and/or laboratory changes such as increased ALP and/or increased Tbili.

INVOICE

11184

DATE

1/27/2026

- Very, very mildly reactive mesenteric lymph nodes – infiltrative neoplastic disease cannot be ruled out but is considered less likely.



PATIENT

Cash Deveau

SPECIES

Canine

BREED

Lab

SEX

Neutered Male

AGE

10 years

WEIGHT

35.5 kg

INTERPRETED BY

Beth Johnson, DVM
DACVIM

IMAGING PERFORMED BY

Dr. Gira

HOSPITAL NAME

McKnight VH

REFERRING VET

Dr. Vanessa Gruffydd

INVOICE

11184

DATE

1/27/2026

INTERPRETATION OF THE FINDINGS & FURTHER RECOMMENDATIONS

A routine fecal/giardia exam is recommended if not recently evaluated.

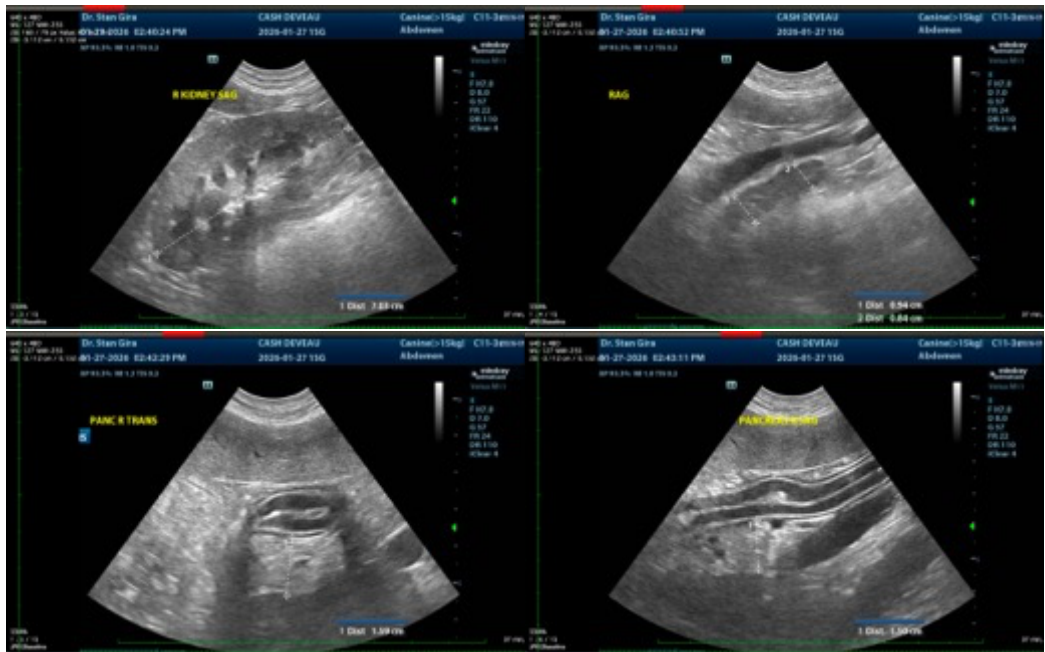
A gastrointestinal malabsorption panel (including cobalamin, folate, TLI and PLI) to Texas A&M GI Laboratory is recommended for further evaluation of GI and pancreatic function.

A baseline cortisol is recommended. If baseline cortisol is less than 2, a full ACTH stimulation test is recommended to rule out hypoadrenocorticism +/- a fecal enteropathogen PCR panel to Texas A&M GI Laboratory could be considered for further evaluation of possible infectious disease. Contact lab for recommendations on how long to discontinue antibiotics (if indicated) prior to obtaining a stool sample for submission.

Additionally, especially if microhepatica is confirmed and/or there are other concerns related to possible hepatopathy, bile acids could be considered if patient's total bilirubin is not increased.

Fine needle aspirates of the spleen could be considered if patient's coagulation status is appropriate.

If a diagnosis is still not made, further evaluation for possible pain (dental, orthopedic, other), upper respiratory disease or oropharyngeal disease, cardiac disease and/or neurologic disease vs other as possible causes for decreased appetite and/or unintentional weight loss is also recommended.





PATIENT

Cash Deveau

SPECIES

Canine

BREED

Lab

SEX

Neutered Male

AGE

10 years

WEIGHT

35.5 kg

INTERPRETED BY

Beth Johnson, DVM
DACVIM

IMAGING PERFORMED BY

Dr. Gira

HOSPITAL NAME

McKnight VH

REFERRING VET

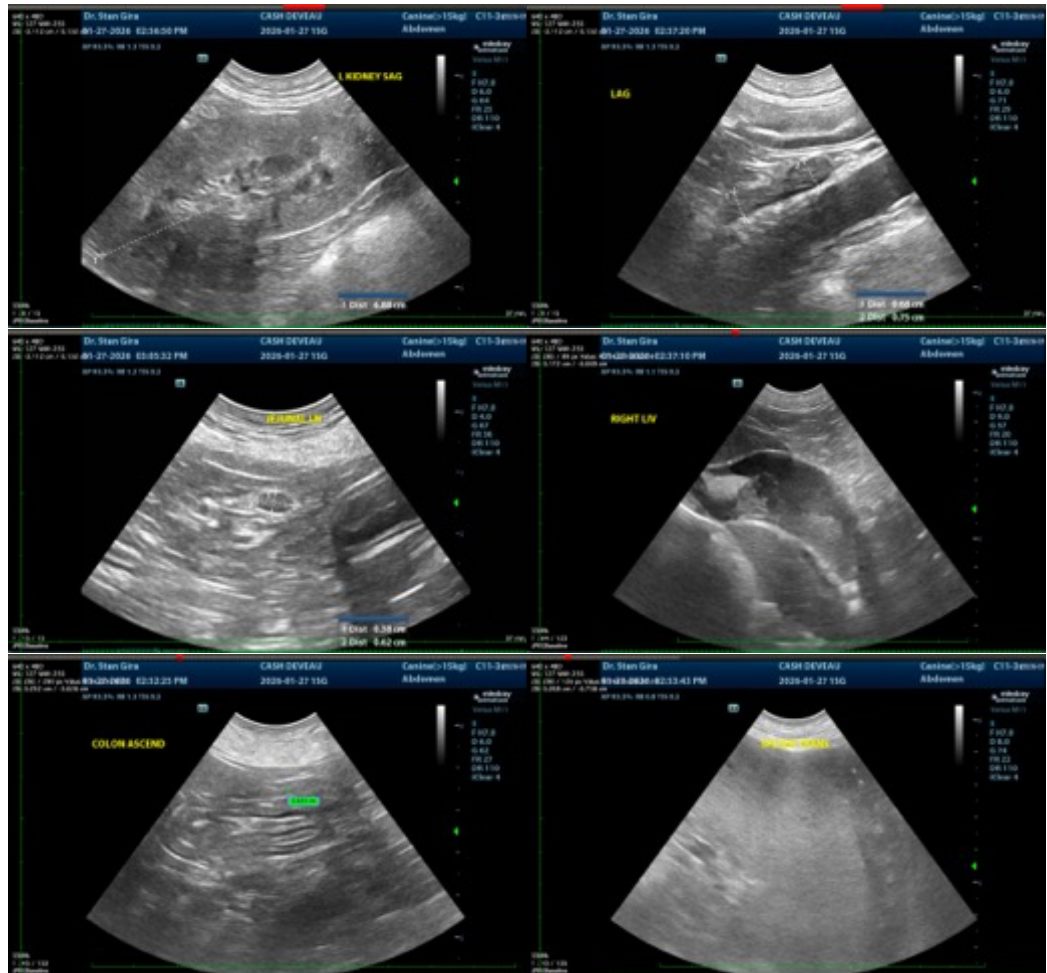
Dr. Vanessa Gruffydd

INVOICE

11184

DATE

1/27/2026



The information and recommendations provided are based on the images presented by the referring veterinarian/sonographer. No evaluation can be communicated regarding pathology that was not visible in the image/video clips provided.

Thank you for this referral. If the clinical or image interpretation does not parallel your findings or if I can be of any further assistance please contact me.

Beth Johnson, DVM, DACVIM
info@sonopath.com