



PATIENT	PRESENTING CLINICAL SIGNS
Doozy Smith	Elevated ALP- 6,000 +, now reduced appetite + increased ALT, GGT, and AST, small anal gland mass, she is currently on galliprant, selegiline, and trazadone at night.
SPECIES	ULTRASONOGRAPHIC EXAMINATION OF THE ABDOMEN
Canine	**Note: Many of the images were a little dark.
BREED	Urinary System
Shetland Sheepdog	The urinary bladder is moderately distended with anechoic contents. No masses, inflammatory changes, echogenic sediment or cystoliths are observed. The urinary bladder, trigone and visible pelvic urethra are normal in thickness with a smooth mucosal surface.
SEX	The right kidney is normal in size (4.2 cm), shape and echogenicity. It has smooth peripheral margination. There is a normal 1:3 cortex to medulla ratio with appropriate corticomedullary distinction. There is no evidence of pyelectasia, mineral or infarcts observed.
Spayed Female	
AGE	The left kidney is normal in size (4.1 cm), shape and echogenicity. It has smooth peripheral margination. There is a normal 1:3 cortex to medulla ratio with appropriate corticomedullary distinction. There is no evidence of pyelectasia, mineral or infarcts observed.
14 Years 6 Months	
WEIGHT	Adrenal Glands
19.2 Pounds	The right adrenal gland is normal in size (2.6 cm long x 1.1 cm at the cranial pole and 0.78 cm at the caudal pole), shape and contour. Corticomedullary structure is unremarkable. Visible surrounding vasculature appears normal.
INTERPRETED BY	The left adrenal gland is normal in size (0.74 cm at the cranial pole and 0.56 cm at the caudal pole), shape and contour. Corticomedullary structure is unremarkable. Visible surrounding vasculature appears normal.
Beth Johnson, DVM DACVIM	
IMAGING PERFORMED BY	Spleen
Dr. Katie Buss	The spleen is subjectively normal in size with a normal smooth capsular contour. Parenchyma is appropriately finely textured and homogenous with normal echogenicity relative to surrounding tissue (hyperechoic to liver). No focal nodules or masses are observed. Splenic vasculature appears normal.
HOSPITAL NAME	Liver
Kings Vet Hospital	Liver is subjectively enlarged with rounded margins. Parenchyma is heterogenous characterized by multiple poorly defined hypoechoic nodules within otherwise hyperechoic liver parenchyma. Just caudal to the gallbladder, the liver lobe appears round and mass-like, measuring 4.0 in diameter with a similar heterogeneous appearance to the rest of the liver, but discreet and mass-like in shape. Visible vasculature appears normal.
REFERRING VET	The gallbladder contains a moderate amount of non-dependent, mildly aggregated/inspissated sludge. Hypo to anechoic cystic areas are noted between the gallbladder sludge and luminal wall. The wall is otherwise smooth without visible thickening. There is no evidence of cystic or CBD dilation. There is no evidence of effusion.
Dr. Katie Buss	
INVOICE	Gastrointestinal
35136	The stomach wall is normal in thickness (canine < 0.5 cm and feline < 0.4 cm) and layering. The lumen of the stomach is empty with no evidence of obstruction, foreign material or infiltrative disease. Pyloric outflow tract appears patent.
DATE	
1/27/22	



PATIENT

Doozy Smith

The visible small intestines are normal in wall thickness and layering (canine duodenum < 0.5 cm and feline duodenum < 0.4 cm; other < 0.3 cm). Small intestinal motility appears adequate (1-3 contractions per min). The lumen of the small intestine is empty with no evidence of obstruction, foreign material or infiltrative disease.

SPECIES

Canine

The visible colon is normal in wall thickness (< 0.2 cm) and layering. Contents are consistent with normal formed feces and gas.

Pancreas

BREED

Shetland Sheepdog

The pancreatic parenchyma is appropriately isoechoic to surrounding tissue. Visible capsule is smooth and normal in contour. There is no visible pancreatic duct dilation. There is no evidence of active peripancreatic inflammation.

SEX

Spayed Female

Free Abdomen

There is no evidence of peritoneal effusion. There is no apparent lymphadenopathy in these images.

ULTRASONOGRAPHIC FINDINGS

AGE

14 Years 6 Months

- Early mucocele – Cholecystic debris is of unknown clinical significance. It can be seen with biliary stasis from fasting or illness. Cholecystic debris is not necessarily related to hepatobiliary disease. The non-dependent nature of this sludge combined with the cystic areas are suggestive, however, of possible emerging cystic mucosal hyperplasia or early gallbladder mucocele.

WEIGHT

19.2 Pounds

- Heterogenous liver a discreet mass-like lesion just caudal to the gallbladder. Differentials for hepatic changes include both benign steroid (vacuolar) hepatopathy or extramedullary hematopoiesis as well as infiltrative round cell or metastatic neoplasia. The mass-like lesion is more concerning for infiltrative neoplasia than the diffuse changes elsewhere.

INTERPRETED BY

Beth Johnson, DVM
DACVIM

INTERPRETATION OF THE FINDINGS & FURTHER RECOMMENDATIONS

Recommendations include a fine needle aspirate of the mass-like lesion in the liver, if patient's coagulation status is appropriate. However, given patient signalment combined with the ultrasound appearance of the gallbladder, an emerging mucocele is also likely, and pending the results of the liver fine needle aspirate, next recommended step may be exploratory laparotomy for gallbladder assessment +/- removal as well as liver biopsy, as well as anal gland mass removal. If not already performed, 3-view thoracic radiographs to further evaluate for possible metastatic disease are recommended. If surgery is not an option, empirical medical therapy could be tried with supportive care including antiemetics and appetite stimulants as well as empirical broad-spectrum antibiotics and Ursodiol.

IMAGING PERFORMED BY

Dr. Katie Buss

HOSPITAL NAME

Kings Vet Hospital

REFERRING VET

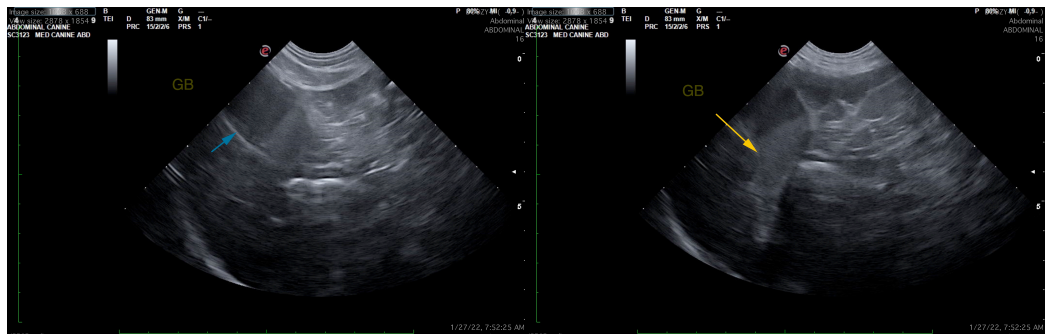
Dr. Katie Buss

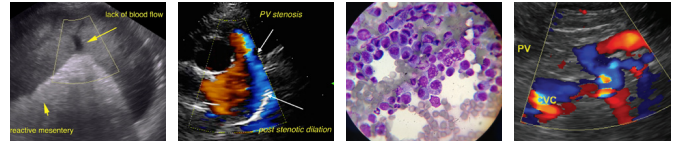
INVOICE

35136

DATE

1/27/22





PATIENT

Doozy Smith

SPECIES

Canine

BREED

Shetland Sheepdog

SEX

Spayed Female

AGE

14 Years 6 Months

WEIGHT

19.2 Pounds

INTERPRETED BY

Beth Johnson, DVM
DACVIM

IMAGING PERFORMED BY

Dr. Katie Buss

HOSPITAL NAME

Kings Vet Hospital

REFERRING VET

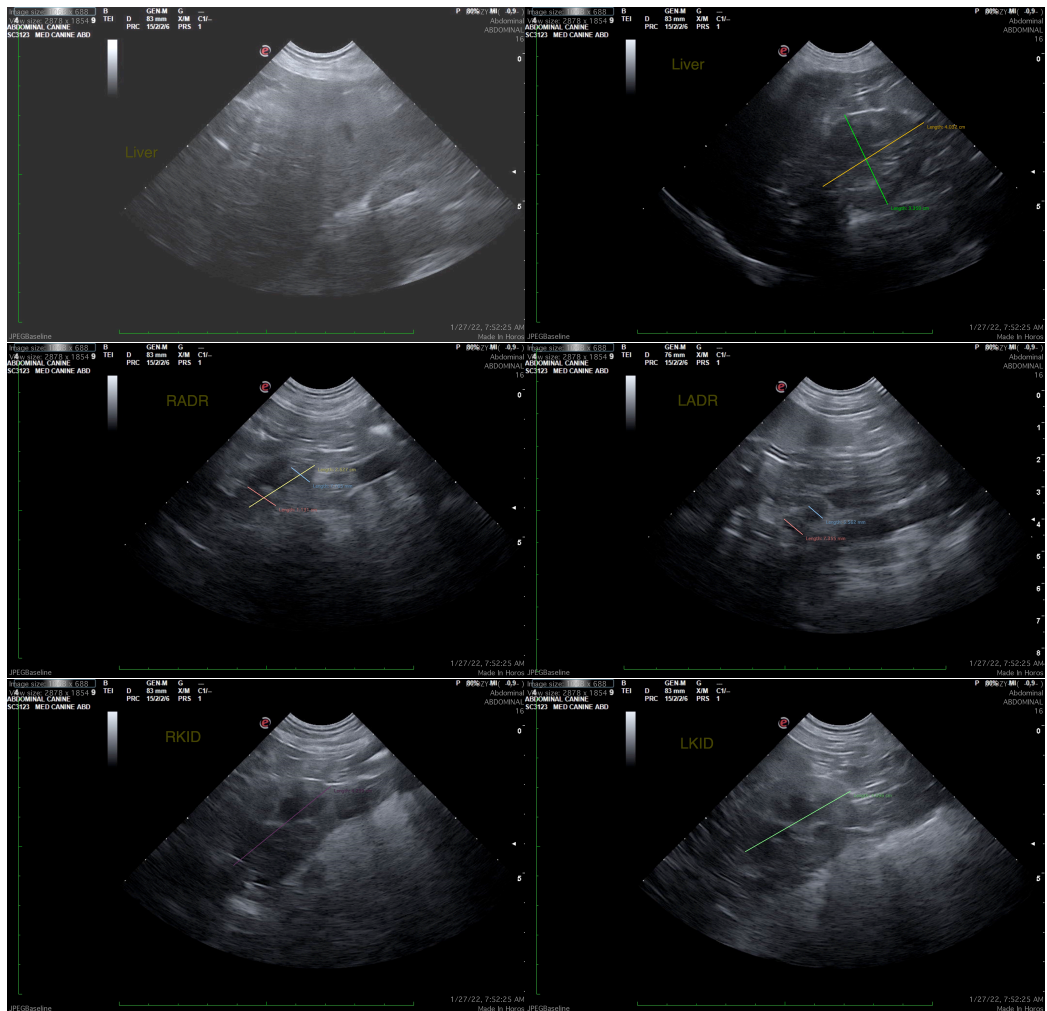
Dr. Katie Buss

INVOICE

35136

DATE

1/27/22



The information and recommendations provided are based on the images presented by the referring veterinarian/sonographer. No evaluation can be communicated regarding pathology that was not visible in the image/video clips provided.

Thank you for this referral. If the clinical or image interpretation does not parallel your findings or if I can be of any further assistance please contact me.

Beth Johnson, DVM, DACVIM
Beth.Johnson@sonopath.com