



PATIENT

Cairo Trombley

PRESENTING CLINICAL SIGNS

History of collapse and weakness. VPCs indicated abdominal ultrasound to check for disease

SPECIES

Canine

ULTRASONOGRAPHIC EXAMINATION OF THE ABDOMEN

Urinary System

The urinary bladder is moderately distended with anechoic contents. No masses, inflammatory changes, echogenic sediment or cystoliths are observed. The urinary bladder, trigone and visible pelvic urethra are normal in thickness with a smooth mucosal surface.

BREED

Terrier X

There is no pathology noted in the region of the prostate. The prostate measures 2.9 cm width.

SEX

Male

The right kidney is normal in size (5.6 cm), shape and echogenicity. It has smooth peripheral margination. There is a normal 1:3 cortex to medulla ratio with appropriate corticomedullary distinction. There is no evidence of pyelectasia, mineral or infarcts observed.

AGE

11 Years

The left kidney is normal in size (6.3 cm), shape and echogenicity. It has smooth peripheral margination. There is a normal 1:3 cortex to medulla ratio with appropriate corticomedullary distinction. There is no evidence of pyelectasia, mineral or infarcts observed.

Adrenal Glands

WEIGHT

38.7 kg

The right adrenal gland is normal in size (0.62 cm at the cranial pole and 0.45 cm at the caudal pole), shape and contour. Corticomedullary structure is unremarkable. Visible surrounding vasculature appears normal.

The left adrenal gland is normal in size (0.63 cm at the cranial pole and 0.55 cm at the caudal pole), shape and contour. Corticomedullary structure is unremarkable. Visible surrounding vasculature appears normal.

INTERPRETED BY

Beth Johnson, DVM
DACVIM

Spleen

Spleen is subjectively enlarged in size with rounded margins but intact capsule. Parenchyma is homogeneously coarse/mottled in echotexture and normal to hypoechoic in echogenicity. No focal nodules or masses are observed. Splenic vasculature appears normal.

IMAGING PERFORMED BY

Alejandro Vargas
Lumbreras

Liver

The liver is subjectively normal in size with normal smooth curvilinear peripheral contour. Parenchyma is appropriately hypoechoic to the spleen in echogenicity and appropriately mildly coarse and homogenous in echotexture. No focal lesions are observed. Visible vasculature and biliary tree appear normal without distension or congestion.

HOSPITAL NAME

Central Island Vet
Emergency Hospital

REFERRING VET

Dr. Nikolas Bell

The gallbladder is non-distended in size. The wall is smooth without visible thickening. Luminal contents are primarily anechoic. There is no evidence of cystic or common bile duct dilation.

Gastrointestinal

INVOICE

35135

The stomach wall is normal in thickness (canine < 0.5 cm and feline < 0.4 cm) and layering. The lumen of the stomach is empty with no evidence of obstruction, foreign material or infiltrative disease. Pyloric outflow tract appears patent.

DATE

1/27/22

The visible small intestines are normal in wall thickness and layering (canine duodenum < 0.5 cm and feline duodenum < 0.4 cm; other < 0.3 cm). Small intestinal motility appears adequate (1-3 contractions



PATIENT

Cairo Trombley

per min). The lumen of the small intestine is empty with no evidence of obstruction, foreign material or infiltrative disease.

SPECIES

Canine

The visible colon is normal in wall thickness (< 0.2 cm) and layering. Contents are consistent with normal formed feces and gas.

Pancreas

The pancreatic parenchyma is appropriately isoechoic to surrounding tissue. Visible capsule is smooth and normal in contour. There is no visible pancreatic duct dilation. There is no evidence of active peripancreatic inflammation.

BREED

Terrier X

Free Abdomen

There is no evidence of peritoneal effusion. There is no apparent lymphadenopathy.

SEX

Male

ULTRASONOGRAPHIC FINDINGS

AGE

11 Years

- Coarse splenomegaly – can be associated with congestion caused by sedation (if sedated) but can also be associated with diffuse infiltrative disease. Both benign conditions such as extramedullary hematopoiesis, lymphoid hyperplasia, as well as infiltrative neoplastic diseases such as round cell neoplasia should be considered.

INTERPRETATION OF THE FINDINGS & FURTHER RECOMMENDATIONS

WEIGHT

38.7 kg

Recommendations for this patient include a fine needle aspirate of the spleen if patient's coagulation status is appropriate. A blood pressure is also recommended as well as urinalysis with a urine protein/creatinine ratio added on if there is protein in the urine and an otherwise quiet sediment, due to the history of collapse and VPCs.

INTERPRETED BY

Beth Johnson, DVM
DACVIM

IMAGING PERFORMED BY

Alejandro Vargas
Lumbreras

HOSPITAL NAME

Central Island Vet
Emergency Hospital

REFERRING VET

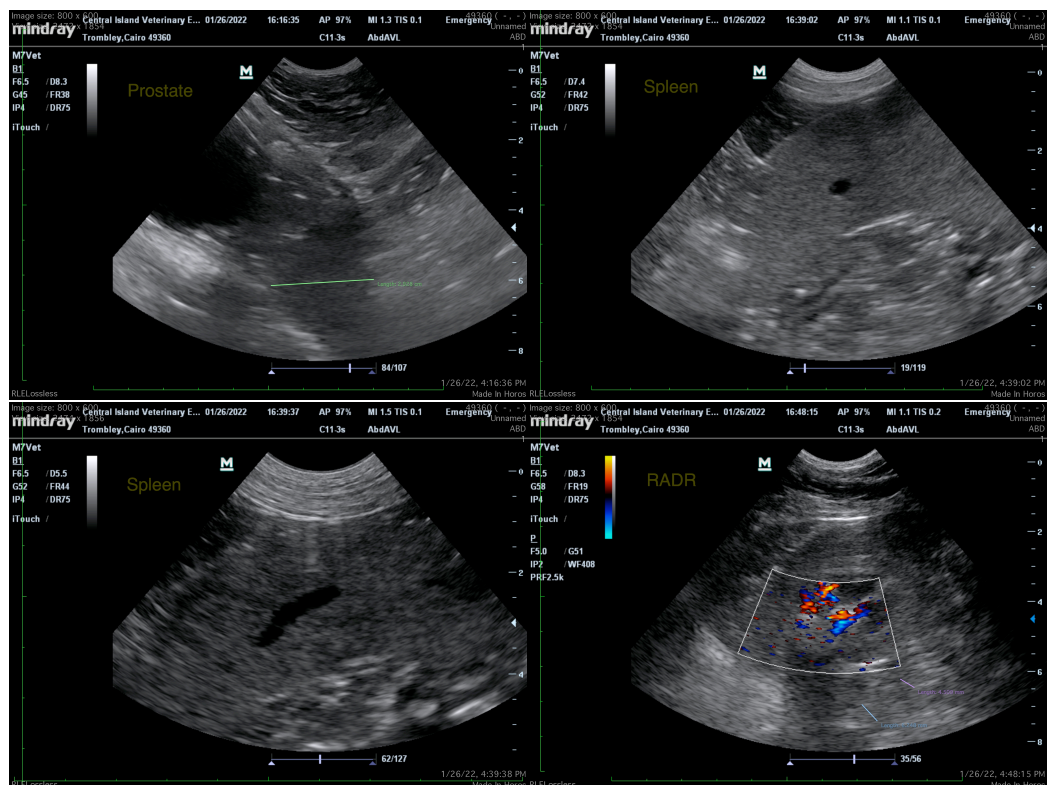
Dr. Nikolas Bell

INVOICE

35135

DATE

1/27/22





PATIENT

Cairo Trombley

SPECIES

Canine

BREED

Terrier X

SEX

Male

AGE

11 Years

WEIGHT

38.7 kg

INTERPRETED BY

Beth Johnson, DVM
DACVIM

IMAGING PERFORMED BY

Alejandro Vargas
Lumbreras

HOSPITAL NAME

Central Island Vet
Emergency Hospital

REFERRING VET

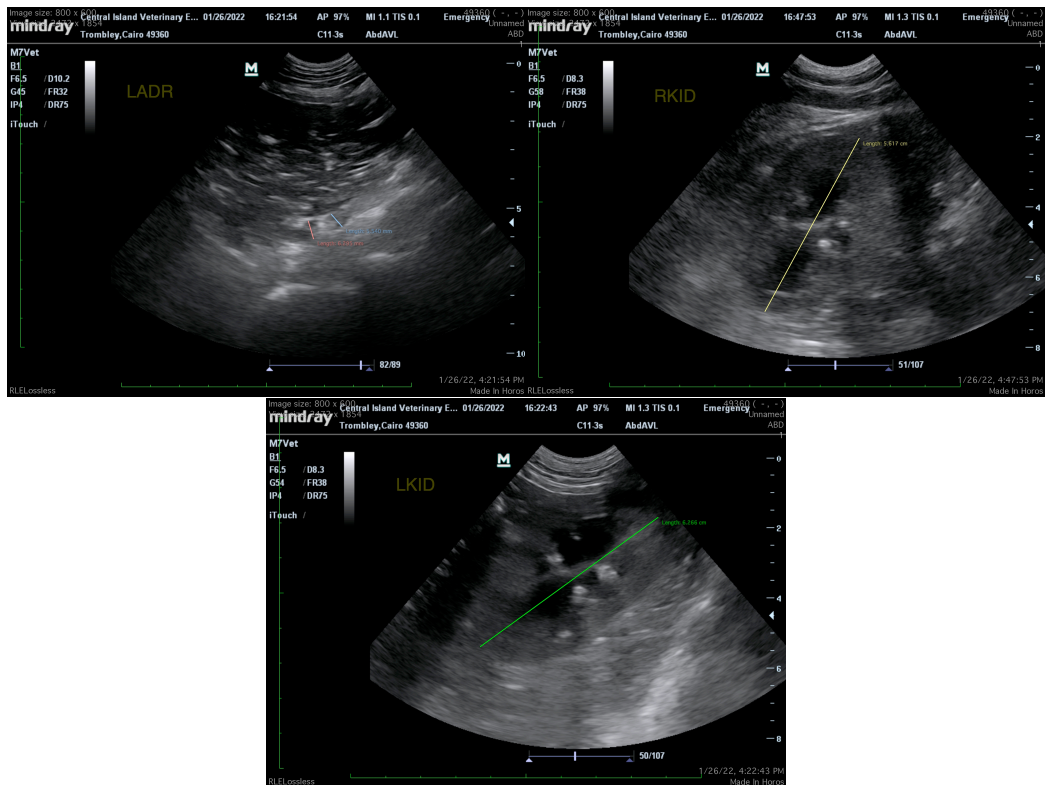
Dr. Nikolas Bell

INVOICE

35135

DATE

1/27/22



The information and recommendations provided are based on the images presented by the referring veterinarian/sonographer. No evaluation can be communicated regarding pathology that was not visible in the image/video clips provided.

Thank you for this referral. If the clinical or image interpretation does not parallel your findings or if I can be of any further assistance please contact me.

Beth Johnson, DVM, DACVIM
Beth.Johnson@sonopath.com