



PATIENT	PRESENTING CLINICAL SIGNS
Sadie Botto	Diarrhea, vomiting, stopped eating and drinking yesterday
SPECIES	ULTRASONOGRAPHIC EXAMINATION OF THE ABDOMEN
Canine	Urinary System
BREED	The urinary bladder is moderately distended with anechoic contents. No masses, inflammatory changes, echogenic sediment or cystoliths are observed. The urinary bladder, trigone and visible pelvic urethra are normal in thickness with a smooth mucosal surface.
Poodle	
SEX	The right kidney is normal in size (3.51 cm), shape and echogenicity. It has smooth peripheral margination. There is a normal 1:3 cortex to medulla ratio with appropriate corticomedullary distinction. There is no evidence of pyelectasia, mineral or infarcts observed.
Spayed Female	
AGE	The left kidney is normal in size (3.14 cm), shape and echogenicity. It has smooth peripheral margination. There is a normal 1:3 cortex to medulla ratio with appropriate corticomedullary distinction. There is no evidence of pyelectasia, mineral or infarcts observed.
2	
WEIGHT	Adrenal Glands
4.5	The right adrenal gland is normal in size (1.85 cm long x 0.87 cm at the cranial pole and 0.50 cm at the caudal pole), shape and contour. Corticomedullary structure is unremarkable. Visible surrounding vasculature appears normal.
INTERPRETED BY	The left adrenal gland is normal in size (1.41 cm long x 0.54 cm at the cranial pole and 0.33 cm at the caudal pole), shape and contour. Corticomedullary structure is unremarkable. Visible surrounding vasculature appears normal.
Beth Johnson, DVM DACVIM	
IMAGING PERFORMED BY	Spleen
Jenn	The spleen is subjectively normal in size with a normal smooth capsular contour. Parenchyma is appropriately finely textured and homogenous with normal echogenicity relative to surrounding tissue (hyperechoic to liver). No focal nodules or masses are observed. Splenic vasculature appears normal.
HOSPITAL NAME	Liver
Rockaway AH	The liver is subjectively normal in size with normal smooth curvilinear peripheral contour. Parenchyma is appropriately hypoechoic to the spleen in echogenicity and appropriately mildly coarse and homogenous in echotexture. No focal lesions are observed. Visible vasculature and biliary tree appear normal without distension or congestion.
REFERRING VET	The gallbladder is non-distended in size. The wall is smooth without visible thickening. Luminal contents are primarily anechoic. There is no evidence of cystic or common bile duct dilation.
Dr. Maniar	
INVOICE	Gastrointestinal
44523	The stomach wall is normal in thickness (canine < 0.5 cm and feline < 0.4 cm) and layering. The lumen of the stomach is empty with no evidence of obstruction, foreign material or infiltrative disease. Pyloric outflow tract appears patent.
DATE	The visible small intestines are normal in wall thickness and layering (canine duodenum < 0.5 cm and feline duodenum < 0.4 cm; other < 0.3 cm). Small intestinal motility appears adequate (1-3 contractions per min). The lumen of the small intestine is empty with no evidence of obstruction, foreign material or infiltrative disease.
1/26/23	



PATIENT The visible colon is normal in wall thickness (< 0.2 cm) and layering. Soft to liquid stool noted.

Sadie Botto **Pancreas**

SPECIES The pancreatic parenchyma is appropriately isoechoic to surrounding tissue. Visible capsule is smooth and normal in contour. There is no visible pancreatic duct dilation. There is no evidence of active peripancreatic inflammation.

Canine

BREED **Free Abdomen**

Poodle There is no evidence of free peritoneal effusion noted in these images.

SEX There is no apparent lymphadenopathy noted in these images.

Spayed Female

ULTRASONOGRAPHIC FINDINGS

- Soft stool in the colon – consistent with the reported clinical history of diarrhea.
- Otherwise, relatively unremarkable/normal abdomen

INTERPRETATION OF THE FINDINGS & FURTHER RECOMMENDATIONS

AGE 2
WEIGHT 4.5
If these clinical signs are acute, then supportive/symptomatic medical management of gastroenteritis, dietary indiscretion, parasitic disease, etc. is recommended to include antiemetics, gastroprotectants, probiotic such as Visbiome or Provable, empirical deworming with a 5-day course of Panacur, and a bland, easy to digest diet until clinical signs resolve.

INTERPRETED BY Beth Johnson, DVM DACVIM
If clinical signs don't resolve and/or there is any chronicity to the clinical signs, further diagnostic recommendations include a general metabolic health screen to include CBC/Chem panel, electrolytes, and urinalysis, as well as a fecal exam if not recently evaluated, and a gastrointestinal malabsorption panel (including cobalamin, folate, TLI and PLI) to Texas A&M GI Laboratory, and if chronic, potentially a diet transition to a hydrolyzed protein diet based on trial and error response.

IMAGING PERFORMED BY

Jenn

HOSPITAL NAME

Rockaway AH

REFERRING VET

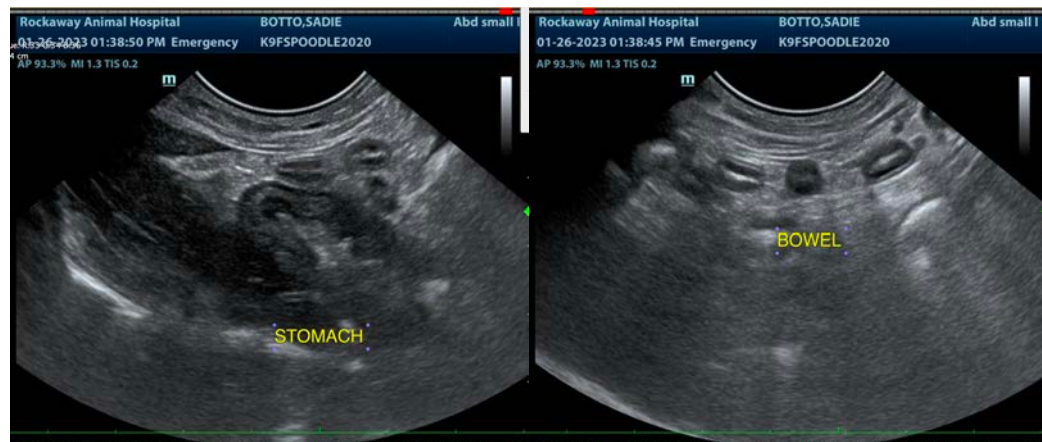
Dr. Maniar

INVOICE

44523

DATE

1/26/23





PATIENT

Sadie Botto

SPECIES

Canine

BREED

Poodle

SEX

Spayed Female

AGE

2

WEIGHT

4.5

INTERPRETED BY

Beth Johnson, DVM
DACVIM

IMAGING PERFORMED BY

Jenn

HOSPITAL NAME

Rockaway AH

REFERRING VET

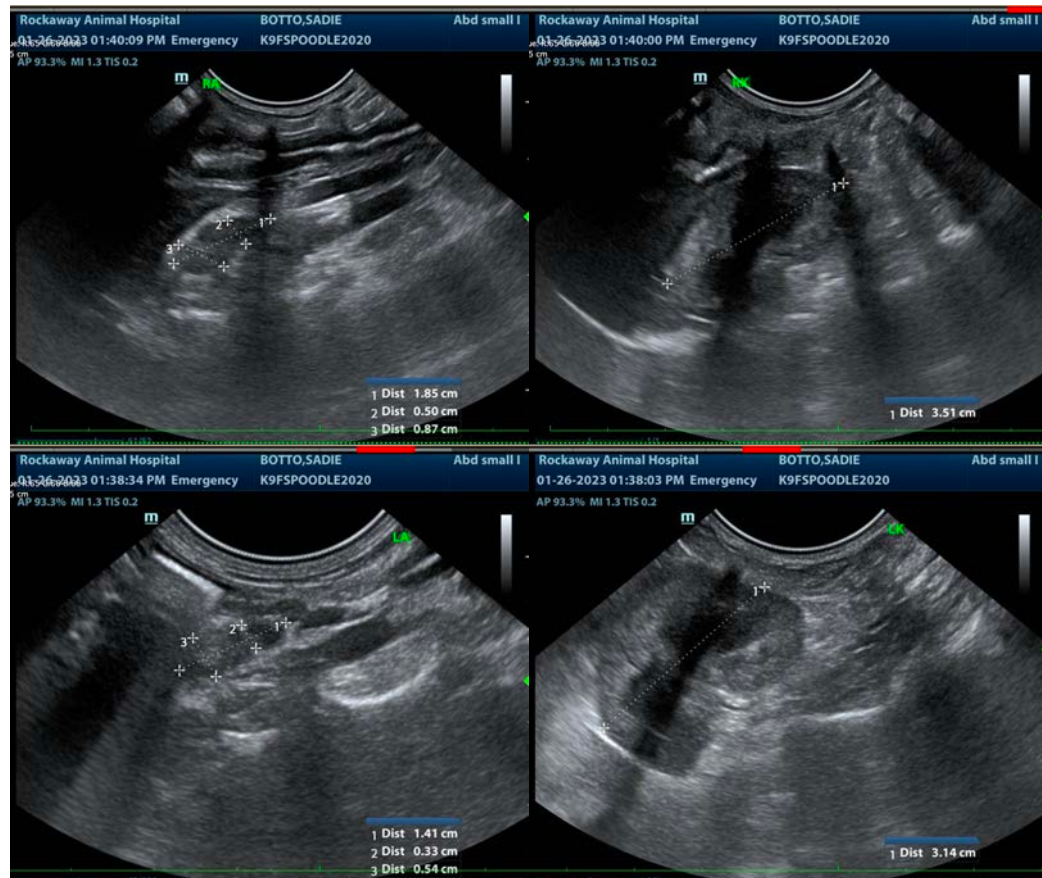
Dr. Maniar

INVOICE

44523

DATE

1/26/23



The information and recommendations provided are based on the images presented by the referring veterinarian/sonographer. No evaluation can be communicated regarding pathology that was not visible in the image/video clips provided.

Thank you for this referral. If the clinical or image interpretation does not parallel your findings or if I can be of any further assistance please contact me.

Beth Johnson, DVM, DACVIM
Beth.Johnson@sonopath.com