

**DATE PRESENTING CLINICAL SIGNS**

1/26/22 History: patient present to PetEr on 1/23 for multiple louts of v and lethargy. rads were taken (SNL). Cerenia and gabapentin were sent home. p has not eaten since 1/23/2022 and is nauseous when food is presented. Painful abd today on evaluation, suspect foreign body with thickened, bunched SI on rads today.

PATIENT

Ja Kraft Radiographs: Attached separately - empty stomach, foreign material in colon, thickened Intestines and bunched, abnormal gas pattern.

SPECIES

Feline

Date of Previous IntraPet Ultrasound: No previous IntraPet scans.

Sedation: Telazol IV.

Stat Report: REQUESTED.

BREED

DSH

SEX

Neutered Male

AGE

8/3/20

WEIGHT

11.6 Pounds

INTERPRETED BY

Beth Johnson, DVM
DACVIM

IMAGING PERFORMED BY

Stephanie Pearce
RDCCS, RVT

HOSPITAL NAME

Northwind AH

REFERRING VET

Dr. Jones

INVOICE

35059

ULTRASONOGRAPHIC EXAMINATION OF THE ABDOMEN**Urinary System**

The urinary bladder is moderately distended with anechoic contents. No masses, inflammatory changes, echogenic sediment or cystoliths are observed. The urinary bladder, trigone and visible pelvic urethra are normal in thickness with a smooth mucosal surface.

The right kidney is normal in size (4.17 cm), shape and echogenicity. It has smooth peripheral margination. There is a normal 1:3 cortex to medulla ratio with appropriate corticomedullary distinction. There is no evidence of pyelectasia, mineral or infarcts observed.

The left kidney is normal in size (3.89 cm), shape and echogenicity. It has smooth peripheral margination. There is a normal 1:3 cortex to medulla ratio with appropriate corticomedullary distinction. There is no evidence of pyelectasia, mineral or infarcts observed.

Adrenal Glands

The right adrenal gland is normal in size (0.54 cm thick), shape and contour. Corticomedullary structure is unremarkable. Visible surrounding vasculature appears normal.

The left adrenal gland is normal in size (0.49 cm thick), shape and contour. Corticomedullary structure is unremarkable. Visible surrounding vasculature appears normal.

Spleen

The spleen is subjectively normal in size with a normal smooth capsular contour. Parenchyma is appropriately finely textured and homogenous with normal echogenicity relative to surrounding tissue (hyperechoic to liver). No focal nodules or masses are observed. Splenic vasculature appears normal.

Liver

The liver is subjectively normal in size with normal smooth curvilinear peripheral contour. Parenchyma is appropriately hypoechoic to the spleen in echogenicity and appropriately mildly coarse and homogenous in echotexture. No focal lesions are observed. Visible vasculature and biliary tree appear normal without distension or congestion.

The gallbladder is non-distended in size. The wall is smooth without visible thickening. Luminal contents are primarily anechoic. There is no evidence of cystic or common bile duct dilation.

Gastrointestinal

The stomach wall is normal in thickness (canine < 0.5 cm and feline < 0.4 cm) and layering. The lumen of the stomach is mildly distended with very echogenic reverberation artifact from intraluminal gas. Combined with the gas, there is echogenic luminal contents, consistent with either ingesta or potentially foreign material given the remainder of the images. Pyloric outflow tract appears patent.

The small bowel has normal thickness and intact layering. There is a focal area of small bowel that is mildly fluid distended and markedly plicated, with very hyperechoic central luminal contents that appear to be attached to a hyperechoic structure with strong acoustic shadowing.

The visible colon is normal in wall thickness (< 0.2 cm) and layering. Contents are consistent with gas, normal formed stool +/- foreign material.

Pancreas

The pancreatic parenchyma is appropriately isoechoic to surrounding tissue. Visible capsule is smooth and normal in contour. There is no visible pancreatic duct dilation. There is no evidence of active peripancreatic inflammation.

Free Abdomen

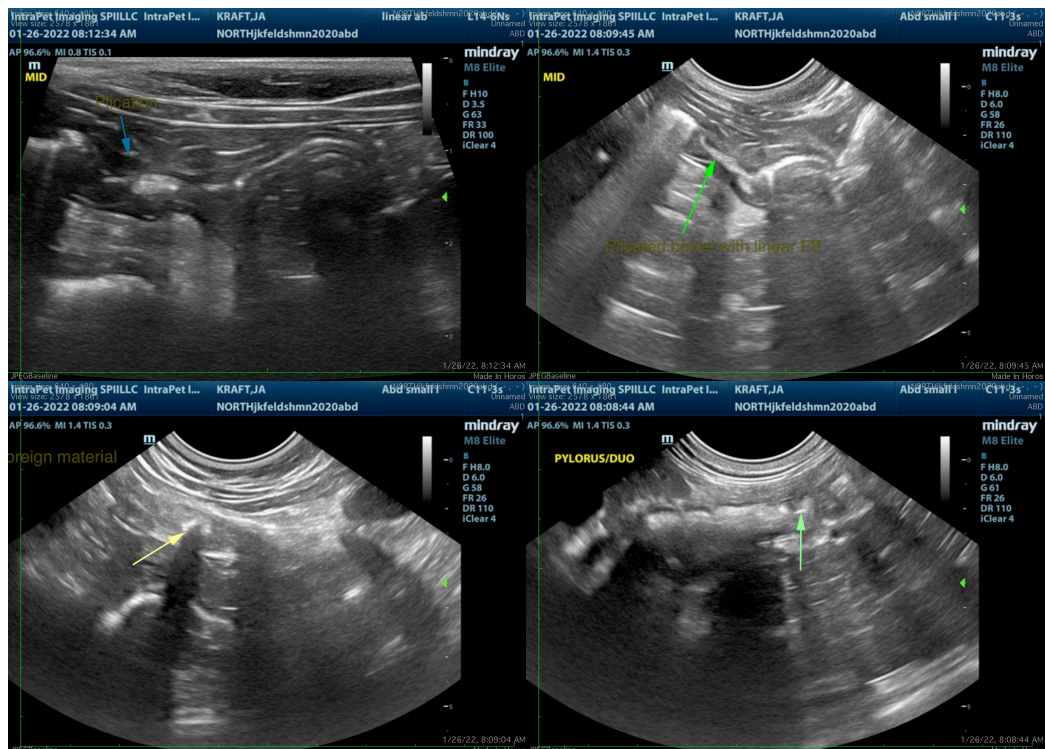
There is no evidence of peritoneal effusion. There is no apparent lymphadenopathy.

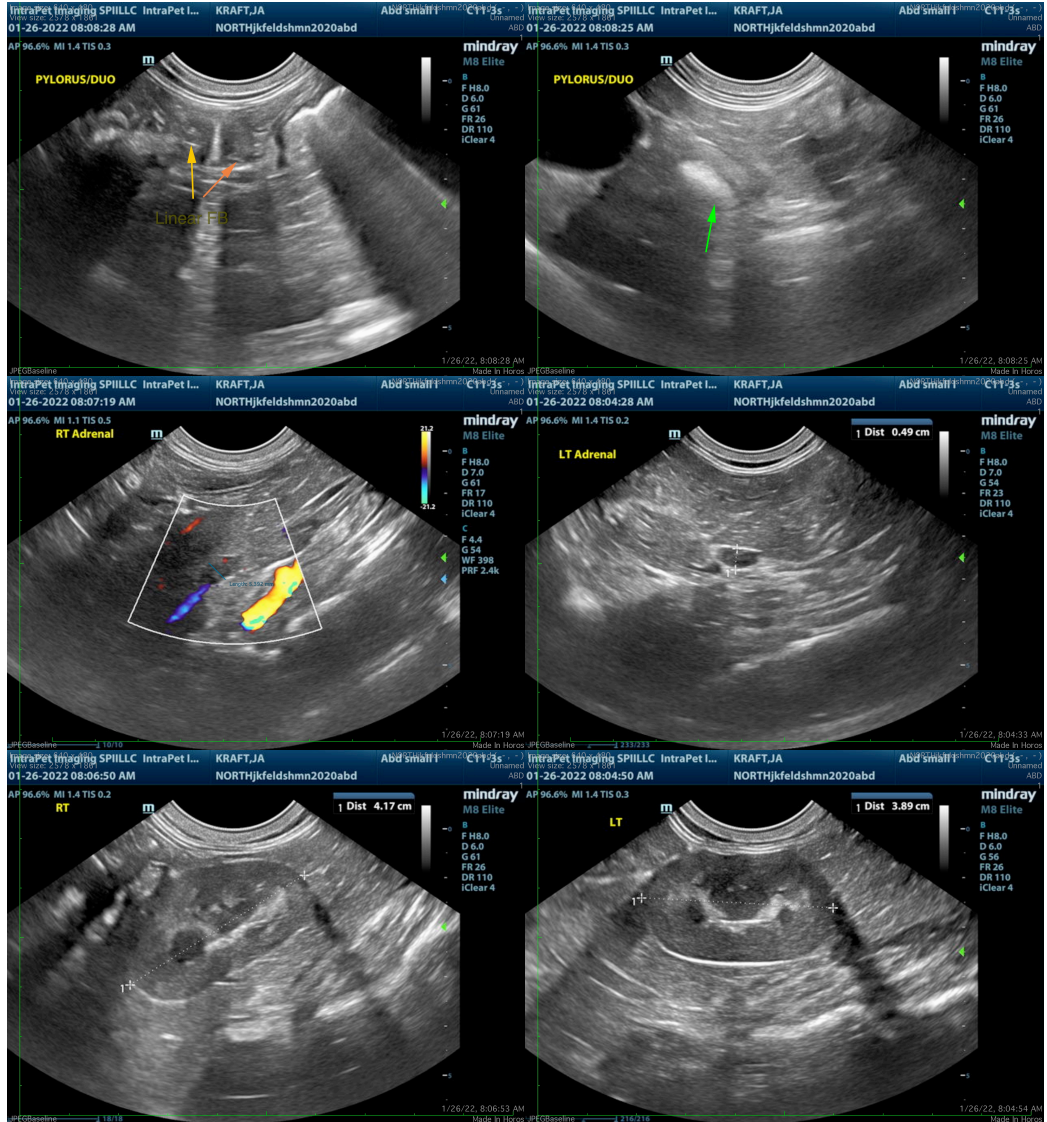
ULTRASONOGRAPHIC FINDINGS

- The small bowel changes are most consistent with a linear foreign body, resulting in plication. Foreign material may also be present in the stomach and the colon.

INTERPRETATION OF THE FINDINGS & FURTHER RECOMMENDATIONS

Recommendations include exploratory laparotomy for foreign body removal +/- resection and anastomosis if needed based on bowel health.





The information and recommendations provided are based on the images presented by the referring veterinarian/sonographer. No evaluation can be communicated regarding pathology that was not visible in the image/video clips provided.

Thank you for this referral. If the clinical or image interpretation does not parallel your findings or if I can be of any further assistance please contact me.

Beth Johnson, DVM, DACVIM
Beth.Johnson@sonopath.com