



PATIENT

Hydrox Paolucci

PRESENTING CLINICAL SIGNS

ALT 236, not clinical. No current meds.

SPECIES

Canine

ULTRASONOGRAPHIC EXAMINATION OF THE ABDOMEN

Urinary System

The urinary bladder is moderately distended with anechoic contents. No masses, inflammatory changes, echogenic sediment or cystoliths are observed. The urinary bladder, trigone and visible pelvic urethra are normal in thickness with a smooth mucosal surface.

BREED

Mixed

The right kidney is normal in size (4.86 cm), shape and echogenicity. It has smooth peripheral margination. There is a normal 1:3 cortex to medulla ratio with appropriate corticomedullary distinction. There is no evidence of pyelectasia, mineral or infarcts observed.

SEX

Spayed Female

The left kidney is normal in size (5.93 cm), shape and echogenicity. It has smooth peripheral margination. There is a normal 1:3 cortex to medulla ratio with appropriate corticomedullary distinction. There is no evidence of pyelectasia, mineral or infarcts observed.

AGE

10 Years

Adrenal Glands

The right adrenal gland is normal in size (1.66 cm long x 0.78 cm at the cranial pole and 0.85 cm at the caudal pole), shape and contour. Corticomedullary structure is unremarkable. Visible surrounding vasculature appears normal.

WEIGHT

49.1 Pounds

The left adrenal gland is normal in size (1.42 cm long x 0.26 cm at the cranial pole and 0.22 cm at the caudal pole), shape and contour. Corticomedullary structure is unremarkable. Visible surrounding vasculature appears normal.

INTERPRETED BY

Beth Johnson, DVM
DACVIM

Spleen

The spleen is subjectively normal in size with a normal smooth capsular contour. Parenchyma is appropriately finely textured and homogenous with normal echogenicity relative to surrounding tissue (hyperechoic to liver). A hypo- to anechoic nodule measuring 0.8 cm in diameter was noted in the mid body, non-capsule disrupting. Splenic vasculature appears normal.

IMAGING PERFORMED BY

Kelly Vazquez

Liver

The liver is subjectively normal in size with normal smooth curvilinear peripheral contour. Parenchyma is appropriately hypoechoic to the spleen in echogenicity and appropriately mildly coarse and homogenous in echotexture. No focal lesions are observed. Visible vasculature and biliary tree appear normal without distension or congestion.

HOSPITAL NAME

Animal General
on the Hudson

REFERRING VET

Dr. Vivian Ng

The gallbladder is moderately distended with anechoic bile and gravity dependent echogenic sediment. The wall is smooth without visible thickening. There is no evidence of cystic or CBD dilation. There is no evidence of effusion or inflammation.

Gastrointestinal

INVOICE

35128

The stomach wall is normal in thickness (canine < 0.5 cm and feline < 0.4 cm) and layering. The lumen of the stomach is empty with no evidence of obstruction, foreign material or infiltrative disease. Pyloric outflow tract appears patent.

DATE

1/26/22



PATIENT

Hydrox Paolucci

The visible small intestines are normal in wall thickness and layering (canine duodenum < 0.5 cm and feline duodenum < 0.4 cm; other < 0.3 cm). Small intestinal motility appears adequate (1-3 contractions per min). The lumen of the small intestine is empty with no evidence of obstruction, foreign material or infiltrative disease.

SPECIES

Canine

The visible colon is normal in wall thickness (< 0.2 cm) and layering. Contents are consistent with normal formed feces and gas.

Pancreas

BREED

Mixed

The pancreatic parenchyma is appropriately isoechoic to surrounding tissue. Visible capsule is smooth and normal in contour. There is no visible pancreatic duct dilation. There is no evidence of active peripancreatic inflammation.

SEX

Spayed Female

Free Abdomen

There is no evidence of peritoneal effusion. There is no apparent lymphadenopathy.

ULTRASONOGRAPHIC FINDINGS

AGE

10 Years

- Splenic nodule – most consistent with a benign cyst, hematoma, or extramedullary hematopoiesis. Infiltrative neoplasia can mimic benign lesions and cannot be ruled out, but is considered less likely.

WEIGHT

49.1 Pounds

- Gallbladder debris - Cholecystic debris is of unknown clinical significance. It can be seen with biliary stasis from fasting or illness. Cholecystic debris is not necessarily related to hepatobiliary disease. Echogenic bile is most commonly an incidental finding in dogs and should be interpreted in combination with clinical signs such as nausea, inappetence, cranial abdominal discomfort and/or laboratory changes such as increased ALP and/or increased Tbili.

INTERPRETED BY

Beth Johnson, DVM
DACVIM

INTERPRETATION OF THE FINDINGS & FURTHER RECOMMENDATIONS

Alanine Aminotransferase (ALT) - ALT is more liver specific than other enzymes. It is a good indicator of active liver damage (cell membrane disruption, cellular necrosis) if the value is increased by at least 3-4 times normal. Differentials include infectious disease, including Leptospirosis, inflammatory disease (ie. active hepatitis, copper, other), toxic insult as well as infiltrative neoplasia.

IMAGING PERFORMED BY

Kelly Vazquez

ALT levels vary in cases of vascular anomalies such as microvascular dysplasia and portosystemic shunts (PSS), but are often less significantly increased.

HOSPITAL NAME

Animal General
on the Hudson

Non primary hepatic causes of increased ALT can include a variety of other metabolic conditions including, but not limited to, pancreatitis, gastroenteritis, parasitic disease, dental disease, vacuolar or endocrine hepatopathy from diabetes mellitus or hyperadrenocorticism (steroid-induced), hypoadrenocorticism, certain drugs (e.g. phenobarbital, corticosteroids, azathioprine, etc.), and muscle ALT (more likely if AST and CK concurrently increased).

REFERRING VET

Dr. Vivian Ng

Specific recommendations for this patient include testing for Leptospirosis followed by an empirical course of antibiotics +/- Ursodiol and Denamarin given the mild gallbladder changes. If ALT does not improve with empirical therapy and/or progresses, a liver biopsy is indicated.

INVOICE

35128

DATE

1/26/22



PATIENT

Hydrox Paolucci

SPECIES

Canine

BREED

Mixed

SEX

Spayed Female

AGE

10 Years

WEIGHT

49.1 Pounds

INTERPRETED BY

Beth Johnson, DVM
DACVIM

IMAGING PERFORMED BY

Kelly Vazquez

HOSPITAL NAME

Animal General
on the Hudson

REFERRING VET

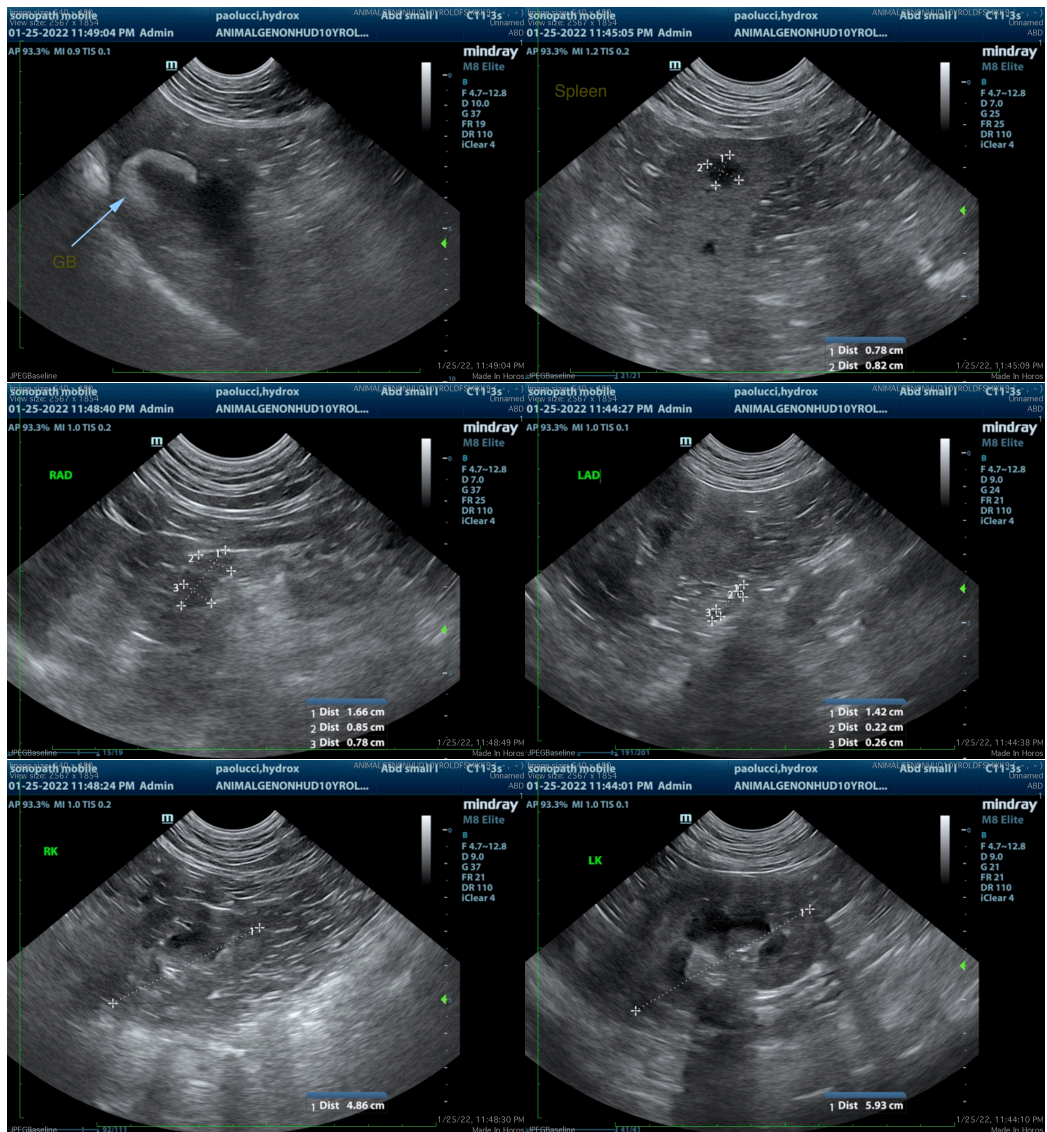
Dr. Vivian Ng

INVOICE

35128

DATE

1/26/22



The information and recommendations provided are based on the images presented by the referring veterinarian/sonographer. No evaluation can be communicated regarding pathology that was not visible in the image/video clips provided.

Thank you for this referral. If the clinical or image interpretation does not parallel your findings or if I can be of any further assistance please contact me.

Beth Johnson, DVM, DACVIM
Beth.Johnson@sonopath.com