



PATIENT

Snoopy Curanovic

SPECIES

Canine

BREED

Shih Tzu

SEX

Intact Male

AGE

13 Years

WEIGHT

19.6 Pounds

INTERPRETED BY

Beth Johnson, DVM
DACVIM

IMAGING PERFORMED BY

Kelly Vazquez

HOSPITAL NAME

Animal General
on the Hudson

REFERRING VET

Dr. Stefanie Lang

INVOICE

44503

DATE

1/25/23

PRESENTING CLINICAL SIGNS

History of elevated ALT - increasing over the last year, newly diagnosed heart murmur, asymptomatic. Owner reports no signs of liver disease. Current meds: none.

Abnormal PE/Chem/CBC/UA Results: ALT - 436 in January 2023, 265 in January 2022.

ULTRASONOGRAPHIC EXAMINATION OF THE ABDOMEN

Urinary System

Urinary bladder is only mildly distended (empty). Visible contents are anechoic. Urinary bladder wall is unable to be fully assessed for pathology without further distension. No visible masses or cystoliths are observed. The trigone and visible pelvic urethra are normal thickness with a smooth mucosal surface. If there are urinary signs and/or concern for urinary bladder pathology, reassessment after complete filling is recommended.

Prostate is normal in size for an intact male (2.42 cm wide). Parenchyma is diffusely homogenous and relatively hyperechoic. Normal distinct margins and symmetrical bilobed shape are maintained.

The right kidney is normal in size (5.09 cm), shape and echogenicity. It has smooth peripheral margination. There is a normal 1:3 cortex to medulla ratio with appropriate corticomedullary distinction. There is no evidence of pyelectasia or infarcts observed. A non-obstructive nephrolith that is approximately 0.50 cm is noted.

The left kidney is normal in size (4.03 cm), shape and echogenicity. It has smooth peripheral margination. There is a normal 1:3 cortex to medulla ratio with appropriate corticomedullary distinction. There is no evidence of pyelectasia, mineral or infarcts observed.

Adrenal Glands

The right adrenal gland is normal in size (1.69 cm long x 0.89 cm at the cranial pole and 0.55 cm at the caudal pole), shape and contour. Corticomedullary structure is unremarkable. Visible surrounding vasculature appears normal.

The left adrenal gland is normal in size (1.94 cm long x 0.57 cm at the cranial pole and 0.48 cm at the caudal pole), shape and contour. Corticomedullary structure is unremarkable. Visible surrounding vasculature appears normal.

Spleen

The spleen is subjectively normal in size with a normal smooth capsular contour. Parenchyma is appropriately finely textured and homogenous with normal echogenicity relative to surrounding tissue (hyperechoic to liver). No focal nodules or masses are observed. Splenic vasculature appears normal.

Liver

Liver is subjectively enlarged (swollen contour) without disruption of architecture. It has a normal homogenous echotexture. Parenchyma is diffusely hyperechoic characterized by less prominent than normal portal vein walls and increased echogenicity relative to the spleen and falciform fat. No focal lesions are observed. Visible vasculature and biliary tree appear normal without distension or congestion. A normal 1:1 portal vein to caudal vena cava ratio is visualized.

The gallbladder is non-distended in size. The wall is smooth without visible thickening. Luminal contents are primarily anechoic. There is no evidence of cystic or common bile duct dilation.



PATIENT

Snoopy Curanovic

SPECIES

Canine

BREED

Shih Tzu

SEX

Intact Male

AGE

13 Years

WEIGHT

19.6 Pounds

INTERPRETED BY

Beth Johnson, DVM
DACVIM

IMAGING PERFORMED BY

Kelly Vazquez

HOSPITAL NAME

Animal General
on the Hudson

REFERRING VET

Dr. Stefanie Lang

INVOICE

44503

DATE

1/25/23

Gastrointestinal

The stomach wall is normal in thickness (canine < 0.5 cm and feline < 0.4 cm) and layering. The lumen of the stomach is empty with no evidence of obstruction, foreign material or infiltrative disease. Pyloric outflow tract appears patent.

The visible small intestines are normal in wall thickness and layering (canine duodenum < 0.5 cm and feline duodenum < 0.4 cm; other < 0.3 cm). Small intestinal motility appears adequate (1-3 contractions per min). The lumen of the small intestine is empty with no evidence of obstruction, foreign material or infiltrative disease.

The visible colon is normal in wall thickness (< 0.2 cm) and layering. Contents are consistent with normal formed feces and gas.

Pancreas

The pancreatic parenchyma is appropriately isoechoic to surrounding tissue. Visible capsule is smooth and normal in contour. There is no visible pancreatic duct dilation. There is no evidence of active peripancreatic inflammation.

Free Abdomen

There is no evidence of free peritoneal effusion noted in these images.

There is no apparent lymphadenopathy noted in these images.

Both testicles are visualized without evident testicular pathology.

ULTRASONOGRAPHIC FINDINGS

- **Hyperechoic hepatomegaly** - This appearance is non-specific and most consistent with a benign steroid (endocrine) or vacuolar hepatopathy or reactive or idiopathic hepatopathy. Inflammatory and/or infiltrative disease (such as round cell neoplasia) are also possible, but considered less likely.
- Non-obstructive nephrolith in the right kidney

INTERPRETATION OF THE FINDINGS & FURTHER RECOMMENDATIONS

An obvious cause for the reported increased liver enzymes is not identified in these images. Microscopic disease such as Leptospirosis, bacterial cholangiohepatitis, chronic active hepatitis, copper-associated hepatotoxicity, other hepatotoxicity, infiltrative neoplasia (considered unlikely), etc. cannot be definitively ruled out.

Testing for Leptospirosis is recommended. Bile acids are recommended, if tbili is not increased. An empirical course of antibiotics and hepatic nutraceuticals may be tried empirically; however, ultimately, tissue sampling is likely warranted. FNA of the liver can be performed to assess inflammatory cell type, rule in/out round cell neoplasia, etc. If round cell neoplasia is not diagnosed, a liver biopsy (including copper level assessment) may be required to definitively diagnose the underlying hepatopathy.



PATIENT

Snoopy Curanovic

SPECIES

Canine

BREED

Shih Tzu

SEX

Intact Male

AGE

13 Years

WEIGHT

19.6 Pounds

INTERPRETED BY

Beth Johnson, DVM
DACVIM

IMAGING PERFORMED BY

Kelly Vazquez

HOSPITAL NAME

Animal General
on the Hudson

REFERRING VET

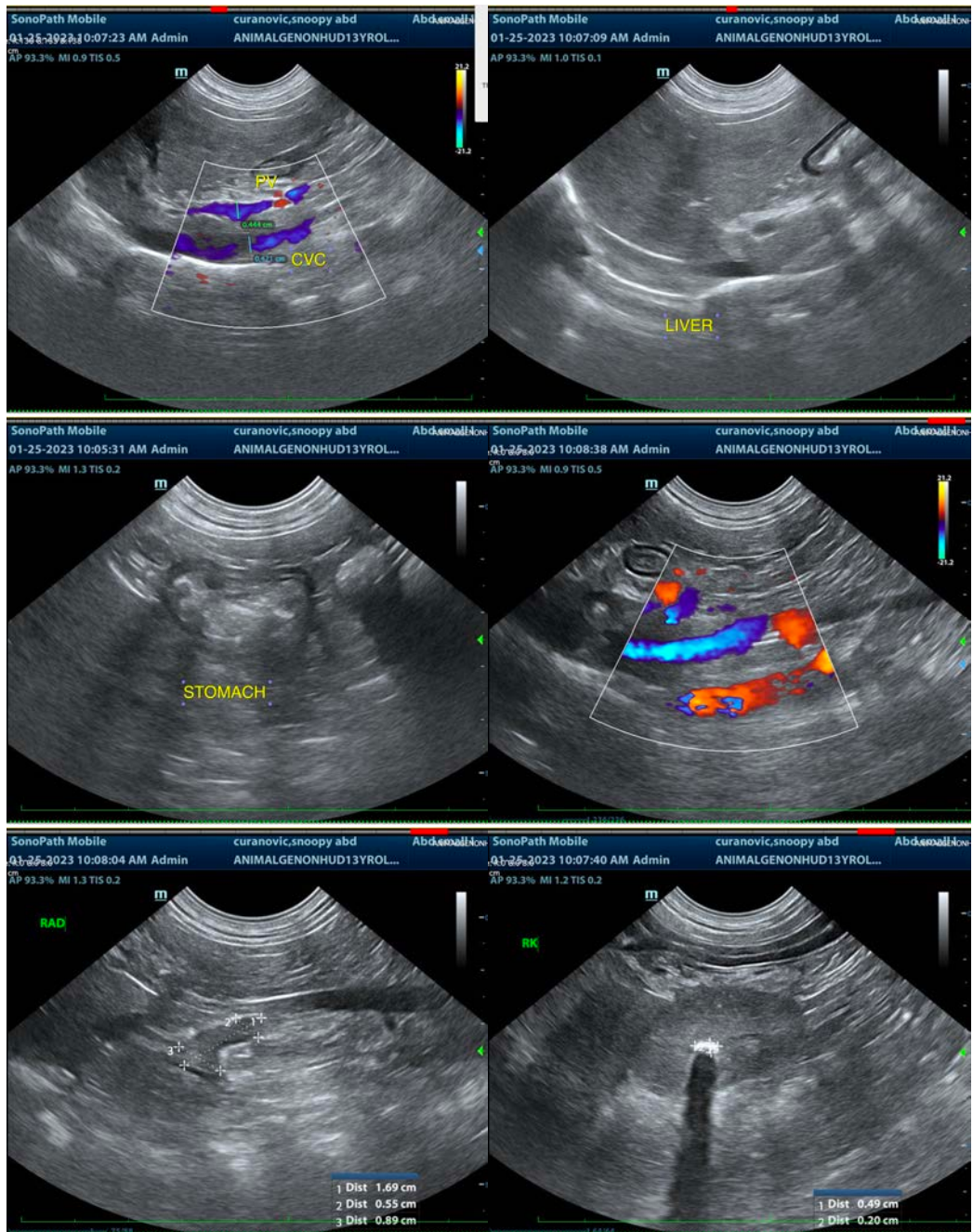
Dr. Stefanie Lang

INVOICE

44503

DATE

1/25/23





PATIENT

Snoopy Curanovic

SPECIES

Canine

BREED

Shih Tzu

SEX

Intact Male

AGE

13 Years

WEIGHT

19.6 Pounds

INTERPRETED BY

Beth Johnson, DVM
DACVIM

IMAGING PERFORMED BY

Kelly Vazquez

HOSPITAL NAME

Animal General
on the Hudson

REFERRING VET

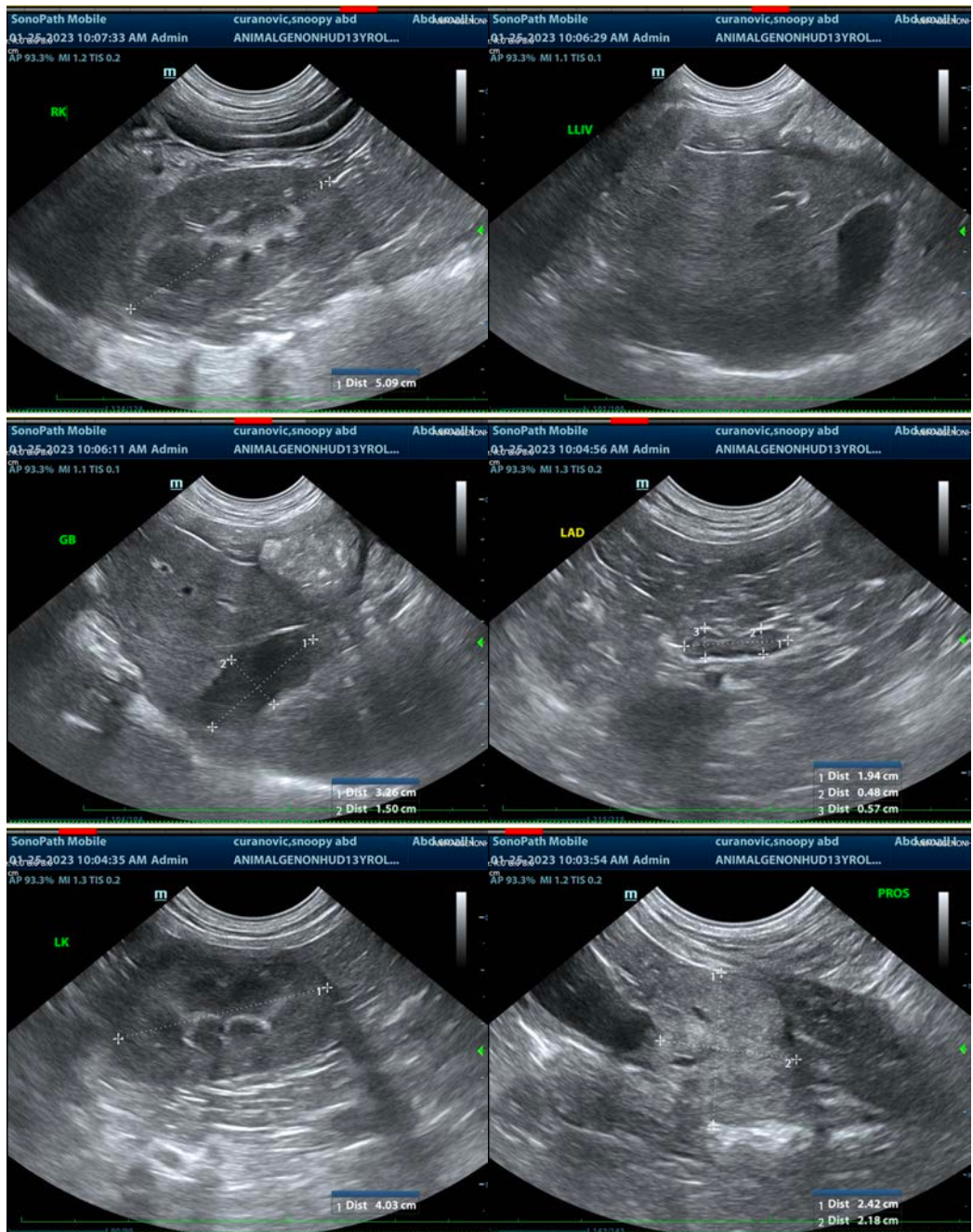
Dr. Stefanie Lang

INVOICE

44503

DATE

1/25/23





PATIENT

Snoopy Curanovic

SPECIES

Canine

BREED

Shih Tzu

SEX

Intact Male

AGE

13 Years

WEIGHT

19.6 Pounds

INTERPRETED BY

Beth Johnson, DVM
DACVIM

IMAGING PERFORMED BY

Kelly Vazquez

HOSPITAL NAME

Animal General
on the Hudson

REFERRING VET

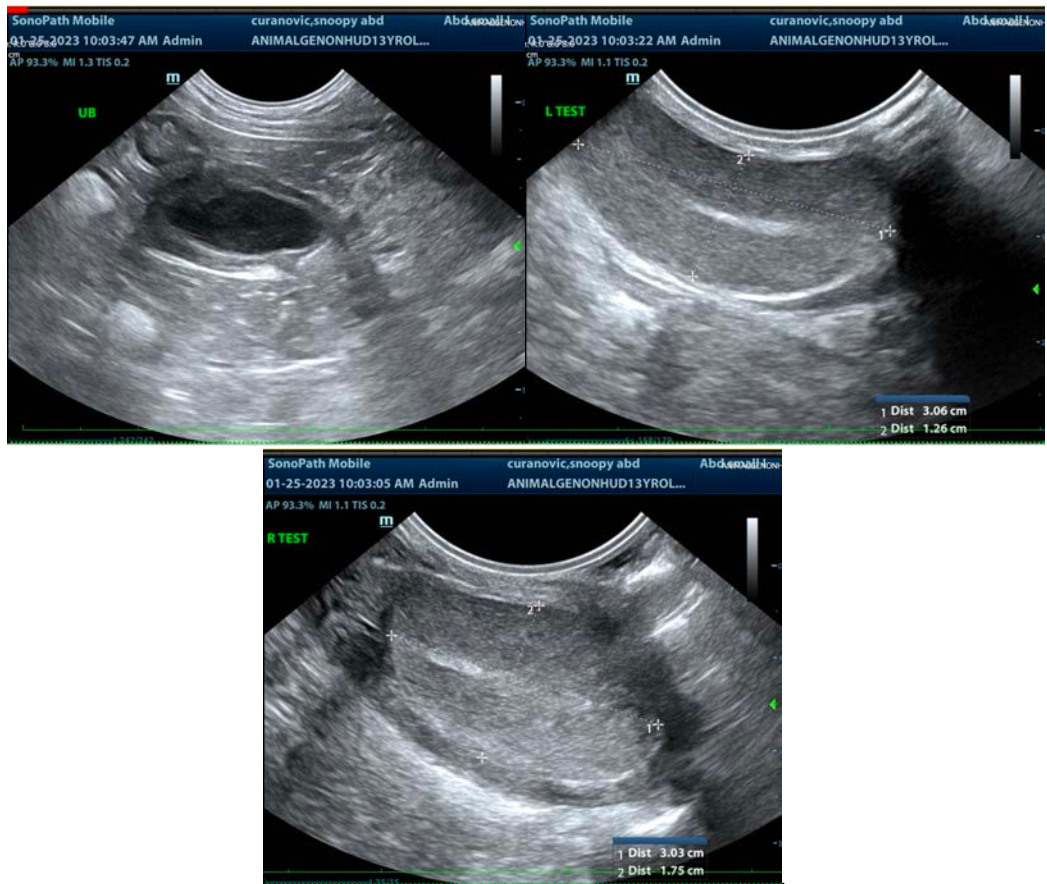
Dr. Stefanie Lang

INVOICE

44503

DATE

1/25/23



The information and recommendations provided are based on the images presented by the referring veterinarian/sonographer. No evaluation can be communicated regarding pathology that was not visible in the image/video clips provided.

Thank you for this referral. If the clinical or image interpretation does not parallel your findings or if I can be of any further assistance please contact me.

Beth Johnson, DVM, DACVIM
Beth.Johnson@sonopath.com