



PATIENT PRESENTING CLINICAL SIGNS

Finn Traendly Chronic lethargy, not eating, elevated liver values

SPECIES

Abnormal PE/Chem/CBC/UA Results: Today ALP: 1694, ALT: 201 GGT: 19 1/20/2023: ALP 1922, ALT: 218, GGT: 38

Canine

ULTRASONOGRAPHIC EXAMINATION OF THE ABDOMEN

BREED

Urinary System

Poodle Mix

Urinary bladder is moderately distended with anechoic contents. No masses, inflammatory changes, echogenic sediment or cystoliths are observed. The urinary bladder, trigone and visible pelvic urethra are normal in thickness with a smooth mucosal surface.

SEX

Right kidney is normal in size (6.2 cm), shape and echogenicity. It has smooth peripheral margination. There is a normal 1:3 cortex to medulla ratio with appropriate corticomedullary distinction. There is no evidence of pyelectasia, mineral or infarcts observed.

M

AGE

Left kidney is normal in size (5.24 cm), shape and echogenicity. It has smooth peripheral margination. There is a normal 1:3 cortex to medulla ratio with appropriate corticomedullary distinction. There is no evidence of pyelectasia, mineral or infarcts observed.

9

The prostate is unable to be well visualized.

WEIGHT

Adrenal Glands

16.7

Right adrenal gland is unable to be well visualized.

Left adrenal gland is normal in size (0.7 cm at cranial pole and 0.6 cm at caudal pole), shape and contour. Corticomedullary structure is unremarkable. Visible surrounding vasculature appears normal.

INTERPRETED BY

Beth Johnson, DVM
DACVIM

Spleen

Spleen is subjectively normal in size with a normal smooth capsular contour. Parenchyma is appropriately finely textured and homogenous with normal echogenicity relative to surrounding tissue (hyperechoic to liver). No focal nodules or masses are observed. Splenic vasculature appears normal.

IMAGING PERFORMED BY

Hope Brossman

Liver

Liver is subjectively enlarged (swollen contour) without disruption of architecture. It has a normal homogenous echotexture. Parenchyma is diffusely hyperechoic characterized by less prominent than normal portal vein walls and increased echogenicity relative to the spleen and falciform fat. No focal lesions are observed. Visible vasculature and biliary tree appear normal without distension or congestion. Portal vein to CVC ratio is normal at 1:1.

HOSPITAL NAME

Animal Mansion
Veterinary Hospital

REFERRING VET

Dr. Bertoldo

Gallbladder is moderately distended with anechoic bile as well as suspended and gravity dependent echogenic debris. The wall is smooth without visible thickening. There is no evidence of cystic or CBD dilation. There is no evidence of effusion or inflammation.

INVOICE

12782ag

Gastrointestinal

The stomach wall is normal in thickness (canine < 0.5 cm and feline < 0.4 cm) and layering. The lumen of the stomach is empty with no evidence of obstruction, foreign material or infiltrative disease. Pyloric outflow tract appears patent.

DATE

01/25/2023

The visible small intestines are normal in wall thickness and layering (canine duodenum < 0.5 cm and feline duodenum < 0.4 cm; other < 0.3 cm). Small intestinal motility appears adequate (1-3 contractions per min). The lumen of the small intestine is mildly distended with echogenic non-shadowing luminal



PATIENT

contents and gas consistent with normal ingesta. There is no evidence of obstruction or foreign material noted.

Finn Traendly

The visible colon is normal in wall thickness (< 0.2 cm) and layering. Contents are consistent with normal formed feces and gas.

SPECIES

Canine

Pancreas

Pancreatic parenchyma is appropriately isoechoic to surrounding tissue. Visible capsule is smooth and normal in contour. There is no visible pancreatic duct dilation. There is no evidence of active peripancreatic inflammation.

BREED

Poodle Mix

Free Abdomen

There is no evidence of peritoneal effusion. There is no apparent lymphadenopathy.

SEX

ULTRASONOGRAPHIC FINDINGS

M

- Hypoechoic hepatomegaly – This appearance is consistent with an acute hepatopathy or acute cholangiohepatitis. Infiltrative neoplasia (round cell neoplasia) should also be considered.
- Very mid gallbladder debris (canine) - Cholecystic debris is of unknown clinical significance. It can be seen with biliary stasis from fasting or illness. Cholecystic debris is not necessarily related to hepatobiliary disease. Echogenic bile is most commonly an incidental finding in dogs and should be interpreted in combination with clinical signs such as nausea, inappetence, cranial abdominal discomfort and/or laboratory changes such as increased ALP and/or increased Tbili.
- An obvious cause for the reported increased liver enzymes is not identified in these images. Microscopic disease such as Leptospirosis, bacterial cholangiohepatitis, chronic active hepatitis, copper-associated hepatotoxicity, other hepatotoxicity, infiltrative neoplasia (considered unlikely), etc. cannot be definitively ruled out.

AGE

9

WEIGHT

16.7

INTERPRETED BY

Beth Johnson, DVM
DACVIM

INTERPRETATION OF THE FINDINGS & FURTHER RECOMMENDATIONS

1. If improvement is not noted and enzyme increase progresses liver sampling beginning with a FNA of the liver if the patient's coagulation status is appropriate and/or progressing to a liver biopsy including copper level assessment may be warranted. Additionally supportive medical management including antiemetics, gastric protectants and an appetite stimulant +/- fluid therapy if indicated are recommended.

IMAGING PERFORMED BY
Hope Brossman

HOSPITAL NAME

Animal Mansion
Veterinary Hospital

REFERRING VET

Dr. Bertoldo

INVOICE

12782ag

DATE

01/25/2023



PATIENT

Finn Traendly

SPECIES

Canine

BREED

Poodle Mix

SEX

M

AGE

9

WEIGHT

16.7

INTERPRETED BY

Beth Johnson, DVM
DACVIM

IMAGING PERFORMED BY
Hope Brossman

HOSPITAL NAME

Animal Mansion
Veterinary Hospital

REFERRING VET

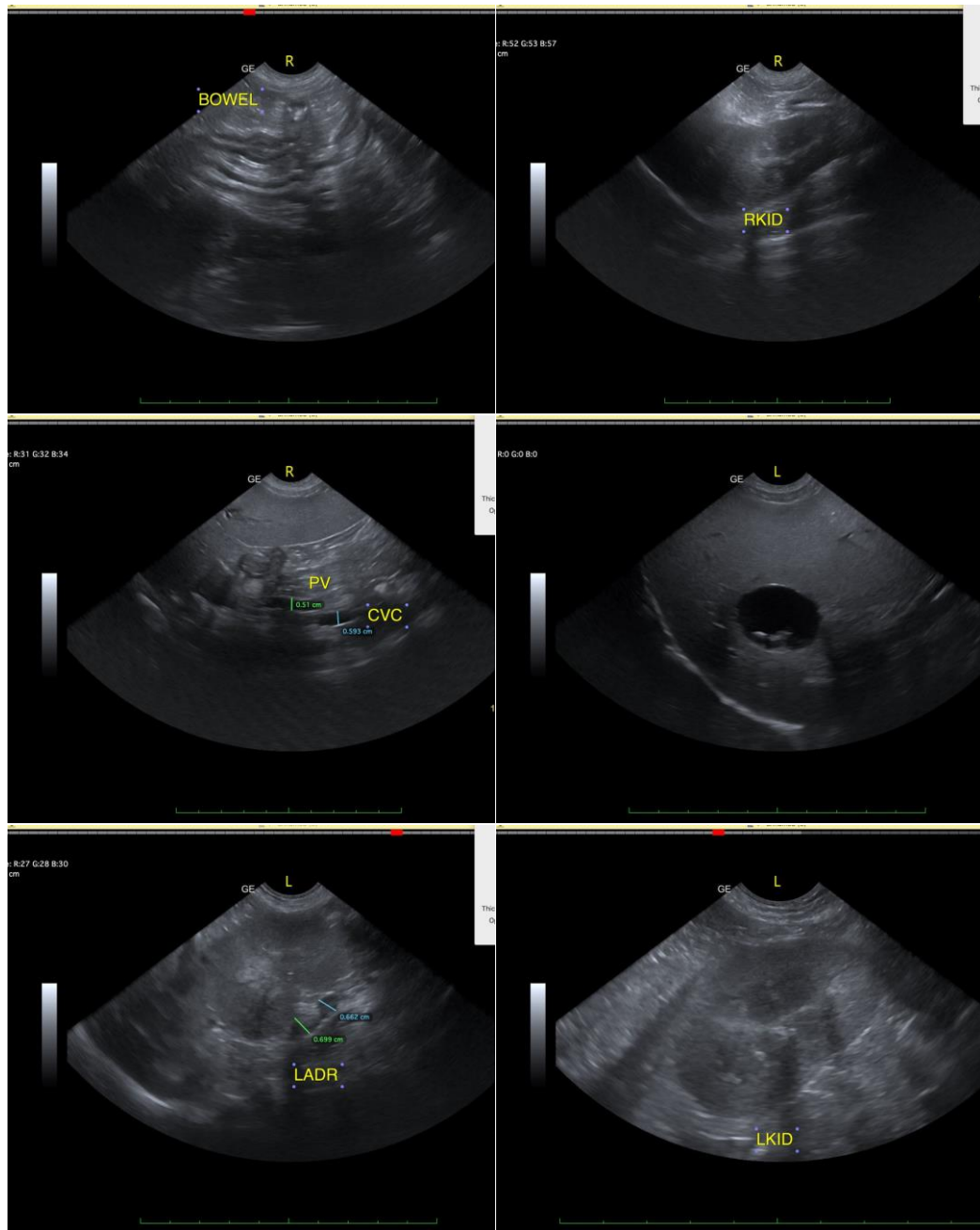
Dr. Bertoldo

INVOICE

12782ag

DATE

01/25/2023



The information and recommendations provided are based on the images presented by the referring veterinarian/sonographer. No evaluation can be communicated regarding pathology that was not visible in the image/video clips provided.

Thank you for this referral. If the clinical or image interpretation does not parallel your findings or if I can be of any further assistance please contact me.

Beth Johnson, DVM DACVIM

Beth.Johnson@SonoPath.com



PATIENT

Finn Traendly

SPECIES

Canine

BREED

Poodle Mix

SEX

M

AGE

9

WEIGHT

16.7

INTERPRETED BY

Beth Johnson, DVM
DACVIM

**IMAGING
PERFORMED BY**

Hope Brossman

HOSPITAL NAME

Animal Mansion
Veterinary Hospital

REFERRING VET

Dr. Bertoldo

INVOICE

12782ag

DATE

01/25/2023