



<b>PATIENT</b>	<b>PRESENTING CLINICAL SIGNS</b>
Scooby Weinstock	Patient presents for weight loss, was 19 lbs, now 13.6 lbs. Abnormal PE/Chem/CBC/UA Results: Precision PSL (high).
<b>SPECIES</b>	<b>ULTRASONOGRAPHIC EXAMINATION OF THE ABDOMEN</b>
Canine	<b>Urinary System</b>
<b>BREED</b>	The urinary bladder is moderately distended with anechoic contents. No masses, inflammatory changes, echogenic sediment or cystoliths are observed. The urinary bladder, trigone and visible pelvic urethra are normal in thickness with a smooth mucosal surface.
Miniature Pinscher	Prostate (neutered) is normal in size, echotexture and echogenicity for a neutered male.
<b>SEX</b>	The right kidney is normal in size (3.65 cm), shape and echogenicity. It has smooth peripheral margination. There is a normal 1:3 cortex to medulla ratio with appropriate corticomedullary distinction. There is no evidence of pyelectasia, mineral or infarcts observed.
Neutered Male	
<b>AGE</b>	The left kidney is normal in size (4.43 cm), shape and echogenicity. It has smooth peripheral margination. There is a normal 1:3 cortex to medulla ratio with appropriate corticomedullary distinction. There is no evidence of pyelectasia, mineral or infarcts observed.
11 Years 9 Months	
<b>WEIGHT</b>	<b>Adrenal Glands</b>
13.6 Pounds	The right adrenal gland is normal in size (2.0 cm long x 1.0 cm at the cranial pole and 0.53 cm at the caudal pole), shape and contour. Corticomedullary structure is unremarkable. Visible surrounding vasculature appears normal.
<b>INTERPRETED BY</b>	The left adrenal gland is normal in size (1.5 cm long x 0.61 cm at the cranial pole and 0.67 cm at the caudal pole), shape and contour. Corticomedullary structure is unremarkable. Visible surrounding vasculature appears normal.
Beth Johnson, DVM DACVIM	
<b>IMAGING PERFORMED BY</b>	<b>Spleen</b>
Kelly Vazquez	The spleen is subjectively normal in size with a normal smooth capsular contour. Parenchyma is appropriately finely textured and homogenous with normal echogenicity relative to surrounding tissue (hyperechoic to liver). No focal nodules or masses are observed. Splenic vasculature appears normal.
<b>HOSPITAL NAME</b>	<b>Liver</b>
Brenda King Vet	The liver is subjectively normal in size with normal smooth curvilinear peripheral contour. Parenchyma is appropriately hypoechoic to the spleen in echogenicity and appropriately mildly coarse and homogenous in echotexture. No focal lesions are observed. Visible vasculature and biliary tree appear normal without distension or congestion.
<b>REFERRING VET</b>	The gallbladder is moderately distended with anechoic bile and gravity dependent echogenic sediment. The wall is smooth without visible thickening. There is no evidence of cystic or CBD dilation. There is no evidence of effusion or inflammation.
Dr. Brenda King	
<b>INVOICE</b>	<b>Gastrointestinal</b>
35088	Gastric fundic mucosal hypertrophy with hyperechoic mucosa and some mucosal remodeling is noted. There is no loss of mural detail. Layering is normal, but overall slightly increased in thickness, measuring 0.7 cm thick. There is mild luminal fluid accumulation. No evidence of masses/nodules or foreign material present.
<b>DATE</b>	
1/26/22	



**PATIENT**

Scooby Weinstock

The visible small intestines are normal in wall thickness and layering (canine duodenum < 0.5 cm and feline duodenum < 0.4 cm; other < 0.3 cm). Small intestinal motility appears adequate (1-3 contractions per min). The lumen of the small intestine is empty with no evidence of obstruction, foreign material or infiltrative disease.

**SPECIES**

Canine

The visible colon is normal in wall thickness (< 0.2 cm) and layering. Contents are consistent with normal formed feces and gas.

**Pancreas**

**BREED**

Miniature Pinscher

The pancreatic parenchyma is appropriately isoechoic to surrounding tissue. Visible capsule is smooth and normal in contour. There is no visible pancreatic duct dilation. There is no evidence of active peripancreatic inflammation.

**SEX**

Neutered Male

**Free Abdomen**

There is no evidence of peritoneal effusion. There is no apparent lymphadenopathy.

**ULTRASONOGRAPHIC FINDINGS**

**AGE**

11 Years 9 Months

- Gastritis and mild diffuse gastric wall thickening – Microulceration cannot be ruled out.
- Gallbladder debris - Cholecystic debris is of unknown clinical significance. It can be seen with biliary stasis from fasting or illness. Cholecystic debris is not necessarily related to hepatobiliary disease. Echogenic bile is most commonly an incidental finding in dogs and should be interpreted in combination with clinical signs such as nausea, inappetence, cranial abdominal discomfort and/or laboratory changes such as increased ALP and/or increased Tbili.

**WEIGHT**

13.6 Pounds

**INTERPRETATION OF THE FINDINGS & FURTHER RECOMMENDATIONS**

**INTERPRETED BY**

Beth Johnson, DVM  
DACVIM

Given this patient's history of weight loss, the first recommendation is to double check the patient's daily caloric intake in case diet has changes or feeding regiment has changed and the patient is not receiving enough calories and/or determine if the patient's weight loss is due to decreased appetite versus decreased absorption, etc.

**IMAGING PERFORMED BY**

Kelly Vazquez

If appetite is normal and caloric intake is normal, recommendations include a gastrointestinal malabsorption panel including TLI, PLI, folate and cobalamin, as well as a baseline cortisol to Texas A&M GI laboratory followed by empirical deworming with a 5 day course of Panacur as well as antacid therapy given the evidence of mild gastritis and gastric wall thickening. If weight loss persists in the face of normal caloric intake, the next step may need to be gastroscopy/endoscopy to further assess the gastric and duodenal mucosa with biopsies.

**HOSPITAL NAME**

Brenda King Vet

**REFERRING VET**

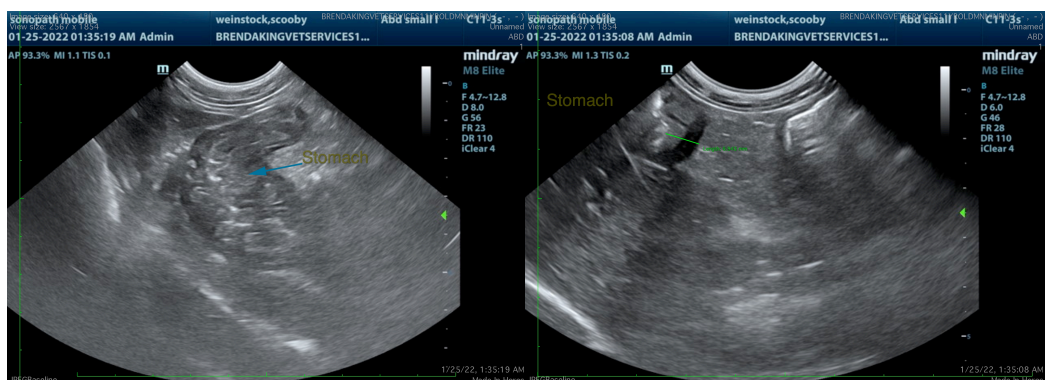
Dr. Brenda King

**INVOICE**

35088

**DATE**

1/26/22





**PATIENT**

Scooby Weinstock

**SPECIES**

Canine

**BREED**

Miniature Pinscher

**SEX**

Neutered Male

**AGE**

11 Years 9 Months

**WEIGHT**

13.6 Pounds

**INTERPRETED BY**

Beth Johnson, DVM  
DACVIM

**IMAGING PERFORMED BY**

Kelly Vazquez

**HOSPITAL NAME**

Brenda King Vet

**REFERRING VET**

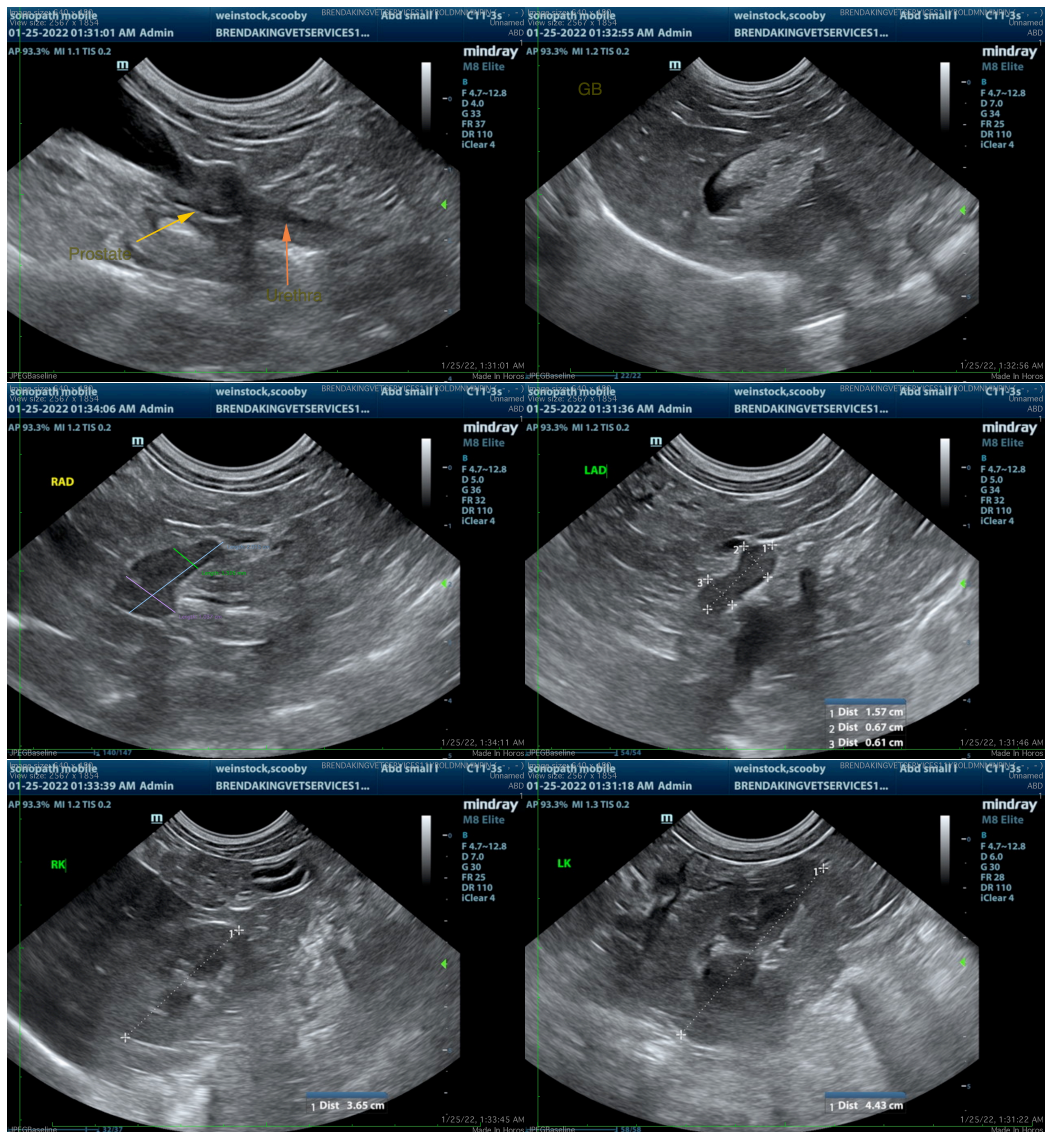
Dr. Brenda King

**INVOICE**

35088

**DATE**

1/26/22



The information and recommendations provided are based on the images presented by the referring veterinarian/sonographer. No evaluation can be communicated regarding pathology that was not visible in the image/video clips provided.

Thank you for this referral. If the clinical or image interpretation does not parallel your findings or if I can be of any further assistance please contact me.

**Beth Johnson, DVM, DACVIM**  
Beth.Johnson@sonopath.com