

**DATE PRESENTING CLINICAL SIGNS**

1/24/23 Hx of trouble with rear legs, increase in water drinking, decreased appetites, urinary accident. Exam findings showed tachycardia, discomfort in rear legs.

**PATIENT**

Clyde Koerner  
 Current Medications: None.  
 Lab Results: Albumin 2.3, SDMA 17.8, AST 232, Glob 4.9, Urine protein 1+, Sp grav 1.012  
 Date of Previous IntraPet Ultrasound: No previous.  
 Sedation: Not required to complete full diagnostic ultrasound.  
 Stat Report: Not requested.  
 Imaging Performed By: Stephanie Warga RDCS, RVT.

**SPECIES**

Canine

**BREED**

Labrador X

**SEX**

Neutered Male

**AGE**

1/1/14

**WEIGHT**

100 Pounds

**INTERPRETED BY**

Beth Johnson, DVM  
 DACVIM

**HOSPITAL NAME**

Bel Air Vet Hospital

**REFERRING VET**

Dr. Schmidt

**INVOICE**

44456

**ULTRASONOGRAPHIC EXAMINATION OF THE ABDOMEN****Urinary System**

Urinary bladder is adequately distended. It has a normal uniform wall thickness. Contents include primarily anechoic fluid with occasional echogenic non-shadowing debris, most consistent with exfoliated cells, mucous and/or small blood clots. Mineral sand/debris creating an acoustic shadow is noted. Both sterile inflammation as well as urinary tract infection can also present with echogenic debris. No masses observed. The trigone and visible pelvic urethra are normal in thickness with a smooth mucosal surface.

Prostate is normal in size, echotexture and echogenicity for a neutered male.

The right kidney is normal in size (8.23 cm), shape and echogenicity. It has smooth peripheral margination. There is a normal 1:3 cortex to medulla ratio with appropriate corticomedullary distinction. There is no evidence of pyelectasia or infarcts observed. Tiny non-obstructive nephroliths are noted.

The left kidney is normal in size (7.36 cm), shape and echogenicity. It has smooth peripheral margination. There is a normal 1:3 cortex to medulla ratio with appropriate corticomedullary distinction. There is no evidence of pyelectasia or infarcts observed. Tiny non-obstructive nephroliths are noted.

**Adrenal Glands**

The right adrenal gland is normal in size (2.49 cm long x 0.65 cm at the cranial pole and 0.69 cm at the caudal pole), shape and contour. Corticomedullary structure is unremarkable. Visible surrounding vasculature appears normal.

The left adrenal gland is normal in size (2.99 cm long x 0.63 cm at the cranial pole and 0.80 cm at the caudal pole), shape and contour. Corticomedullary structure is unremarkable. Visible surrounding vasculature appears normal.

**Spleen**

The spleen is subjectively normal in size with a normal smooth capsular contour. Parenchyma is appropriately finely textured and homogenous with normal echogenicity relative to surrounding tissue (hyperechoic to liver). No focal nodules or masses are observed. Splenic vasculature appears normal.

**Liver**

The liver is subjectively normal in size with normal smooth curvilinear peripheral contour. Parenchyma is appropriately hypoechoic to the spleen in echogenicity and appropriately mildly coarse and homogenous in echotexture. No focal lesions are observed. Visible vasculature and biliary tree appear normal without distension or congestion.

Gallbladder is moderately distended with anechoic bile as well as mild suspended and gravity dependent echogenic debris. The wall is smooth without visible thickening. There is no evidence of cystic or CBD dilation. There is no evidence of effusion or inflammation.

### ***Gastrointestinal***

The stomach wall is normal in thickness (canine < 0.5 cm and feline < 0.4 cm) and layering. The lumen of the stomach is empty with no evidence of obstruction, foreign material or infiltrative disease. Pyloric outflow tract appears patent.

The visible small intestines are normal in wall thickness and layering (canine duodenum < 0.5 cm and feline duodenum < 0.4 cm; other < 0.3 cm). Small intestinal motility appears adequate (1-3 contractions per min). The lumen of the small intestine is empty with no evidence of obstruction, foreign material or infiltrative disease.

The visible colon is normal in wall thickness (< 0.2 cm) and layering. Contents are consistent with normal formed feces and gas.

### ***Pancreas***

The pancreatic parenchyma is appropriately isoechoic to surrounding tissue. Visible capsule is smooth and normal in contour. There is no visible pancreatic duct dilation. There is no evidence of active peripancreatic inflammation.

### ***Free Abdomen***

There is no evidence of free peritoneal effusion noted in these images.

The medial iliac and gastric/pancreaticoduodenal lymph nodes are prominent in size with swollen capsular contour. Normal elongated shape (length to width ratio) is maintained. There is no loss of parenchymal detail.

Ringdowns are noted at the level of the diaphragm. There is no evidence of pericardial or pleural effusion or heart base mass visible in these images. There is evidence of subjective tachycardia, which is consistent with reported physical exam findings.

## **PRIMARY FINDINGS**

- **Reactive pancreaticoduodenal and medial iliac lymph nodes** – infiltrative neoplastic disease cannot be ruled out but is considered less likely.
- **Ringdowns at the level of the diaphragm** – suggestive of possible concurrent pulmonary pathology.

## **SECONDARY FINDINGS**

- Urinary bladder mineral/sand debris with shadow, small cystoliths can't be definitively ruled out
- **Mild gallbladder debris** - Cholecystic debris is of unknown clinical significance. It can be seen with biliary stasis from fasting or illness. Cholecystic debris is not necessarily related to hepatobiliary disease. Echogenic bile is most commonly an incidental finding in dogs and should be interpreted in combination with clinical signs such as nausea, inappetence, cranial abdominal discomfort and/or laboratory changes such as increased ALP and/or increased Tbili.
- Tiny bilateral non-obstructive nephroliths

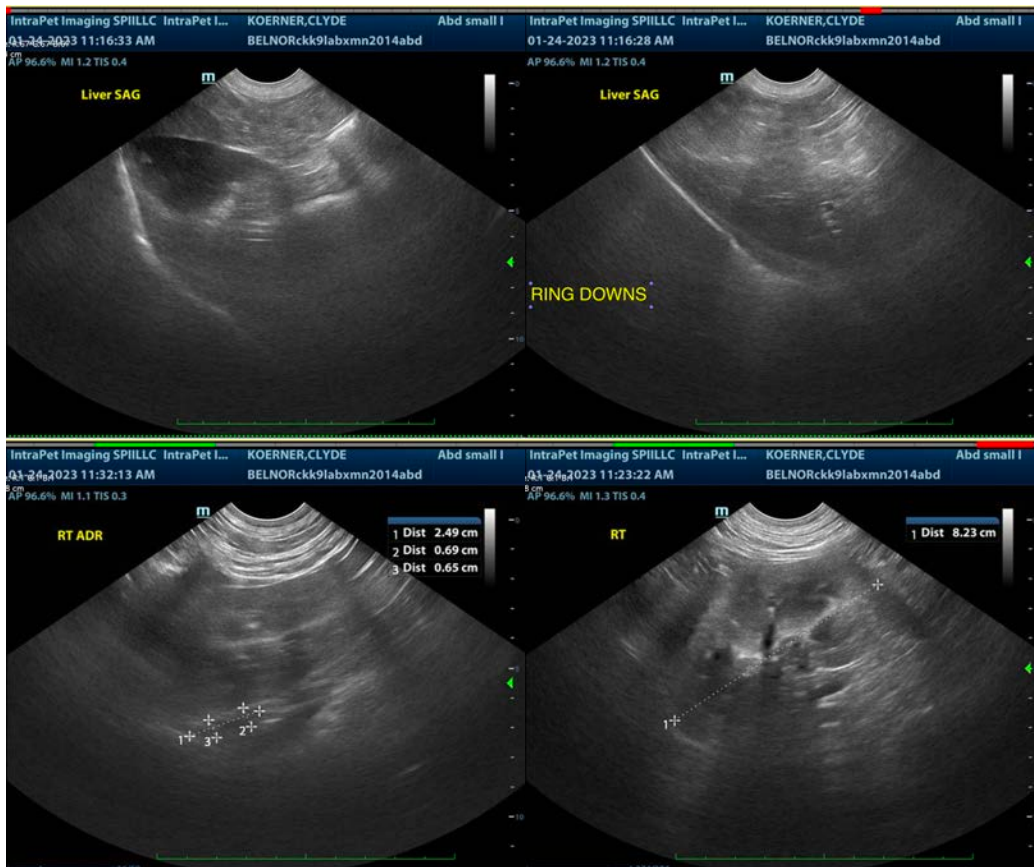
## INTERPRETATION OF THE FINDINGS & FURTHER RECOMMENDATIONS

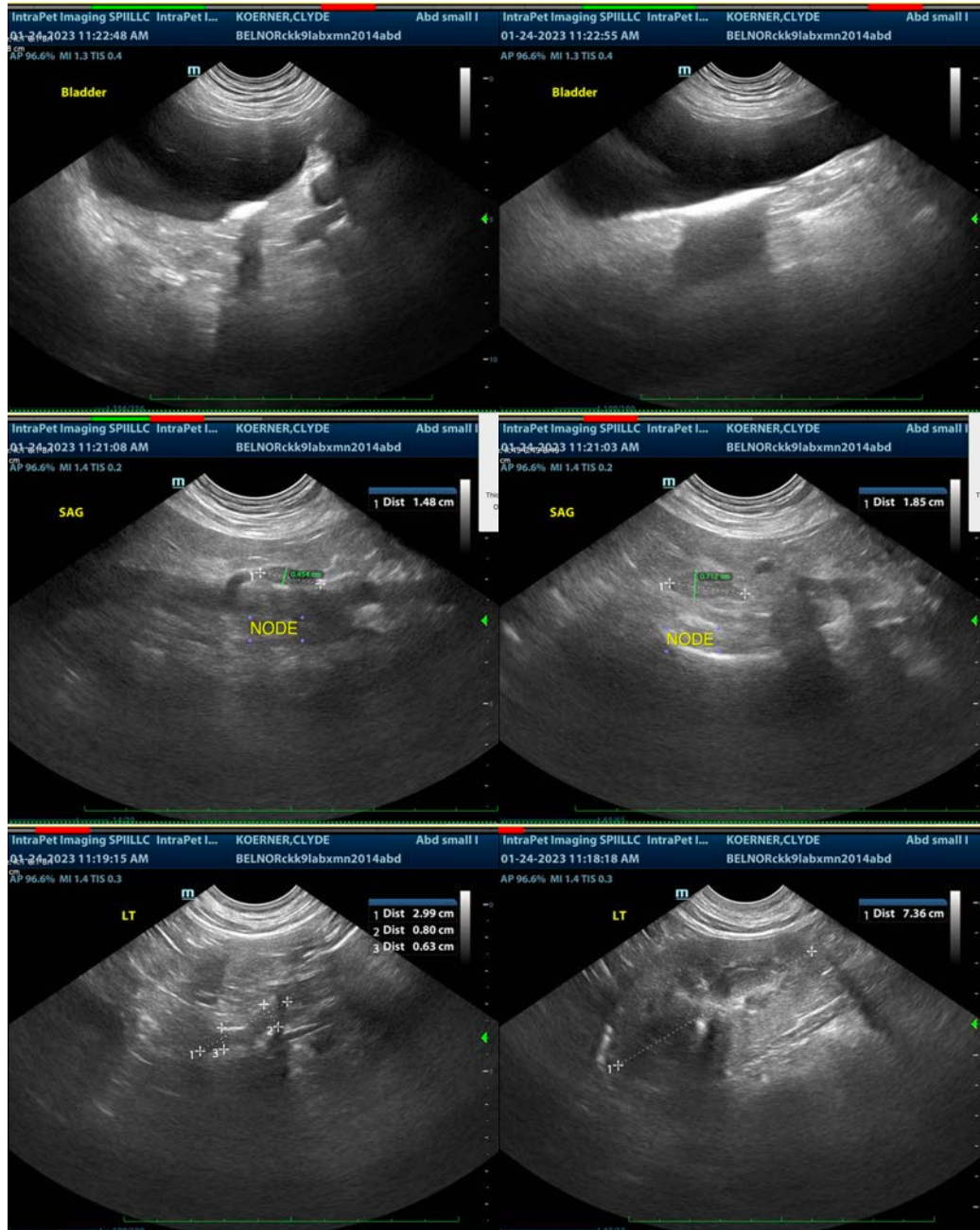
Given this patient's reported hypoalbuminemia and eosinophilia combined with non-specific clinical signs, a baseline cortisol is recommended. If baseline cortisol is less than 2, a full ACTH stimulation test is recommended to rule out hypoadrenocorticism.

For further evaluation of the hypoalbuminemia, a gastrointestinal malabsorption panel (including cobalamin, folate, TLI and PLI) to Texas A&M GI Laboratory is recommended for further evaluation of GI and pancreatic function, as well as a urine protein to creatinine ratio if the urinalysis sediment is otherwise quiet with protein present. Testing for Leptospirosis could also be considered, given the reported PU/PD, if not recently evaluated.

The tachycardia may be secondary to pain or anxiety or hypovolemia, etc. However, 3-view thoracic radiographs are recommended, as is an EKG if the tachycardia persists.

In the meantime, empirical deworming with a 5-day course of Panacur is recommended in addition to supportive/symptomatic care of clinical signs, including pain/discomfort, if indicated.





The information and recommendations provided are based on the images presented by the referring veterinarian/sonographer. No evaluation can be communicated regarding pathology that was not visible in the image/video clips provided.

Thank you for this referral. If the clinical or image interpretation does not parallel your findings or if I can be of any further assistance please contact me.

**Beth Johnson, DVM, DACVIM**  
Beth.Johnson@sonopath.com