



DATE PRESENTING CLINICAL SIGNS

1/22/26

Patient History: Presents for acute onset diarrhea beginning approximately 24 hours prior to presentation. Owner reports patient has experienced decreased appetite over the past month, attributed to severe dental disease making kibble consumption difficult. Objective: - BAR- not clinically dehydrated. MM pink, CRT 1-2 sec

PATIENT

Maizie Tober

SPECIES

Canine

BREED

Shepherd x

SEX

Spayed Female

AGE

3/15/12

WEIGHT

57.4 lbs

INTERPRETED BY

Beth Johnson, DVM
DACVIM

HOSPITAL NAME

Lutherville Animal
Hospital

REFERRING VET

Dr. Morgan

INVOICE

72400

-Severe gingivitis and dental calculus, patient would not allow complete oral cavity exam - Nuclear sclerosis OU, ~4-5 mm mass effect at the lateral aspect of the L lower eyelid with impacted meibomian gland, no current blepharospasm, no scleral injection, no signs of discomfort at this time. R eye quiet. - Ears: Quiet - Peripheral lymph nodes soft and symmetrical -Heart and lungs clear. Minor respiratory sinus arrhythmia, HR ~120 bpm, intermittent panting with increase in bronchovesicular sounds. No murmur noted. No crackles or wheezes noted. Normal respiratory rate and effort. - Mild tensing on abdominal palpation, no discrete masses palpated, not overtly painful. No fluid wave, no appreciable organomegaly. - Decreased range of motion bilateral hips consistent with degenerative joint disease, decreased muscle mass. Medial buttress of both stifles. - Historical mass noted on right lateral flank, pedunculated dermal mass on paw—stable - BCS: 3/9 with decreased muscling, weight bearing and ambulatory X 4

Current Medications: Rx Metronidazole 250 mg- 1.5 tabs PO BID for 7 days, Provable SID.

Labwork Results: Labwork not attached, reported as: Lab work overall stable, though progression in SDMA, decrease in Na/K is new.

Date of Previous IntraPet Ultrasound: No previous.

Sedation: Torbugesic.

Stat Report: Not requested.

Imaging Performed by: Stephanie Warga RDCS, RVT.

ULTRASONOGRAPHIC EXAMINATION OF THE ABDOMEN

Urinary System

The urinary bladder is adequately distended with anechoic contents. No masses, inflammatory changes, echogenic sediment or cystoliths are observed. The urinary bladder, trigone and visible pelvic urethra are normal in thickness with a smooth mucosal surface.

Kidneys are overall normal in size and shape with smooth peripheral margination. A normal 1:3 cortex to medulla ratio is maintained. The medulla and cortices are uniform in texture with some mild increased cortical echogenicity and mild loss of corticomedullary distinction, expected in this age patient. There is no evidence of mineral or infarcts observed. Left kidney measured 7.5 cm. Right kidney measured 7.14 cm. Trace pyelectasia is present bilaterally.

Adrenal Glands

The cranial pole of the right adrenal gland is normal in size (1.4 cm), shape and overall architecture, echogenicity and echotexture. Visible surrounding vasculature appears normal. The caudal pole is unable to be well visualized in these images.

The cranial pole of the left adrenal gland is enlarged (2.96 cm x 3.35 cm) with mild heterogenous parenchymal changes. Swollen capsular expansion is noted primarily within the cranial pole, where a mass measures 2.96 cm x 3.35 cm in size without evident capsular escape or vascular invasion. The caudal pole measures approximately 0.97 cm.

Spleen

Spleen is subjectively normal in size with a normal smooth capsular contour. Parenchyma is appropriately finely textured and homogenous with normal echogenicity relative to surrounding tissue (hyperechoic to liver). Multifocal well-demarcated hyperechoic homogenous nodules are noted. Splenic vasculature appears normal.

Liver

Liver is subjectively enlarged with mildly irregular margins. Parenchyma is moderately heterogenous characterized by multiple poorly defined hypoechoic nodules within otherwise hyperechoic liver parenchyma. Visible vasculature and biliary tree appear normal without distension or congestion.

Gallbladder is mildly overdistended with a moderate amount of non-dependent, mildly aggregated/inspissated sludge. Hypo to anechoic cystic areas are noted between the gallbladder sludge and luminal wall. The wall is otherwise smooth without visible thickening. There is no evidence of cystic or CBD dilation. There is no evidence of effusion.

Gastrointestinal

The visible stomach wall is normal in thickness and layering. The lumen of the stomach is empty with no evidence of obstruction, foreign material or infiltrative disease. Pyloric outflow tract appears patent.

The visible small intestine demonstrates areas of moderately thick muscularis layer relative to mucosa (disruption of the normal 1:3 muscularis:mucosa ratio). Small intestinal submucosa is slightly irregular, thick and hyperechoic, without evident loss of layering appreciated. The lumen of the small intestine is empty with no evidence of obstruction or foreign material.

The visible colon is normal in wall thickness (< 0.2 cm) and layering. Contents are consistent with normal formed feces and gas.

Pancreas

The pancreas that is observed appears appropriately isoechoic to surrounding omental fat. Visible capsule is smooth and normal in contour. Visible pancreatic parenchyma is homogenous and unremarkable. There is no visible pancreatic duct dilation. There is no evidence of active peripancreatic inflammation.

Free Abdomen

There is no visible free peritoneal effusion noted in these images.

There is no apparent pathologic lymphadenopathy noted in these images.

The visible heart base (RA) and pericardium are unremarkable without obvious pathology noted in these images at this time. If cardiac function evaluation is desired, a full echocardiogram is recommended.

PRIMARY FINDINGS

- Moderate inflammatory bowel disease (IBD) pattern – Thick muscularis has been reported with infiltrative bowel disease including both benign inflammatory disease as well as infiltrative neoplasia such as lymphoma. No loss of layering or distinct characteristics of malignancy are present. Therefore, differentials cannot be further ranked without tissue sampling. **This change may be in part normal patient variant in a senior pet, although given the reported recent onset of gastrointestinal signs, a pathologic process should be ruled out.*
- The left adrenal mass could represent an adrenal adenoma versus adenocarcinoma, pheochromocytoma, or adrenal hyperplasia which can't be ruled out but is considered less likely. There are no characteristics of malignancy in these images at this time. However, malignancy can't be ruled out.
- Moderately heterogenous liver – These changes are most consistent with benign processes such as nodular hyperplasia, steroid (vacuolar) hepatopathy, extramedullary hematopoiesis or possibly chronic inflammatory disease and less commonly infiltrative round cell or metastatic neoplasia.
- Emerging mucocele – Cholecystic debris is of unknown clinical significance. It can be seen with biliary stasis from fasting or illness. Cholecystic debris is not necessarily related to hepatobiliary disease. The non-dependent nature of this sludge combined with the cystic areas are suggestive, however, of possible emerging cystic mucosal hyperplasia or early gallbladder mucocele.

SECONDARY FINDINGS

- Age related kidney changes with trace bilateral pyelectasia.
- Hyperechoic splenic nodules – most consistent with benign myelolipomas. Other differentials such as fibrosis or calcification caused by old hematomas or infarcts, chronic inflammation, granulomatous disease or metastatic disease cannot be ruled out, but are considered less likely.

INTERPRETATION OF THE FINDINGS & FURTHER RECOMMENDATIONS

Given patient's reported diarrhea, further gastrointestinal workup recommendations to consider include a routine fecal/giardia exam.

A gastrointestinal malabsorption panel (including cobalamin, folate, TLI and PLI) to Texas A&M GI Laboratory is recommended for further evaluation of GI and pancreatic function.

A fecal enteropathogen PCR panel to Texas A&M GI Laboratory could be considered for further evaluation of possible infectious disease. Contact lab for recommendations on how long to discontinue antibiotics (if indicated) prior to obtaining a stool sample for submission.

Having said that, however, while likely unrelated to the diarrhea, the adrenal mass also warrants further evaluation if elected.

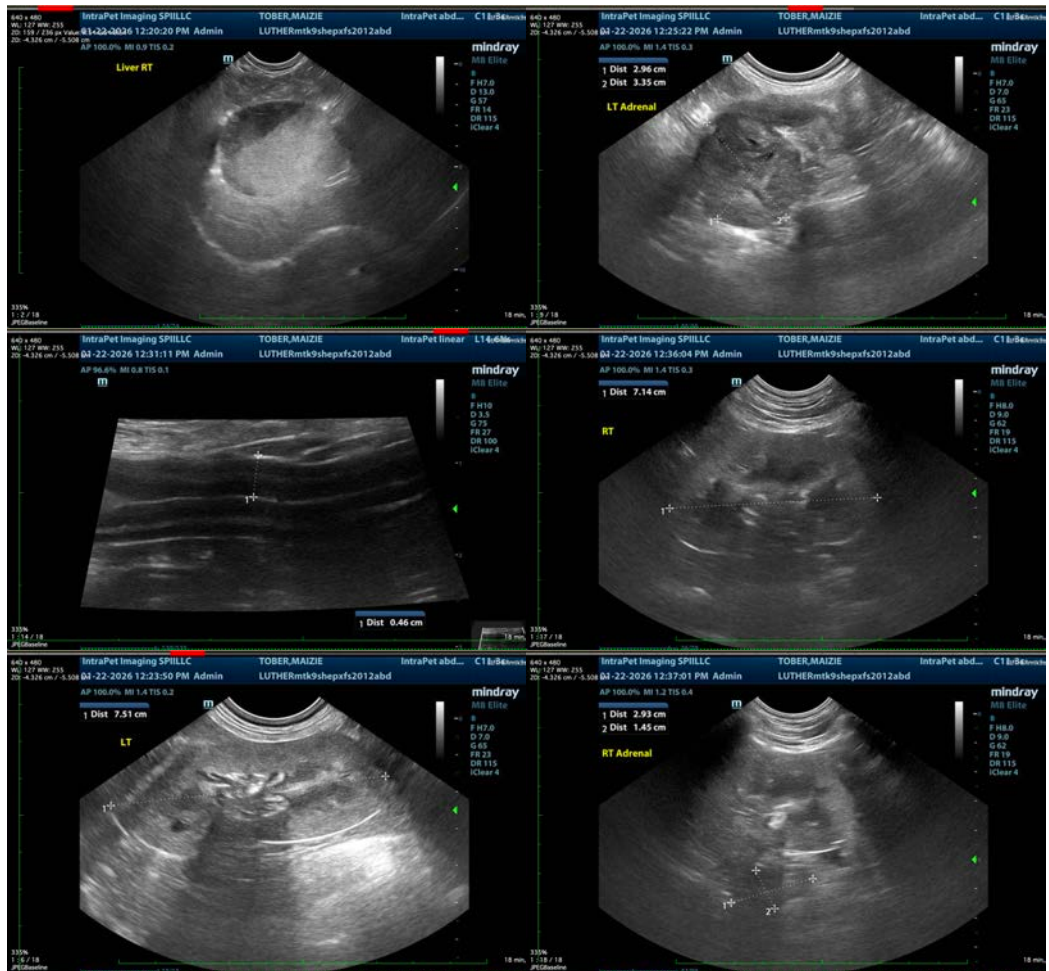
Three view thoracic radiographs are recommended for further assessment of cardio-pulmonary status as well as to further evaluate for any evidence of metastatic disease, if not recently evaluated.

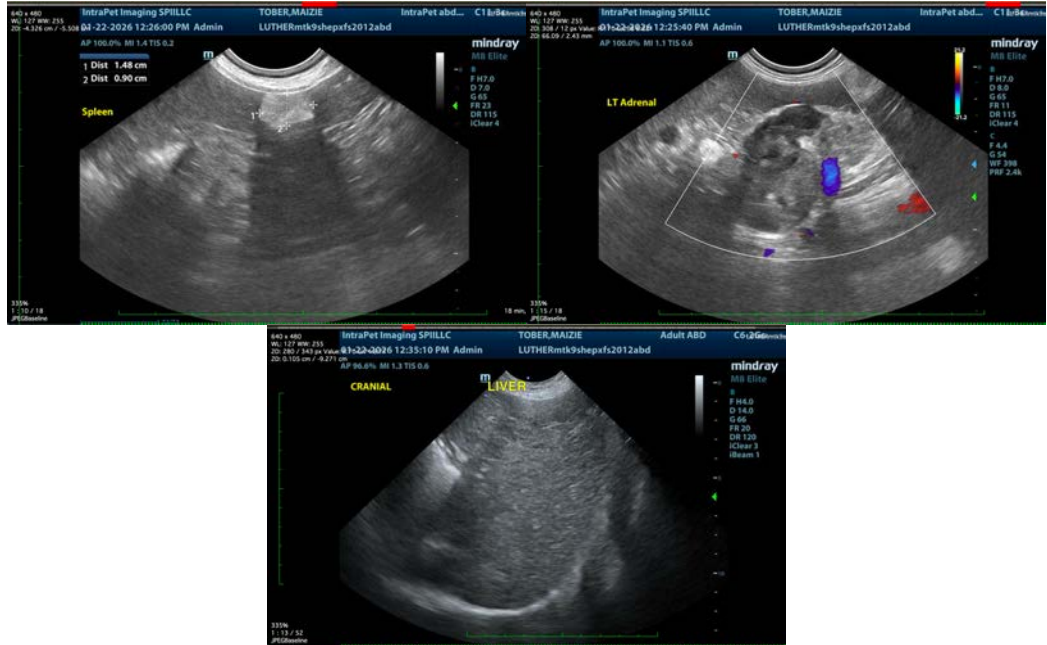
A blood pressure is recommended if not recently evaluated.

Hormone testing such as a low-dose Dexamethasone suppression test could be considered.

Ultimately, however, as a left adrenalectomy is likely recommended, an abdominal contrast CT scan could be considered for further staging, assessment of subtle (not visibly present here) vascular invasion, etc.

In the meantime, supportive/symptomatic medical management of clinical signs is recommended, including a probiotic (such as visbiome or proviable), empirical deworming with a 5-day course of Panacur and, if tolerated, a transition in diet, based on trial-and-error response, beginning possibly with a gastrointestinal biome diet vs a hydrolyzed protein diet vs other. Some patients respond to one brand/version of a hydrolyzed protein diet better than another brand, so several brand attempts may be required.





The information and recommendations provided are based on the images presented by the referring veterinarian/sonographer. No evaluation can be communicated regarding pathology that was not visible in the image/video clips provided.

Thank you for this referral. If the clinical or image interpretation does not parallel your findings or if I can be of any further assistance please contact me.

Beth Johnson, DVM, DACVIM
info@sonopath.com